

A bronchoscopic brush biopsy study of large airway mucosal pathology in smokers with chronic bronchitis and in healthy nonsmokers

G.C. Riise*, S. Larsson*, B.A. Andersson**

A bronchoscopic brush biopsy study of large airway mucosal pathology in smokers with chronic bronchitis and in healthy nonsmokers. G.C. Riise, S. Larsson, B.A. Andersson.
ABSTRACT: We investigated the use of bronchial brush biopsies of the bronchial epithelium as a diagnostic tool in common airway diseases.

Flexible fiberoptic bronchoscopy was performed on 22 smokers with non-obstructive chronic bronchitis and on 14 healthy nonsmoking individuals. Ten of the smokers had recurrent infectious exacerbations. Cell samples were taken from carinal and subsegmental levels of the bronchial tree with a standard cytological brush, and a differential count was made of the different cell types.

Smokers with chronic bronchitis had significantly more goblet cells (mean 20.0, SD 8.6), and less ciliated epithelial cells (mean 74.1, SD 9.4), than the healthy nonsmokers (mean 9.2, SD 3.9 and mean 84.7, SD 6.6, respectively). No such changes were found between the chronic bronchitis groups with or without infectious exacerbations.

Thus, bronchial brush biopsies can be used as a complement to standard bronchial biopsies in the investigation of airway diseases other than pulmonary malignancies.

Eur Respir J, 1992, 5, 382-386.

Dept of *Pulmonary Medicine
Renström's Hospital and
**Clinical Immunology
University of Göteborg, Sweden.

Correspondence: G.C. Riise
Dept of Pulmonary Medicine
Renström's Hospital
P.O.B. 17301, S-402 64
Gothenburg, Sweden.

Keywords: Bronchoscopy
brush biopsy
chronic bronchitis
cytology.

Received: September 1991
Accepted after revision December 3 1991.

Bronchial cytological brush biopsy is a routine method used in diagnosing pulmonary malignancies [1, 2]. The method can also be used to obtain cells from the normal bronchial epithelium. The aim of this study was, firstly to evaluate whether bronchoscopic brush biopsies can be used in a standardized manner to investigate common airway diseases, and secondly to evaluate brush biopsies as an objective method for the diagnosis of chronic bronchitis based on morphological changes in the bronchial epithelium.

Chronic bronchitis primarily affects smokers and is characterized by daily coughing and expectoration during at least three consecutive months over a period of more than two years [3]. The diagnostic criterion of chronic bronchitis is based solely on the case history, and no clinically useful objective method to diagnose chronic bronchitis has been described. The morphological basis for the hypersecretion in chronic bronchitis has previously been studied in bronchial specimens from patients taken during surgery or in postmortem tissue. Bronchial epithelium from patients with chronic bronchitis has been shown to have an increased number of goblet cells in the major and smaller bronchi, as well as in the bronchioles [4]. The number of inflammatory cells found in the mucosa is increased [5, 6].

We therefore analysed the cytology of the respiratory epithelium in smokers with non-obstructive chronic bronchitis and in healthy nonsmoking individuals. A

comparison was also made between the cytological outcome in chronic bronchitis patients with and without infectious exacerbations. The material was obtained with bronchoscopic brush biopsies taken from the carinal and the subsegmental levels of the bronchial tree.

Materials and methods

Subjects

1. Fourteen healthy nonsmoking volunteers with normal spirometry and no history of pulmonary disease or signs of upper or lower respiratory disease during the past four weeks.
2. Twelve current smokers with productive daily cough for at least six consecutive months each year, during the last two years, and normal spirometry and no history of infectious exacerbations.
3. Ten current smokers with chronic bronchitis and two or more infectious exacerbations a year, during the past two years. Exacerbation was defined according to BOMAN *et al.* [7]. Mucopurulent sputum and increased cough were regarded as obligatory criteria for a diagnosis of exacerbation. At least one of the following symptoms should be present: general malaise, symptoms of common cold, fever $>38^{\circ}\text{C}$, dyspnoea, increased mucus production, increased sputum thickness,

erythrocyte sedimentation rate (ESR)-elevation or blood leucocytosis.

None of the healthy nonsmokers had any regular medication. Five out of 22 chronic bronchitis patients used acetylcysteine regularly, eight out of 22 used inhaled beta₂-stimulants sporadically, and two out of 22 used inhaled ipratropium bromide sporadically. None used theophylline preparations or steroids of any kind. The duration of the bronchitis symptoms varied greatly between the individuals: from 2.5–24 yrs with a mean of 8.3 yrs.

Criteria for exclusion were abnormal chest X-ray, abnormal spirometry (forced expiratory volume in one second (FEV₁) <80% predicted), patients with bronchial hypersecretion caused by factors other than cigarette smoking, patients with a history of asthma or age >70 yrs.

Lung function (FEV₁) was measured with a Bernstein spirometer or Vitalograph and was required to decide whether the patients were suitable for the study or not.

The study design was approved by the local Ethical Committee and the volunteers gave their consent after written and oral information.

Bronchoscopy

Premedication was given with haloperidol, 5 mg orally, followed by 0.5–1 ml morphine-scopolamine *i.m.* Five ml 1% tetracaine was nebulized with a pressurized nebuliser (Plug-in inhalator, Aiolos systems, Karlstad, Sweden) and inhaled in an upright position for local anaesthesia. All bronchoscopies were performed by two experienced bronchoscopists and with the patient in the supine position. A flexible fiberoptic bronchoscope (Olympus BF ITR/IT 10, Olympus, Japan) was used.

Collection of samples

Brush biopsies for cytological examination were taken during bronchoscopy using a standard metal cytology brush (Olympus BC 9C-26101). Three consecutive brushings, from an approximately 3–4 cm² intrabronchial area, were sampled from two levels of the bronchial tree: from the carina and from the subsegmental bronchial level in the right lower lobe.

Two separate brushes were used for the two levels. The samples were immediately suspended in buffered formaldehyde and the analyses were performed without the investigator knowing which patient group was being investigated.

Cytological analysis

The fixed cells were stained with a drop of Sedistain (Clay Adams, Becton Dickinson, Parsippany, NJ 07054, USA) and analysed using an interference contrast microscope (Optophot II, Nikon, Fuji Bldg, 2–3, Marunouchi 3-chome, Chiyoda-ku, Tokyo 100, Japan). The number of ciliated epithelial cells, goblet cells, squamous epithelial cells, polymorphonuclear granulocytes and mononuclear cells (including macrophages) was determined. A few percent of the cells were classified as "other cells" consisting mainly of basal cells. The frequency of the different cell types was expressed as the percentage of one hundred intact cells counted.

Statistics

The location and dispersion of the two cell types with normal distribution were estimated using the arithmetical mean and standard deviation. For the cell types without normal distribution the median values were given. For comparison of the cellular distribution between groups of subjects, the group means were compared using the Student's *t*-test for data with normal distribution, and the Mann-Whitney *U*-test for non-parametric data.

Results

The mean age and the mean maximum FEV₁ did not differ substantially between the healthy nonsmokers and the patients with chronic bronchitis without exacerbations. The patients with chronic bronchitis and exacerbations were slightly older and had a lower FEV₁ in percentage of the predicted values, but within the normal range. The smoking history of the two groups with chronic bronchitis was comparable (table 1).

Table 1. – Age, FEV₁ (% of predicted normal) and cigarette consumption (pack years) of healthy controls and patients with chronic bronchitis

	n	Age yrs Mean (range)	FEV ₁ Mean	sd	Pack- years
Healthy nonsmokers	14	46 (26–66)	101	4	0
Chronic bronchitis without exacerbations	12	49 (36–62)	96	6	35
Chronic bronchitis with exacerbations	10	55 (48–68)	87	9	36

FEV₁: forced expiratory volume in one second.

Table 2. - Cellular distribution of brush biopsies in percentage of 100 counted cells at the carina level and the subsegmental level in patients with chronic bronchitis (n=22) and healthy controls (n=14)

Cell type	Healthy nonsmokers					Chronic bronchitis				
	Carina Mean	SD	Subsegmental Mean	SD	p<	Carina Mean	SD	Subsegmental Mean	SD	p<
Ciliated cells	81.4	11.6	88.0	5.2	NS	73.1	14.3	74.7	9.2	NS
Goblet cells	9.4	4.7	9.0	5.0	NS	19.8	11.0	20.3	9.7	NS
Cell type	Median	(Range)	Median	(Range)	p<	Median	(Range)	Median	(Range)	p<
Squamous cells	0	(0-9)	0	(0-2)	NS	0	(0-5)	0	(0-10)	NS
PMN	0	(0-4)	0	(0-11)	NS	0	(0-3)	0	(0-3)	NS
Mo-Mac	0	(0-48)	0.5	(0-8)	NS	0	(0-63)	1.0	(0-24)	NS
Others	0	(0-5)	0	(0-9)	NS	0	(0-4)	0	(0-5)	NS

PMN: polymorphonuclear granulocytes; Mo-Mac: mononuclear cells-macrophages; Others: cells with other morphology of which the majority were basal cells; ns: not significant.

Table 3. - Cellular distribution of brush biopsies in percentage of 100 counted cells in patients with chronic bronchitis (n=22) and healthy controls (n=14)

Cell type	Chronic bronchitis		Healthy nonsmokers		p<
	Mean	SD	Mean	SD	
Ciliated cells	74.1	9.4	84.7	6.6	0.001
Goblet cells	20.0	8.6	9.2	3.9	0.0001
Cell type	Median	(Range)	Median	(Range)	p<
Squamous cells	0	(0-7.5)	0	(0-5.5)	NS
PMN	0	(0-1.5)	0	(0-5.5)	NS
Mo-Mac	0	(0-35)	0	(0-28)	NS
Others	0	(0-3)	0	(0-7)	NS

For each individual the mean values from the carinal and the subsegmental level were used. For abbreviations see legend to table 2.

Table 4. - Cellular distribution of brush biopsies in percentage of 100 counted cells from chronic bronchitis patients with (n=10) and without (n=12) infectious exacerbations

Cell type	With exacerbations		Without exacerbations		p<
	Mean	SD	Mean	SD	
Ciliated cells	73.5	12.0	75.1	7.8	NS
Goblet cells	17.1	8.3	22.2	8.9	NS
Cell type	Median	(Range)	Median	(Range)	p<
Squamous cells	0	(0-7.5)	0	(0-3)	NS
PMN	0.5	(0-1.5)	0	(0-0.5)	0.03
Mo-Mac	2.5	(0-35)	0	(0-7.5)	NS
Others	0	(0-2)	0	(0-3)	NS

For each individual the mean values from the carinal and the subsegmental level were used. For abbreviations see legend to table 2.

The mean number of ciliated epithelial cells, goblet cells, squamous cells, inflammatory cells and alveolar macrophages did not differ significantly between the carinal level and the subsegmental level for any cell type (table 2). As no differences between the two levels were found, means for cell counts from the

two levels were used for comparison between the groups.

A significantly larger number of goblet cells was noted in patients with chronic bronchitis than in healthy controls ($p=0.0001$; 99.9% confidence interval: 14.1-25.9% and 5.9-11.8%, respectively), (table 3). A

significantly smaller number of columnar epithelial cells was found in the patients with chronic bronchitis ($p < 0.001$). The ratio of goblet cells to ciliated epithelial cells was about 1:9 in healthy nonsmoking controls and about 1:3.5 in patients with chronic bronchitis. The numbers of squamous epithelial cells, polymorphonuclear granulocytes and mononuclear cells were small, they were unevenly distributed and did not differ significantly between the study groups (tables 3 and 4).

The cellular distribution in brush biopsies from patients with chronic bronchitis with and without infectious exacerbations did not differ significantly for any of the cell types with one exception: the percentage of polymorphonuclear cells was significantly higher in the chronic bronchitis group with recurrent infectious exacerbations ($p < 0.03$ with Mann-Whitney U-test) (table 4).

The cell frequency in brush biopsies from different bronchial levels in the healthy nonsmoking group was taken as the reference value for normality by adding two SDs to the mean of the goblet cells. Thirteen out of 22 smokers with chronic bronchitis had goblet cell percentages above this cut-off level. The sensitivity of the method in differentiating bronchitics from controls was approximately 60% (fig. 1). Similar values were noted for ciliated epithelial cells.

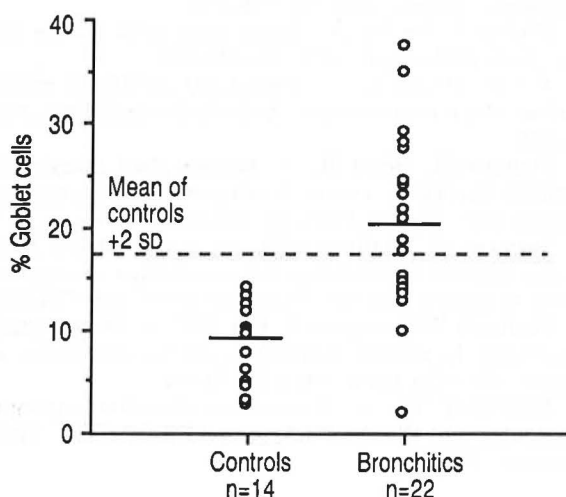


Fig. 1. — Individual numbers of goblet cells in percentage of 100 counted cells in controls and bronchitics. For each individual the mean value from the carina and the subsegmental levels is given. Dashed line indicates the mean +2SD for the goblet cell percentages in controls. Thirteen out of 22 patients with chronic bronchitis fall outside this range. A short horizontal line in each group indicates the mean number of goblet cells.

Discussion

Quantitative studies of the cell population in normal nonsmoking human bronchial epithelium are scarce. SÖDERBERG *et al.* [8] recently reported a ratio of goblet cells to ciliated epithelial cells of approximately 1:10 in healthy nonsmokers based on bronchial biopsies. In previous studies on healthy people a ratio of 1:5 from

the trachea [9] and 1:3 from the bronchi has been reported [10], but the authors commented that the large number of goblet cells in their reports was probably due to inclusion of specimens from heavy smokers. The results of the present study show a ratio close to 1:9 in healthy nonsmokers, which is similar to the results of SÖDERBERG *et al.* [8].

Previous morphological studies in patients with chronic bronchitis have largely been based on postmortem or postoperative material. Patients with chronic bronchitis have been shown to have increased numbers of goblet cells both in the central [6, 11–14], and in the peripheral bronchi [5, 15–18]. Increased mucosal inflammation has also been found. The submucosal mucous glands seem to be hypertrophic in chronic bronchitis and their production of mucus is increased [12, 13, 19]. In two biopsy studies on the human trachea and bronchi, the authors found that the mean goblet cell density was positively correlated to the tobacco consumption in smokers, and that smokers with chronic bronchitis had the highest values [20, 21]. Our results from both healthy nonsmokers and patients with chronic bronchitis are, thus, in line with previous reports, indicating that brush biopsies gives meaningful results and can be used for diagnostic purposes. The use of bronchial brush biopsies for diagnostic purposes in pulmonary diseases, other than malignancies, has not previously been described.

Attempts have been made to validate the diagnosis of chronic bronchitis from histopathological changes [5, 12, 19, 22–24]. The methods used in these studies are, however, dependent on postoperative or postmortem material. Their clinical use in diagnosing chronic bronchitis is therefore limited.

Histological sections of bronchial biopsies have also been studied to investigate the cell population of the bronchial epithelium, both in healthy subjects and in patients with chronic bronchitis, but the size, condition and degree of representation of the biopsies varied greatly and the method proved hard to standardize [9, 13, 18]. In the study of SÖDERBERG *et al.* [8] for example, 40% of the biopsies had to be discarded [25]. In the present study, the problem of uneven, clusterwise goblet cell distribution in the bronchial tree [12, 16, 17, 20] is overcome by brushing a relatively large bronchial area and making a differential cell count of the brush biopsy outcome.

To study the usefulness of our findings for diagnostic purposes we constructed a normal interval based on the goblet cell percentage in the healthy nonsmoking group. To define the upper limit, two standard deviations were added to the mean. Thirteen out of 22 of the bronchitic patients fell outside this value, having a higher percentage of goblet cells in their bronchial biopsies. This implies that the method has a sensitivity of 60% in differentiating smokers with chronic bronchitis from healthy nonsmokers.

In conclusion, bronchial brush biopsies can be used to study airway mucosal pathology clinically. In being representative for a large bronchial area they could be

used as a complement to the standard bronchial forceps biopsy.

A finding of more than 17% goblet cells in the bronchial brush biopsy from a smoker with hypersecretion strongly suggests chronic bronchitis. The usefulness of this method in differentiating between chronic bronchitis and other pulmonary diseases with bronchial hypersecretion, especially asthma, needs to be further evaluated.

In accordance with our reported findings above, we are now preparing a larger study involving asthmatics and comparing the bronchial brush biopsy technique to standard bronchial biopsies.

Acknowledgements: The authors would like to thank the following organizations for their support of this study: The Swedish Heart and Lung Foundation, the Swedish Society for Medicine and the Swedish Tobacco Company.

References

1. Fulkersson WJ. - Current concepts. Fiberoptic bronchoscopy. *N Engl J Med*, 1984; 311: 511-514.
2. Carr DT, Cortese DA. - The value of cytologic examination in the management of lung cancer. *Curr Probl Cancer*, 1980; 5: 20-34.
3. Council MR. - Definition and classification of chronic bronchitis for clinical and epidemiological purposes. *Lancet*, 1965; 1: 775-781.
4. Breeze RG, Wheeldon EB. - The cells of the pulmonary airways. *Am Rev Respir Dis*, 1977; 116: 705-768.
5. Mullen BJ, Wright JL, Wiggs BR, Pare PD, Hogg JC. - Reassessment of inflammation of airways in chronic bronchitis. *Br Med J*, 1985; 291: 1235-1239.
6. Mullen BJ, Wright JL, Wiggs BR, Pare PD, Hogg JC. - Structure of central airways in current smokers and ex-smokers with and without mucus hypersecretion: relationship to lung function. *Thorax*, 1987; 42: 843-848.
7. Boman G, Bäcker U, Larsson S, Melander B, Wåhlander L. - Oral acetylcysteine reduces exacerbation rate in chronic bronchitis: report of a trial organized by the Swedish Society for Pulmonary Diseases. *Eur J Respir Dis*, 1983; 64: 405-415.
8. Söderberg M, Hellström S, Sandström T, Lundgren R, Bergh A. - Structural characterization of bronchial biopsies from healthy volunteers: a light and electron microscopical study. *Eur Respir J*, 1990; 3: 261-266.
9. Rhodin JAG. - Ultrastructure and function of the human tracheal mucosa. *Am Rev Respir Dis*, 1966; 93(3): 1-15.
10. McDowell E, Barrett L, Glavin F, Harris C, Trump B. - The respiratory epithelium. 1. Human bronchus. *J Natl Cancer Inst*, 1978; 61: 539-545.
11. Reid L, Melb MB. - Pathology of chronic bronchitis. *Lancet*, 1954; 1 (Feb 6): 275-278.
12. Reid L. - Measurement of the bronchial gland layer: a diagnostic yardstick in chronic bronchitis. *Thorax*, 1960; 15: 132-141.
13. Salvato G. - Some histological changes in chronic bronchitis and asthma. *Thorax*, 1968; 23: 168-172.
14. Watson JHL, Brinkman GL. - Electron microscopy of the epithelial cells of normal and bronchitic human bronchus. *Am Rev Respir Dis*, 1964; 90(6): 851-855.
15. Wright JL, Lawson LM, Pare PD, Wiggs BJ, Kennedy S, Hogg JC. - Morphology of peripheral airways in current smokers and ex-smokers. *Am Rev Respir Dis*, 1983; 127: 474-477.
16. Lumsden AB, McLean A, Lamb D. - Goblet and Clara cells of human distal airways: evidence for smoking induced changes in their number. *Thorax*, 1984; 39: 844-849.
17. Ebert RV, Terracio MJ. - The bronchiolar epithelium in cigarette smokers. *Am Rev Respir Dis*, 1975; 111: 4-11.
18. Brinkman G, Watson JHL. - Electron microscopy of human bronchial mucosa. *J Am Med Assoc*, 1965; 192(9): 90-93.
19. Dunnill MS, Massarella GR, Anderson JA. - A comparison of the quantitative anatomy of the bronchi in normal subjects, in status asthmaticus, in chronic bronchitis, and in emphysema. *Thorax*, 1969; 24: 176-179.
20. Ellefsen P, Tos M. - Goblet cells in the human trachea. *Arch Otolaryngol*, 1972; 95: 547-555.
21. Tos M, Möller K. - Goblet-cell density in human bronchus in chronic bronchitis. *Arch Otolaryngol*, 1983; 109: 673-676.
22. Restrepo GL, Heard BE. - Mucous gland enlargement in chronic bronchitis: extent of enlargement in the tracheo-bronchial tree. *Thorax*, 1963; 18: 334-339.
23. Takizawa T, Thurlbeck WM. - A comparative study of four methods of assessing the morphologic changes in chronic bronchitis. *Am Rev Respir Dis*, 1971; 103: 774-783.
24. Thurlbeck WM, Angus GE, Pare JAP. - Mucous gland hypertrophy in chronic bronchitis, and its occurrence in smokers. *Br J Dis Chest*, 1963; 57: 73-78.
25. Söderberg M. - Studies on bronchial mucosal morphology and bronchial responsiveness in man. Umeå University, 1990.