

## Atypical ossification in bronchial carcinoid

L. Vanmaele\*, M. Noppen\*, N. Frecourt\*\*,  
N. Impens\*, B. Welch\*\*\*, W. Schandevijl\*

*Atypical ossification in bronchial carcinoid. L. Vanmaele, M. Noppen, N. Frecourt, N. Impens, B. Welch, W. Schandevijl.*

**ABSTRACT:** A patient is described with bronchial carcinoid and ossification in the surrounding bronchial wall. The osseous metaplasia was the only histologic abnormality discovered in bronchial biopsy specimens taken pre-operatively. We propose that underlying bronchial carcinoid tumour should be considered in isolated bronchial or bronchopulmonary ossification.

*Eur Respir J.*, 1990, 3, 927-929.

Departments of Pulmonology\*, Pathology\*\*, and Thoracic Surgery\*\*\*, Academic Hospital, Free University Brussels, Belgium.

Correspondence: L. Vanmaele, Department of Pulmonology, AZ-VUB, Laarbeeklaan 101, 1090 Brussels, Belgium.

Keywords: Bronchial carcinoid; broncho-pulmonary ossification.

Received: May 1989, accepted August 9, 1989.

The bronchial carcinoid is a relatively low-grade malignant neoplasm and arises from the neuroendocrine argentaffin cells of the bronchial mucosa (Kulchitsky's cells). Its incidence is estimated to be less than one per 100,000 inhabitants per year [1]. The light microscopic histology, the electron microscopic demonstration of neurosecretory granules and the histochemical characteristics usually permit distinction from other bronchopulmonary malignancies. The clinical evolution is usually benign, but metastases in regional lymph nodes, liver, bone and adrenals can occur, and therefore surgical excision is the treatment of choice when possible. The ten year survival post surgery is excellent (up to 90%) [1].

A subgroup of atypical carcinoids represent a distinct clinicopathologic entity and implicates a less favourable prognosis [2].

Pulmonary ossification or osseous metaplasia is a non-specific finding and known to occur in a variety of pulmonary disorders. One of them is the bronchial carcinoid, and up to 10% of cases show some amount of bone tissue but almost always within the tumoral stroma [3].

We here report the case of a patient with postoperatively diagnosed carcinoid tumour of the lung with atypical osseous metaplasia of the surrounding bronchial wall.

### Case report

A 49 year old caucasian woman present with a 6 month history of non-productive cough and intermittent fever up to 38°C during the last month prior to admission. She experienced mild fatigue and a 2 kg weight loss. Her previous medical history was unremarkable except for maxillary sinusitis 1 year earlier. She was a house wife and denied alcohol and tobacco use. A

treatment of doxycycline 2 weeks before entry was unsuccessful.

On examination the patient appeared to be well. Her temperature was 37.4°C. No lymphadenopathies were found. The lungs, heart, breast, abdomen and extremities were normal. Laboratory findings included a sedimentation rate of 64 mm per hour and a fibrinogen concentration of 492 mg·100 ml<sup>-1</sup>. All other routine laboratory results were within normal limits.

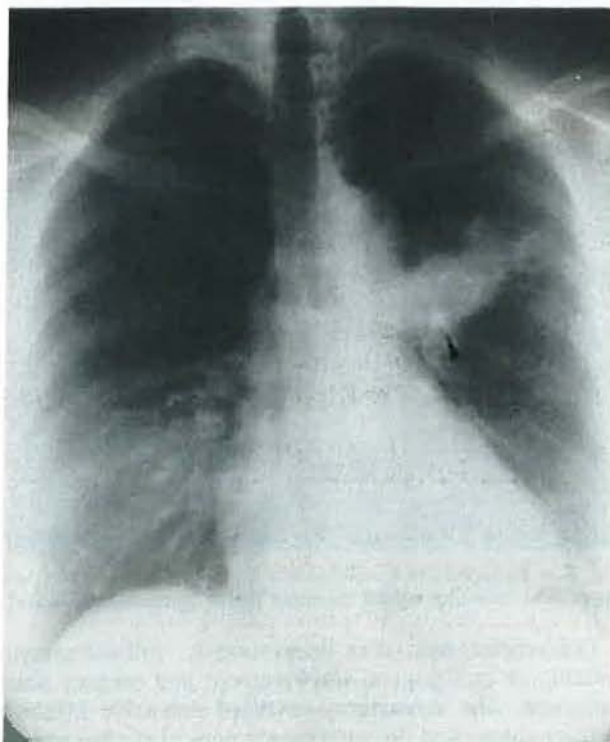


Fig. 1. - Chest X-ray shows an infiltrate in the anterior segment of the left upper lobe with possible calcification (arrow) at its origin.



The chest X-ray (fig. 1) disclosed a consolidation with partial atelectasis of the anterior segment of the left upper lobe with a small area of calcification at its origin. A CT scan of the thorax confirmed this, but failed to show an evident cause for obstruction. At bronchoscopy the anterior segment of the left upper lobe showed a concentric narrowing leading to complete obstruction. No evident tumour was discovered but the mucosa had an irregular appearance. The only abnormality observed in multiple bronchial biopsy specimens taken in the obstructed segmental bronchus on two occasions was osseous metaplasia (fig. 2). A percutaneous fine needle aspiration under CT guidance yielded a positive culture for *Haemophilus influenzae* but cytologic examination of it as well as of the bronchial aspirate showed no malignant cells.

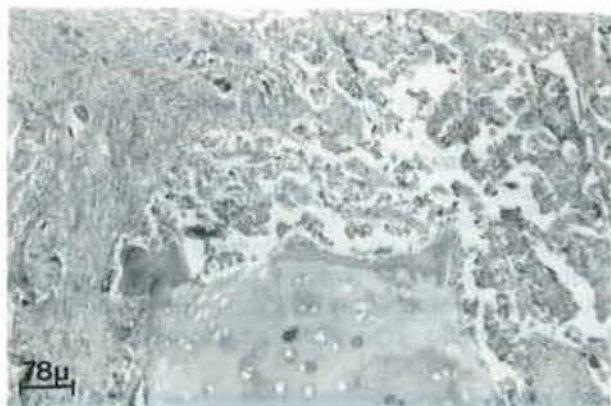


Fig. 2. — Bronchial biopsy showing bone tissue (arrow).

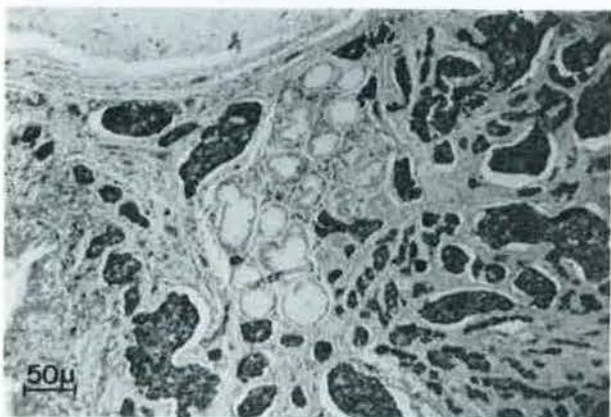


Fig. 3. — Postoperative histologic examination of the resected left upper lobe revealing typical carcinoid tumor (chromogranin stain).

Cefuroxime was given intravenously, without symptomatic or radiological improvement and surgery was proposed. The thoractomy revealed extensive inflammatory changes in the anterior segment of the left upper lobe with a narrow stenosis at the origin caused by a small (1 cm) submucosal tumour. Because of multiple

adhesions to the other segments a left upper lobectomy was performed. No lymphadenopathies were present. The post-operative course was uneventful except for one episode of bronchopneumonic infection 1 month later related to attraction and knotting of the left main and lower lobe bronchus, a known complication following upper lobectomy.

Histologic examination showed nests of clear relatively monomorphous cells with uniformly positive immunohistochemical staining for chromogranin, typical bronchial carcinoid tumour (fig. 3). Osseous metaplasia of the bronchial wall in the vicinity of the tumour and to a lesser amount in the tumour itself was demonstrated.

## Discussion

The clinical presentation of our patient is typical for bronchial carcinoid. Since 80% of these tumours are located in the central bronchi and project into the airway lumen [4] they can indeed cause lobar or segmental atelectasis and/or infection. Usually the tumor can then be visualised directly at bronchoscopy and has a greyish-white or "cherry-red" appearance, due to its vascularity. Bronchial obstruction by extrinsic compression without visible tumour as in our patient is less common. The most unusual feature of this case report, however, is the localisation of and confusion caused by the heterotopic osseous tissue in the bronchial wall adjacent to the tumour.

Osseous tissue is often found in the lung and can be associated with numerous conditions [5]. Areas of dystrophic calcification where deposits of calcium salts are formed in damaged or necrotic lung tissue (post-chemo- or radiotherapy, post-infectious etc.) can be accompanied by osseous metaplasia. Bone tissue can also be found in normal or neoplastic cartilage tissue (chondroma), especially in the elderly where ossification of bronchial cartilage rings is common. *Bronchopathia osteoplastica* is a rare disorder characterised by ossification of the cartilaginous rings of the trachea and the large bronchi. Nodular heterotopic ossification may occur in long-standing mitral stenosis, in organised inflammatory tissue, in idiopathic interstitial lung fibrosis, occasionally in the walls of a chronic cavity and very rarely by a process of the metaplasia within normal lung (diffuse parenchymal ossification). Bone formation also can be found within parenchymal amyloid deposits in nodular pulmonary amyloidosis, around the calcospherites in alveolar microlithiasis and in the centres of chondromatous hamartomas and in sclerosing angiomas. Lung metastases from osteogenic sarcoma can contain osseous tissue. Finally, in 10% of bronchial carcinoid tumors particularly in those of long duration, ossification has been found in the vascular stroma and intersecting fibrous strands. An osteoblastic reaction to the tumour cells is also found in metastatic deposits of carcinoids especially in bone. This is a strong argument that ossification is caused by influence of enzymes secreted by the carcinoid cells of the surrounds stroma [6]. In this regard it is interesting to observe that



sometimes tumour cells are rich in acid phosphatase and 5-nucleotidase (both negative in our case).

The finding of isolated osseous tissue in a bronchial biopsy specimen can be explained by the size limitation of the bronchial biopsies. The bone fragment could have been surrounded by tumoral cells that were missed in small bronchial specimens. It is, however, very unusual to see bone as the only abnormality in severe bronchial biopsies taken at two occasions. This heterotopic bone tissue could account for the calcification found on the radiographic studies.

We conclude that underlying bronchial carcinoid should be considered when bronchial biopsy specimens only show ossification in the absence of other associated lung disorders.

#### References

1. Blondal T, Grimelius L, Nou E, Wilander E, Aberg T. – Argrophil carcinoid tumors of the lung. Incidence, clinical study and follow-up of 46 patients. *Chest*, 1980, 78, 840–844.
2. Grote TH, Macon WR, Davies B, Greco FA, Johnson DH. – Atypical carcinoid of the lung - A distinct clinico-pathological entity. *Chest*, 1988, 93, 370–375.
3. Thomas CP, Morgan AD. – Ossifying bronchial adenoma. *Thorax*, 1958, 13, 286–293.
4. Rozenman J, Pausner R, Lieberman Y, Gamsu G. – Bronchial adenoma. *Chest*, 1987, 92, 145–147.
5. Spencer H. – Degenerative and metabolic disorders of the lung. In: Spencer H, ed. *Pathology of the lung*, 3rd ed. Pergamon Press 1977.
6. Toomey F, Felson B. – Osteoblastic bone metastasis in gastrointestinal and bronchial carcinoids. *Amer J Roentgenol*, 1960, 83, 709–715.

*Ossification atypique dans un carcinoïde bronchique. L. Vanmaele, M. Noppen, N. Freccourt, N. Impens, B. Welch, W. Schandevijl.*

RÉSUMÉ: Nous décrivons une patiente présentant une tumeur carcinoïde bronchique avec une ossification dans la paroi bronchique adjacente. Cette métaplasie osseuse était la seule anomalie histologique retrouvée dans les prélèvements bronchiques pré-opératoires. La présence d'une tumeur carcinoïde bronchique doit être considérée dans les cas d'ossification bronchique ou broncho-pulmonaire isolée. *Eur Respir J.*, 1990, 3, 927–929.