

Peripheral lung mass

M. Mamay*, A. Michils*, P. De Vuyst*, P.A. Gevenois**, J.C. Yernault*

A 76 yr old man was evaluated in February 1989 for a one year long standing pain in the right hypochondrium. In September 1980, he had been admitted to another hospital with multiple right rib fractures and haemothorax after a chest trauma. A routine chest X-ray in 1982 showed sequelae of the trauma and a free right costo-diaphragmatic angle (fig. 1).

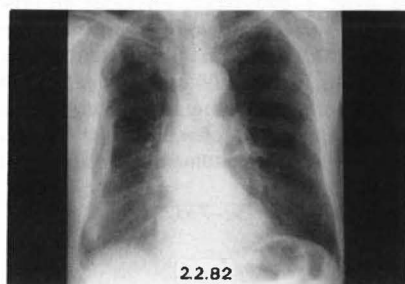


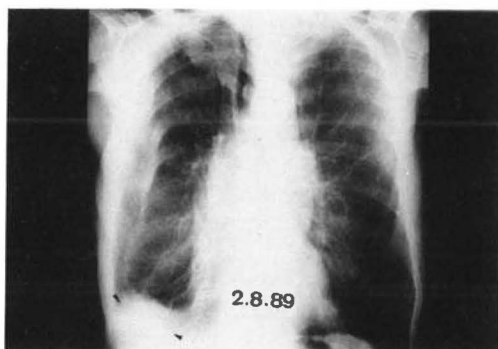
Fig. 1. - Chest X-ray taken in 1982.

He had smoked 30 pack-years and had been submitted to indirect asbestos exposure as an architect during building works.

Physical examination was unremarkable, except for painful palpation of right hypochondrium. His chest X-ray (fig. 2a) was characterized by consolidated rib fractures, a thickening of the right basal pleura, and a postero-basal rounded opacity appearing to have a pleural contact. Lateral and oblique views confirmed a solid mass of 6 cm diameter in the right lower lung field, taking contrast at computed tomography (CT) scan (fig. 3).

The possible diagnoses evoked at that moment were primary (long standing smoking history) or secondary malignant lesion, on round atelectasis (post-traumatic pleural thickening; asbestos exposure).

a



b

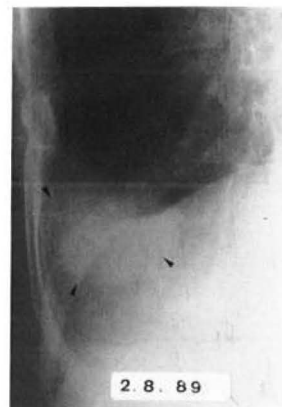

Fig. 2a. - a: Chest X-ray taken in 1989; b: oblique view (1989).

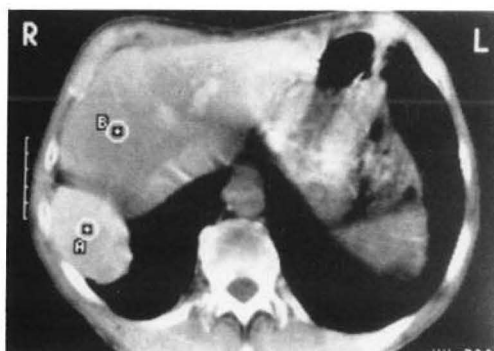


Fig. 3. - Thoraco abdominal computed tomography (CT) scan (1989).

TURN PAGE FOR DIAGNOSIS

Diagnosis

A transthoracic needle aspiration yielded hepatocytes, suggesting a diagnosis of post-traumatic hepatic hernia. This diagnosis was confirmed by an isotopic liver tomogram, yet was not apparent on the classical views (fig. 4a and 4b).

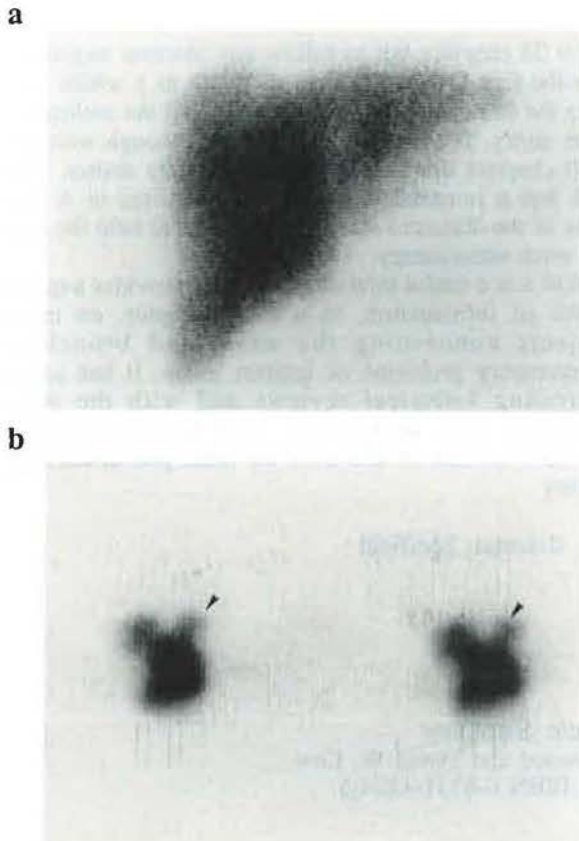


Fig. 4. — a: isotopic liver scan. b: isotopic liver tomogram (transverse view).

Discussion

Blunt or nonpenetrating abdominal traumas account for the vast majority of chronic diaphragmatic hernias [1, 2]. With penetrating traumas, this lesion is recognized earlier during surgical exploration [3]. Left diaphragmatic herniations are more frequent (90% of all diaphragmatic ruptures) because of protection offered by the liver mass on the right side [2, 4].

Chest X-ray is frequently abnormal in case of diaphragmatic herniation at the time of trauma. X-ray findings include diaphragmatic elevation, pleural effusion and air filled or solid viscerae above the diaphragm [1, 2, 5]. However, up to half of all diaphragmatic injuries may be missed during the initial evaluation [6].

In our case, because of associated right haemothorax, the diaphragmatic herniation could not have been visualized by chest X-ray; moreover the X-ray taken two years after the trauma was still unremarkable.

This case report shows that hepatic hernias should be included in the differential diagnoses of right basal masses, when there is a history of thoraco-abdominal trauma, even years later. However, the course of traumatic diaphragmatic hernias usually follows three separated phases [4, 7]: the acute injury, the interval phase which can last up to 45 yrs (eight years in this case) and the late phase related to the complication of herniated incarcerated viscera, which can constitute a surgical emergency in case of strangulation of the small bowel included in the hernia or, as in our case, be the cause of nonspecific pain.

Once the diagnosis of hepatic hernia is suspected, isotopic liver tomogram appears to be a much less invasive procedure than transthoracic needle aspiration [3].

References

1. Hood M. — Traumatic diaphragmatic hernia. *Ann Thorac Surg*, 1971, 12, 311-316.
2. Broum GL, Richardson JD. — Traumatic diaphragmatic hernia: a continuing challenge. *Ann Thorac Surg*, 1985, 39, 170-173.
3. Hix W, Aaron B. — In: *Residua of thoracic trauma*. Futura publishing CO, Mount Kisco, New York 10549, 1987, 9, 221-234.
4. Trinhile JK, Harman PK, Grower FL. — Chest Trauma. In: *Pulmonary diseases and disorders*, 2nd edition. A.P. Fishman ed., New York MacGraw Hill, 1988, pp. 2443-2458.
5. Aronhiek J, Epstein D, Geffer W, Miller W. — Chronic traumatic diaphragmatic hernia, the significance of pleural effusion. *Radiology*, 1988, 168, 675-678.
6. Arendrup MC, Jensen BS. — Traumatic rupture of the diaphragm. *Surg Gynecol Obstet*, 1982, 154, 526-530.
7. Carter BN, Giuseffi I, Felson B. — Traumatic diaphragmatic hernia. *AJR*, 1951, 65, 56-72.

Masse pulmonaire périphérique. Un cas à diagnostiquer. M. Mamay, A. Milchils, P. De Vuyst, P. Gevenois, J.C. Yernault.

RÉSUMÉ: Un homme de 76 ans est en observation pour une douleur remontant à un an. Huit ans plus tôt, il avait subi un traumatisme thoracique à droite, accompagné de fractures costales et d'hémothorax. Le cliché thoracique montre une opacité arrondie du champ pulmonaire inférieur droit. La ponction transthoracique à l'aiguille ramène des hépatocytes. Le diagnostic de hernie hépatique post-traumatique est confirmé par une tomographie isotopique du foie. *Eur Respir J.*, 1990, 3, 734-735.