

***Pneumocystis carinii* pneumonia and acquired immunodeficiency syndrome: an atypical presentation with lung cavitations**

J-O. Praz*, P. Lorenzi**, J.C. Chevrolet**

Pneumocystis carinii pneumonia and acquired immunodeficiency syndrome: an atypical presentation with lung cavitations J-O. Praz, P. Lorenzi, J.C. Chevrolet

ABSTRACT: The differential diagnosis of lung cavitations is very broad. We report a case of *Pneumocystis carinii* pneumonia (PCP) with lung cavitations on the chest X-ray in a patient with the acquired immunodeficiency syndrome (AIDS). We discuss the differential diagnosis of such an X-ray pattern and emphasize that multiple cavitations can be a roentgenographic presentation of PCP.

Eur Respir J., 1990, 3, 1221-1223.

* Clinique Médicale Thérapeutique, ** Division de Pneumologie, and Soins Intensifs Médicaux, Geneva University Hospital, Switzerland.

Correspondence: J.C. Chevrolet, Division de Pneumologie, Geneva University Hospital, Switzerland.

Keywords: AIDS; lung cavitations; *Pneumocystis carinii* pneumonia.

Received: December 22, 1989; accepted after revision April 25, 1990.

The roentgenographic pattern of *Pneumocystis carinii* pneumonia (PCP) is a diffuse pulmonary infiltration. This presentation has been described in approximately 80% of patients with the acquired immunodeficiency syndrome (AIDS) [1]. Unusual radiologic manifestations of PCP have been reported in up to 20% of cases, as lobar distribution, pleural effusion, atelectatic changes, hilar lymphadenopathy, pneumothorax, honeycomb appearance, and cavitations.

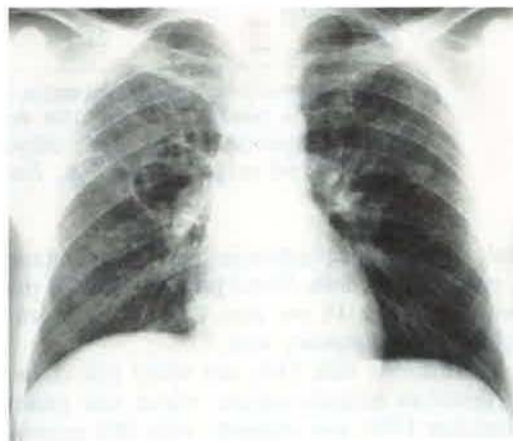
Although lung cavitations were not initially considered to occur in patients with AIDS and PCP [2], they represent a rare roentgenographic manifestation of PCP [3]. We report a case of multiple lung cavitations, which suggests that lung tissue destruction may occur during PCP [4].

Case report

A 30 yr old male intravenous drug addict, HIV positive for 2 yrs, was admitted to our hospital in 1989 for multiple lung cavitations. There was a past history of B-hepatitis in 1982, two episodes of bronchopneumonia in 1988, and a 12 kg body weight loss during the previous 5 mths. Two weeks before hospitalization, the patient presented with a productive cough, fever and nocturnal sweating. He progressively experienced dyspnoea and chest pain when coughing. The chest X-ray showed multiple thin-walled cavitations (fig. 1): a diagnosis of "multiple lung abscesses" was proposed, and the patient was treated with oral cotrimoxazole. This treatment was quite erratic due to poor compliance, and the patient was hospitalized because of worsening symptoms.

On examination the patient appeared thin. He had oral and genital candidosis, as well as right mandibular and

A



B

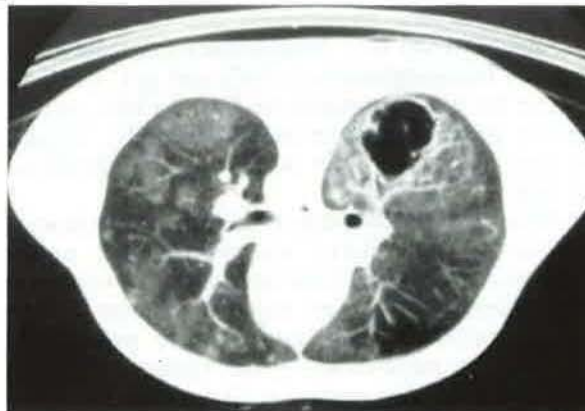


Fig. 1. - A: Chest radiograph showing thin-walled cavitations on the right middle and left upper pulmonary areas; B: computed tomography scan showing thin-walled cavitations with alveolar and interstitial infiltration.

Table 1. - PCP with lung cavitation: literature review of clinical and other aspects

Reference case number	4 (2)	4 (5)	6 (2)	7	10	11	our case
Age yrs	30	40	56	45	32	39	30
Sex	M	M	M	M	M	M	M
HIV+ mths	?	?	?	?	15	?	24
Risk factor	DA	DA	H	B	H	DA	DA
Leucocytes 10⁹.l⁻¹							
total	?	?	24.6	3700	1000*	1700	1800*
lymphocytes	?	?	1230	999	280	221	792
CD4/CD8 ratio	?	?	?	0.8	?	?	0.15
LDH U.l ⁻¹	?	?	?	?	225	?	663
X-ray picture							
1 cavity	0	0	+	0	0	+	0
>1 cavity	+	+	0	+	+	0	+
interstitial pattern	+	+	0	+	0	0	+
response to therapy	+	0	0	+	?	+	+
	C+P	C	C	C	?	C	C+P
Clinical aspects							
body weight loss	+	+	?	+	?	+	+
temperature °C	39	38	37	38	38	39	38
cough	?	?	+	+	+	+	+
dyspnoea	?	?	+	+	+	+	+
Pao ₂ mmHg	56	?	60	?	?	110	82
Fio ₂ %	21	?	21	?	?	21	21

PCP: *Pneumocystis carinii* pneumonia; HIV: human immunodeficiency virus; M: male; ?: data not available; +: present; 0: absent; DA: drug addict; H: homosexual; B: bisexual; *: patients treated by azidothymidine; LDH: lactic dehydrogenase in plasma; C: cotrimoxazole; P: pentamidine; Pao₂: arterial oxygen tension; Fio₂: fraction of inspired oxygen.

bilateral inguinal lymphadenopathies. Temperature was 38°C, pulse 96 per min, blood pressure 130/70 mmHg, and respiratory rate 16 per min. Rales were heard over the right upper pulmonary area.

The haematocrit was 33%; the white cell count was 1,800 (therefore azidothymidine, which was prescribed since October 1988, was stopped), with 28% neutrophils, 14% band form, 14% monocytes, and 40% lymphocytes. The platelet count was 140,000·mm⁻³. Gamma-GT was 236 U.l⁻¹, alkaline phosphatase 242 U.l⁻¹, ASAT 84 U.l⁻¹, and LDH 663 U.l⁻¹. Immunoelectrophoresis showed increased immunoglobulin G (IgG) and IgA. CMV was negative for IgM but positive for IgG, the HIV₁ serology showed positive anti-envelope antibody, negative anti-core, and positive p24 antigen; the CD4/CD8 ratio was 0.15 (n=1-2).

A fiberoptic bronchoscopic examination with broncho-alveolar lavage (BAL) was performed: neither *Pneumocystis carinii* (PC) nor fungi or mycobacteria were found. Blood cultures were negative. Echocardiography was unremarkable. Because of the presence of *Streptococcus pneumoniae* in the sputum, the patient received amoxicillin orally for 10 days.

Three weeks later, a second bronchoscopic examination with BAL was performed, as the chest roentgenogram showed a progression of the pulmonary lesions (appearance of new thin-walled cavitations, size

increase of pre-existent cavitations and an impressive progression of the alveolar and interstitial patterns). PC was identified in the bronchial lavage fluid, and cytological and bacteriological examinations, including mycobacterial cultures up to 8 wks, failed to reveal the presence of any other pathogen. The patient was therefore treated with intravenous cotrimoxazole. After a 10-day treatment, gastrointestinal side-effects appeared: cotrimoxazole was replaced by intravenous pentamidine for a further 11 days. The pulmonary symptoms improved and the interstitial and alveolar pattern decreased; the size of cavitory lesions on chest X-rays remained unchanged. The patient was discharged after 50 days without any residual respiratory symptoms. One month later, a control chest X-ray showed a decrease in size of the cavitations.

Discussion

Many aetiologies may cause pulmonary involvement with cavitations in patients with AIDS. In the present case, an embolic problem (*i.e.* thromboembolic disease, aseptic embolus after drug injection) may be reasonably excluded. Furthermore, there is no evidence for vasculitis. As far as we know, there is no convincing description of cavitating tumours in patients with AIDS

in the literature. Only infectious causes should therefore be considered here, *i.e.* mycobacteria (tuberculosis or atypical mycobacteria), anaerobic abscesses, septic emboli (staphylococci, streptococci, Gram-negative bacteria) and fungi. Our investigations failed to demonstrate any of these pathogens.

PC was the only microorganism that could be identified in BAL, which was a surprising finding, as cavitation is not a classical roentgenographic pattern of PCP. PC may be found in BAL of patients with AIDS after treated PCP without any apparent harmful consequence [5]. However, without a previous history of PCP, the presence of PC is considered as responsible for pulmonary pathological changes [1]. To our knowledge, there is no study demonstrating that PC may be present in the BAL of patients with AIDS without pulmonary involvement and pathological consequences.

The association between PC and cavitations has already been described, but it seems to be rare: up to now, only 18 cases have been described in the literature [3, 4, 6–11]. Sixty cases of PCP in patients with AIDS have been reported in our institution: our case is the only one with thin-walled cavitations without air-fluid levels. These cavitations related to PCP are similar to those reported in the literature [3, 4, 6, 8–10].

By reviewing the only seven well-documented case reports in the literature (table 1), we were not able to determine if there is a specific clinical pattern of PCP with cavitations contrasting with the "classical" PCP.

The response to cotrimoxazole treatment, in our case, does not seem to differ from that in other cases of PCP. Therefore, although the pathogenesis of such pulmonary lesions (*i.e.* cavities) is still undetermined and even though their X-ray aspect suggests that PC may be an invasive microorganism that destroys lung parenchyma [4], this does not necessarily imply that a treatment failure and a poor prognosis are to be expected.

In conclusion, this report adds one more case to the 18 other previously reported cases in the literature. It also confirms that no particular clinical or laboratory patterns are related to PCP cavitory lesions; finally it demonstrates that this particular form of PCP responds quite well to standard PCP treatment regimens.

References

- Ognibene FP, Masur H, Roger P, Travis WD, Suffredini AF, Feuerstein I, Gill VJ, Baird BF, Carrasquillo JA, Parrillo JE, Lane C, Shelhamer JH. – Nonspecific interstitial pneumonitis without evidence of *Pneumocystis carinii* in asymptomatic patients infected with human immunodeficiency virus (HIV). *Ann Intern Med*, 1988, 109, 874–879.
- Rosenow III EC, Wilson WR, Cockerill III FR. – Pulmonary disease in the immunocompromised host (part I). *Mayo Clin Proc*, 1985, 60, 473–487.
- Wilson WR, Cockerill III FR, Rosenow III EC. – Pulmonary disease in the immunocompromised host (part II). *Mayo Clin Proc*, 1985, 60, 610–631.
- Suster B, Akerman M, Orenstein M, Wax MR. – Pulmonary manifestations of AIDS: review of 106 episodes. *Radiology*, 1986, 161, 87–93.
- Eng RHK, Bishburg E, Smith S. – Evidence for destruction of lung tissues during *Pneumocystis carinii* infection. *Arch Intern Med*, 1987, 147, 746–749.
- Barrio JL, Suarez M, Rodriguez JL, Saldana MJ, Pitchenik AE. – *Pneumocystis carinii* pneumonia presenting as cavitating and noncavitating solitary pulmonary nodules in patients with the acquired immunodeficiency syndrome. *Am Rev Respir Dis*, 1986, 134, 1094–1096.
- Febvre M, De Fenoyl O, Capron F, Rochemaure J. – Pneumopathie à *Pneumocystis carinii*: présentation atypique pseudo-tuberculeuse. *Rev Méd Interne*, 1988, 9, 85–88.
- De Lorenzo L, Huang CT, Maguire GP, Stone DJ. – Roentgenographic patterns of *Pneumocystis carinii* pneumonia in 104 patients with AIDS. *Chest*, 1987, 91, 323–327.
- Doppman JL, Geelhoed GW, De Vita VT. – Atypical radiographic features in *Pneumocystis carinii* pneumonia. *Radiology*, 1975, 114, 39–44.
- Scully RE, Mark EJ, McNeely WF, McNeely BU. – Case 9-1989. *N Engl J Med*, 1989, 320, 582–587.
- Chechani V, Zaman MK, Finch PJP. – Chronic cavitory *Pneumocystis carinii* pneumonia in a patient with AIDS. *Chest*, 1989, 95, 1347–1348.

Observation clinique. Pneumonie à Pneumocystis carinii et syndrome d'immuno-déficience acquise. Présentation atypique, avec excavations pulmonaires. J-O. Praz, P. Lorenzi, J.C. Chevolet.

RÉSUMÉ: Le diagnostic différentiel des cavités pulmonaires est particulièrement large. Nous rapportons un cas de pneumonie à *Pneumocystis carinii* (PCP) où le cliché thoracique montrait des excavations pulmonaires chez un patient atteint du syndrome d'immuno-déficience acquise. Nous discutons le diagnostic différentiel d'un aspect radiographique de ce type et insistons sur le fait que les cavitations multiples peuvent être une forme radiologique de PCP. *Eur Respir J.*, 1990, 3, 1221–1223.