

## CASE STUDY

# Necrotizing sarcoid granulomatosis in a 14-yr-old female

E. Tauber\*, C. Wojnarowski\*, E. Horcher\*\*, G. Dekan<sup>†</sup>, T. Frischer\*

*Necrotizing sarcoid granulomatosis in a 14-yr-old female. E. Tauber, C. Wojnarowski, E. Horcher, G. Dekan, T. Frischer. ©ERS Journals 1999.*

**ABSTRACT:** A case of a 14-yr-old female with necrotizing sarcoid granulomatosis (NSG) is presented. She was referred because of chest pain and malaise, and radiography revealed multiple pulmonary nodules. Her history showed seasonal sensitization to aeroallergens and hay fever. Infectious agents or malignancies did not characterize these nodules. However, she was treated with macrolide antibiotics because of suspected infection with *Chlamydia pneumoniae*. Open lung biopsy showed histological findings of NSG, with epithelioid granulomatous inflammation, including giant cells, and vasculitis. No further treatment was performed, and symptoms disappeared within a few weeks. The chest radiograph showed gradual improvement.

The aetiology of NSG is poorly understood, and is postulated to represent either sarcoidosis or rare forms of pulmonary vasculitis such as Wegener's granulomatosis or the Churg–Strauss syndrome. In the case presented, a coincidence of infection with *Chlamydia pneumoniae* suggests an involvement of infectious agents in the pattern of formation of immune complexes in the aetiology of NSG.

*Eur Respir J 1999; 13: 703–705.*

\*Vienna University Children's Hospital, \*\*Dept for Children's Surgery, and <sup>†</sup>Dept for Clinical Pathology, Vienna University, Vienna, Austria.

Correspondence: T. Frischer, University Children's Hospital, Waehringer Guertel 18–20, 1090 Vienna, Austria. Fax: 43 1404003189

Keywords: Child  
chlamydia  
necrotizing sarcoid granulomatosis  
pulmonary granulomatous vasculitis

Received: June 4 1998  
Accepted after revision September 3 1998

## Case history

A 14-yr-old female was referred because of chest pain and malaise. Four weeks before, she had suffered from an asthmatic attack. At that time, the chest radiograph was normal, and she was successfully treated with systemic steroids for less than a week. Before that attack, she had been on antihistamines during the spring for several years, because of seasonal rhinoconjunctivitis.

At admission, the chest radiograph showed multiple ill-defined opacities without hilar lymphadenopathy (fig. 1) and the high resolution computed tomography (CT) scan revealed multiple rounded nodules, suggesting that some nodules were adjacent to intrapulmonary vessels (fig. 2). In serum, the leukocyte count was  $7.7 \times 10^9$  cells·L<sup>-1</sup>, erythrocyte count was  $4.8 \times 10^{12}$  cells·L<sup>-1</sup>, erythrocyte sedimentation rate was 7/14 mm, and C-reactive protein was 55 mg·L<sup>-1</sup>. Respiratory function tests showed a restrictive ventilation pattern (total lung capacity (TLC) was 73% predicted). Serum immunoglobulin (Ig)E was 1,296 U·L<sup>-1</sup>; specific IgE were present against grass-pollen, dog dander and *Dermatophagoides farinae*. Virology, serology against histoplasma, blastomyces and coccidioides, as well as autoantibodies against neutrophil contents (p-antineutrophil cytoplasmic antibody (ANCA), c-ANCA) were negative in serum. A cutaneous test for tuberculosis was negative. Angiotensin-converting enzyme serum level was 14.8 U·L<sup>-1</sup> (normal range in this laboratory is 8–52 U·L<sup>-1</sup>). Abdominal organs were normal, proven by sonography and there were no skin alterations. Bone marrow biopsy showed normal cell distribution, without signs of malignancy. Skeletal radiograph, neurological and ophthalmological examinations did not reveal abnormalities. IgM antibodies against *Chlamydia pneumoniae* were pos-

itive, and the antibody titre fell from 1:640 to 1:320 within one week.

Fibreoptic bronchoscopy with bronchoalveolar lavage (BAL) and mucosal biopsy was performed. Granulomatous alteration of the mucosa in the whole bronchial tree, and compressed subsegmental airways were found. In BAL cytology, there were 82% macrophages including some giant cells, 17% lymphocytes and 1% neutrophil granulocytes, comparable with the diagnosis of lymphocytic alveolitis. The cell ratio of CD4+/CD8+ could not be

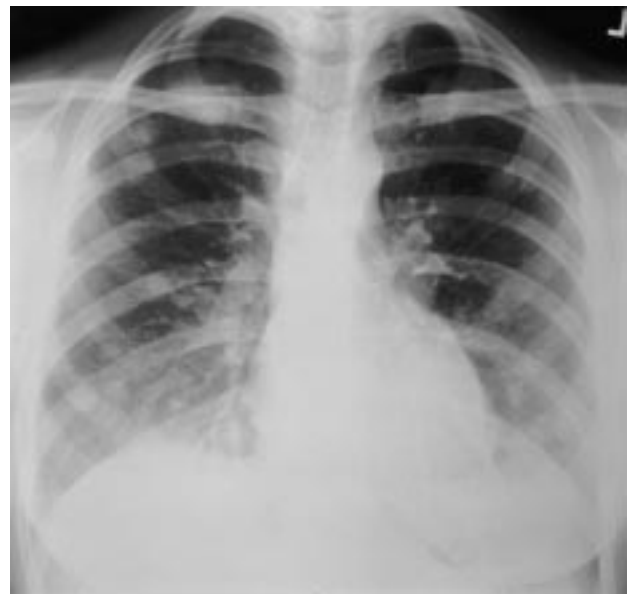

Fig. 1. – Chest radiograph frontal view, at admission showing multiple ill-defined opacities.

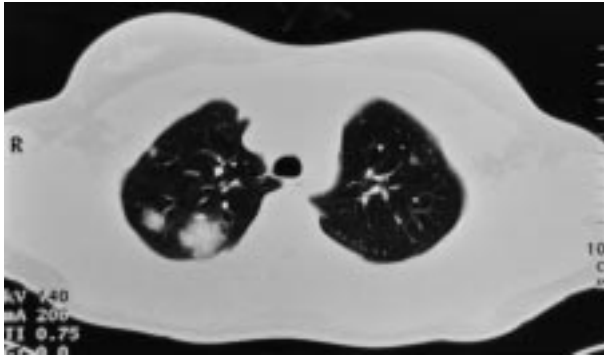


Fig. 2. – Computed tomography scan of the thorax, above the aortic arch, showing nodules.

assessed because of the lack of available cells. There was no evidence of bacteria or other infectious organisms. Cultures for bacteria, including *Mycobacterium tuberculosis*, as well as for fungi, were negative. Bronchial biopsy revealed mild chronic bronchitis, with thickened basement membrane and a mild increase of eosinophil granulocytes, but no evidence of granulomas.

Because of suspected infection with *C. pneumoniae* antibiotic treatment with clarithromycin (7 mg·kg body weight<sup>-1</sup>) was initiated. However, the chest radiograph nodules remained unchanged.

Lung biopsy by video-guided thoracoscopy was performed in the right upper lobe. Massive postpleuritic adhesions were noticed. Two inflammatory yellowish lesions were observed in the right upper lobe, a large one in the apex and a smaller one of 1 cm diameter in the anterior segment of the upper lobe. This smaller one was chosen for biopsy, and was removed together with adjacent lung parenchyma by the endoGIA stapler technique after appropriate adhesiolysis. The resected lung segment was removed by a small thoracotomy of 4 cm. The specimen was cut and revealed a small nodule, filled with necrotic tissue.

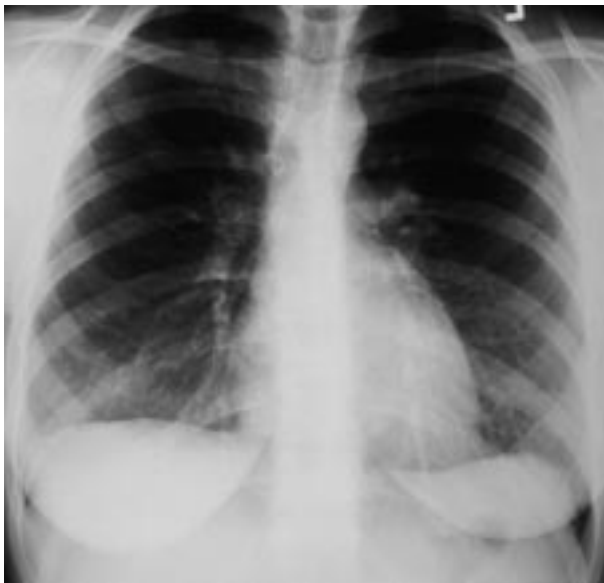

Fig. 3. – Chest radiograph frontal view, after remission, showing gradual improvement compared with radiograph at admission.

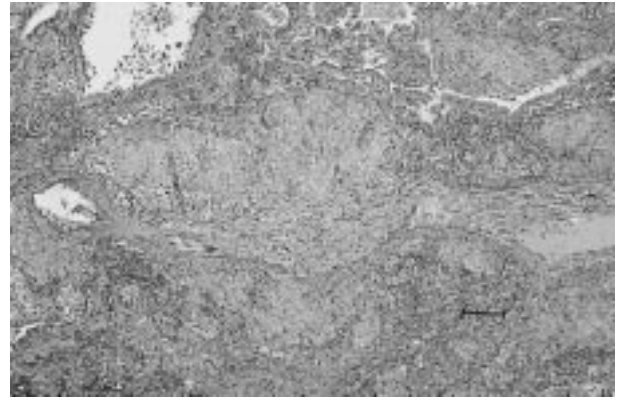


Fig. 4. – Light microscopy of thoracoscopic biopsy specimen of pulmonary granuloma elastica stain, showing necrotizing and non-necrotizing granuloma including multinuclear giant cells and necrotizing lung tissue. Internal scale bar = 125 µm.

Histological examination was consistent with the diagnosis of sarcoid necrotizing granulomatosis (NSG). Symptoms disappeared within a few weeks after biopsy without further treatment, and the chest radiograph showed gradual improvement as well (fig. 3).

### Histology

Two surgical specimens with major diameters of 25 and 15 mm were examined. The cut surface was emphysematous and haemorrhagic, and the pleura was thickened. Histologically, aggregates of non-necrotizing granulomas, including multinucleated giant cells, were located in a lymphangitic peribronchovascular and pleural distribution (fig. 4). Some granulomas demonstrated central necrosis. There was occlusive narrowing of blood vessels owing to granulomas involving the vessels but no thrombosis was seen. Focally, in these areas, blood vessels were completely obliterated by connective tissue (fig. 5). Necrosis appeared eosinophilic in haematoxylin and eosin stained sections. Bronchioli and small bronchi showed a mild-to-moderate chronic inflammation, some bronchi with hyperplastic epithelium and thickened basement membranes were filled with mucus. There was no bronchocentric necrosis or

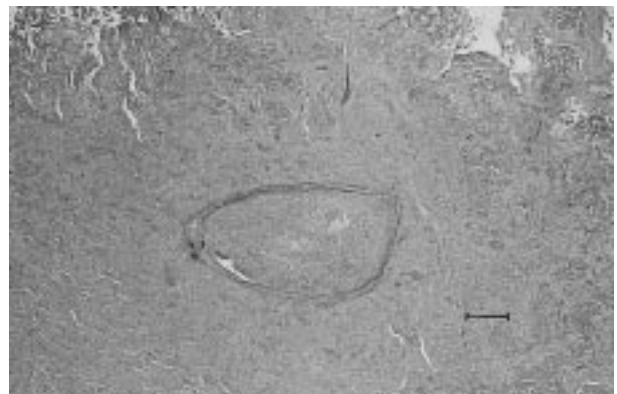


Fig. 5. – Light microscopy of thoracoscopic biopsy specimen of pulmonary granuloma elastica stain, showing total obliteration of intrapulmonary arteries, embedded in necrotic lung tissue. Internal scale bar = 125 µm.

eosinophilic or neutrophilic granulocytes. Special stains for infectious organisms including acid-fast bacilli were negative.

In summary, histology of lung biopsy specimens revealed extensive sarcoid-like granulomas, a prominent granulomatous vasculitis and infarct-like necrosis. This is consistent with the diagnosis of NSG.

### Discussion

NSG [3] is a very rare disease, and to the authors' knowledge it has been reported only twice before in a child. In one report [4], an 11-yr-old male had been referred because of a 6-month history of neurological and ophthalmological complaints. SINGH *et al.* [5] reported the case of a 12-yr-old female with a cerebral lesion diagnosed as NSG. Hence, the present case seems to be the first presented occurrence of NSG in childhood with isolated pulmonary involvement.

NSG is defined histologically [6, 7] by sarcoid-like granulomata, granulomatous vasculitis and necrosis, superimposed upon confluent granulomas. The radiograph [8] shows pulmonary nodules, and usually, the clinical course [1] is benign, even without treatment.

The aetiology of NSG is unclear, and there are similarities in the previously reported cases, as well as in the presented case to other, yet better defined forms of pulmonary vasculitis, as well as to sarcoidosis [2]. First of all, there are histological similarities between the non-necrotizing granulomas of NSG and those seen in sarcoidosis. The angiitis seen in NSG also occurs in classical sarcoidosis, but in less severe form. The benign clinical course of most patients suffering from NSG is similar to the favourable outcome for sarcoidosis. Typical chest radiograph findings for sarcoidosis, such as hilar lymphadenopathy, as well as elevated serum angiotensin-converting enzyme level which is often present in acute sarcoidosis, did not occur in this case and not in most of the previously presented cases. However, some authors [1, 9, 10] doubt the existence of NSG as a distinct entity, but consider it to be a subform of sarcoidosis.

An additional interesting fact in the present case was the coincidence of a suspected infection with *C. pneumoniae* at the same time as pulmonary nodules were revealed. Although the nodules were identified as necrotizing sarcoid granulomatosis-granulomas without any evidence of involvement of infectious agents, another mechanism can influence the pathogenesis of pulmonary vasculitis, as

described by LEAVITT and FAUCI [11]. Inhaled or circulating antigens may elicit an antibody response with the consecutive formation of immune complexes in the pattern of a type III reaction. Since the lung is an organ with high blood flow, deposition of such complexes there is not unlikely. These immune complexes can be triggers for subsequent inflammatory activities and formation of granulomas. However, immune complexes have not been detected in necrotizing sarcoid granulomatosis, nor have they been consistently detectable in other forms of pulmonary vasculitis.

### References

1. Luce JM. Vasculitis, primary pulmonary hypertension, and arteriovenous fistulas. *In: Murray JF, Nadel JA, eds. Textbook of Respiratory Medicine. Philadelphia, WB Saunders, 1998; pp. 1328–1355.*
2. Studdy PR. Sarcoidosis. *In: Brewis RAL, Gibson GJ, Geddes DM, eds. Respiratory Medicine. London, Bailliere Tindall, 1990; pp. 117–1148.*
3. Liebow AA. The J. Burns Amberson lecture: pulmonary angiitis and granulomatosis. *Am Rev Respir Dis* 1973; 108: 1–17.
4. Beach RC, Corrin B, Scopes JW, Graham E. Necrotizing sarcoid granulomatosis with neurologic lesions in a child. *J Pediatr* 1980; 97: 950–953.
5. Singh N, Cole S, Krause PJ, *et al.* Necrotizing sarcoid granulomatosis with extrapulmonary involvement. *Am Rev Respir Dis* 1981; 124: 189.
6. Koss MN, Hochholzer L, Feigin DS, *et al.* Necrotizing sarcoid-like granulomatosis; clinical, pathological and immunopathologic findings. *Human Pathol* 1980; 11: 510.
7. Le Gall F, Loeuillet L, Deleval P, Thoreux PH, Desrues B, Ramee MP. Necrotizing sarcoid granulomatosis with and without extrapulmonary involvement. *Path Res Pract* 1996; 192: 306–313.
8. Niimi H, Hartmann TE, Müller NL. Necrotizing sarcoid granulomatosis: computed tomography and pathologic findings. *J Comput Assist Tomogr* 1995; 19: 920–923.
9. Churg A, Carrington CB, Gupta R. Necrotizing Sarcoid Granulomatosis. *Chest* 1979; 76: 406–413.
10. Gibbs AR, Anderson A. Pulmonary vasculitis and eosinophilic pneumonia. *In: Brewis RAL, Gibson GJ, Geddes DM, eds. Respiratory Medicine. London, Bailliere Tindall, 1990; pp. 1165–1182.*
11. Leavitt RY, Fauci AS. State of the art: pulmonary vasculitis. *Am Rev Respir Dis* 1986; 134: 189.