

## CLINICAL REVIEW

# Many faces of pulmonary aspergillosis

O.P. Sharma\*, R. Chwogule\*\*

*Many faces of pulmonary aspergillosis. O.P. Sharma, R. Chwogule. ©ERS Journals Ltd 1998.*

**ABSTRACT:** *Aspergillus* is a ubiquitous fungus. It is commonly isolated as an upper respiratory tract saprophyte and is the most frequent contaminant in laboratory specimens. Because species of *aspergillus* are omnipresent, one must be cautious in ascribing a causal role to the fungus obtained from patients. *Aspergillus* has low pathogenicity for humans and animals and rarely invades the immunologically competent host. Although the fungus can affect any organ system, the respiratory tract is involved in >90% of afflicted patients. Pulmonary aspergillosis, depending whether the host is atopic or immunosuppressed, may be classified under four categories: allergic or hypersensitivity syndromes, saprophytic colonization, invasive (infective) dissemination, and chemical or toxic pneumonitis. These entities differ clinically, radiologically, immunologically, and in their response to various therapeutic agents. An increased awareness, an aggressive approach to securing the diagnosis, and instituting early and appropriate therapy are needed to reduce the high morbidity and mortality caused by many of the *aspergillus*-related syndromes.

*Eur Respir J 1998; 12: 705–715.*

\*USC School of Medicine, Los Angeles, CA, USA. \*\*Bombay Hospital, Bombay, India.

Correspondence: O P. Sharma, LAC+USC Medical Center, Room 11-900, 1200 North State Street, Los Angeles, CA 90033, USA. Fax: 1 213 2262738

Keywords: Allergic bronchopulmonary aspergillosis, aspergilloma, bronchocentric granulomatosis, chronic necrotizing pulmonary aspergillosis, extrinsic allergic alveolitis, mycotoxicosis

Received: 23 April 1998  
Accepted after revision May 6 1998

*Aspergillus* belongs to the ascomycete moulds, which together with penicillium form the family of Aspergillaceae. These filamentous fungi are ubiquitous and are commonly in humid areas, damp soil or agricultural environments, on grain, cereal, mouldy flour, and organic decaying or decomposing matter. *Aspergillus* grow by budding or branching. The former or conidium, 1–3 µm in diameter, are carried by air and easily inhaled in the lungs. The branching hyphae are 2–5 µm in diameter, split dichotomously at a 45° angle, and are best recognized by methanamine silver stain.

Of more than 350 species that belong to the genus *aspergillus*, only *Aspergillus fumigatus* and *A. niger* produce disease in humans with any frequency. Under certain conditions, however, *A. clavatus*, *A. glaucus*, *A. flavus*, *A. versicolor*, *A. nidulans* and *A. oryzae* can cause infection in humans and animals.

Humans have a remarkable capacity to eliminate *aspergillus* with the help of alveolar macrophages which phagocytose and destroy the inhaled spores. Thus, *aspergillus* rarely invades the immunocompetent host. Nevertheless, *aspergillus* can cause a variety of clinical syndromes ranging from mild, transient asthma to fatal, disseminated disease, particularly in the immunosuppressed host. *Aspergillus*-related pulmonary disorders may be classified into four clinical categories depending on whether the host is atopic, nonatopic or immunosuppressed (table 1). Some of these clinical entities are well defined and common; others are unusual but recognized; and, still others rare and controversial [1–6]. The key points in the pathogenesis, immune response, diagnosis and treatment of each syndrome are summarized (tables 2 and 3).

## Allergic or hypersensitive reactions

### *Allergic asthma*

STORM VAN LEEUWEN [1] was the first to attribute a role to *A. fumigatus* in the causation of asthma in Leyden. *Aspergillus* is responsible for asthma to the same extent as *Alternaria*, *Penicillium*, and other fungi. The illness seems to be more common in the UK, 10–20% of cases with respiratory problems, and in Holland about 15%. Since *aspergillus* grows in humid dwellings on wood and old furniture, on dusty belongings, and on indoor plants, asthma episodes are clinically due to domestic exposure in the USA, such episodes are more common between October and

Table 1. – Pulmonary aspergillosis clinical syndromes

Allergic or hypersensitivity reactions
Allergic asthma
Allergic bronchopulmonary aspergillosis
Extrinsic allergic alveolitis (malt-worker's lung)
Bronchocentric granulomatosis
Invasive (infective) aspergillosis
Generalized or disseminated
Aspergillosis pneumonia
Lung abscess and multiple cavities
Aspergillosis bronchitis
Infarction
Pleural effusion and empyema
Localized or limited: chronic necrotizing pulmonary aspergillosis
Saprophytic colonization
Aspergilloma (mycetoma or fungus ball)
Mycotoxicosis or chemical pneumonitis

Table 2. – Pulmonary aspergillosis: immunological and diagnostic tests

Syndromes	Type I reaction		Type III reaction		Type IV reaction	Other diagnostic tests
	Immediate cutaneous hypersensitivity	Serum IgE	Delayed (Arthus) skin reaction	Precipitating antibodies		
Allergic asthma	Positive	Increased	Absent	Absent	Absent	Reversible airway obstruction
Allergic bronchopulmonary aspergillosis	Positive	Markedly increased	Present	Present	Absent	Bronchogram (high resolution CT, rarely obtained)
Extrinsic allergic alveolitis (malt-worker's lung)	Usually positive	Usually normal	Present	Present	Absent	Lung histology, inhalation challenge (rarely used)
Bronchocentric granulomatosis	May be positive	May be increased	May be present	May be present	-	Lung histology
Pneumonia, lung abscess, bronchitis, infarction	May be positive	Normal	Absent*	Absent*	-	Sputum, blood, urine cultures
Multiple cavities, pleural effusion	Usually negative*	Normal	Absent*	May be present	-	Sputum, blood, urine cultures
Chronic necrotizing pulmonary aspergillosis	-	-	-	May be present	-	Lung biopsy
Aspergilloma	May be positive	Normal	Present	Very high	-	Chest radiograph, CT

\*: opinions expressed in the medical literature are divided regarding these findings, but many of these tests will be positive if the high-quality antigen is used and a research laboratory performs the tests. IgE: immunoglobulin E; CT: computed tomography.

February, when aspergillus spore count is high, than at other times of the year. Although humidity, rain and wind play an important role in disseminating the spores, the peak levels are greater during fair weather that follows a period of rain. At any rate, CHARPIN *et al.* [2] have demonstrated that the spores of aspergillus are present in all seasons.

An intracutaneous test using aspergillus antigen produces an immediate wheal and flare reaction in asthma patients who are allergic to the mould. Furthermore, inhalation of the antigen causes rapid bronchospasm. In making the diagnosis, however, the physician should be cautious, because 30–40% of patients with non-aspergillus induced asthma may also have a positive reaction to Aspergillus skin test. Precipitating (immunoglobulin (Ig)G) antibodies are usually absent in such patients. Treatment includes  $\beta$ -adrenergic agonists, as needed, to relieve symptoms. Cromolyn or nedocromil sodium can prevent symptoms if the drug is administered before anticipated exposure to the allergen.

### Allergic bronchopulmonary aspergillosis

HINSON *et al.* [7] provided the first descriptions of allergic bronchopulmonary aspergillosis (ABPA), followed by PEPYS *et al.* [3]. CAMPBELL and CLAYTON [8] reported 87 cases, FRANKLAND and DAVIS [9] 36 cases, HENDERSON [10] 32 cases, SIMON [11] 111 cases and EDGE *et al.* [12] 12 cases, all in the UK. In the USA, this disorder was thought to be rare. However, SHAW *et al.* [13] described 36 cases under the term "mucoid impaction" in which aspergillus aetiology was almost certain. The incidence of ABPA varies from 6–20% of all patients with asthma [14]. It occurs with equal frequency in both sexes. Most patients are under age 35 yrs at the time of diagnosis. In patients with cystic fibrosis, the prevalence of ABPA is 0.5–11%.

The disease manifests itself with low-grade fever, cough, wheezing, golden, brown mucus plugs, and progressive shortness of breath. Pleuritic chest pain and haemoptysis are frequent. PATTERSON and coworkers [15–17] have proposed five stages of ABPA. However, these stages are not

Table 3. – Pulmonary aspergillosis: clinical syndromes and treatment

Syndromes	Immunological mechanism	Host		Treatment
		Atopic	Immuno-suppressed	
Allergic asthma	Hypersensitivity (type I)	Yes	No	Bronchodilators
Allergic bronchopulmonary aspergillosis	Hypersensitivity (types I and III)	Yes	No	Corticosteroids, bronchodilators
Extrinsic allergic alveolitis (malt-worker's lung)	Hypersensitivity (types III and IV)	No	No	Corticosteroids, avoidance of exposure
Bronchocentric granulomatosis	Hypersensitivity (types III and IV)	Some	No	Corticosteroids
Pneumonia, lung abscess, bronchitis, infarction	Invasive (infective) localized disease	No	Yes	Amphotericin B
Multiple cavities, pleural effusion	Invasive (infective) disseminated disease	No	Yes	Amphotericin B
Chronic necrotizing pulmonary aspergillosis	Invasive, chronic, localized disease	No	Yes	Amphotericin B
Aspergilloma	Saprophytic colonization	No	No	Surgery only if haemoptysis is present, embolization, intracavitary antifungal drugs
Mycotoxicosis	Chemical, pneumonitis	No	No	Corticosteroids

Table 4. — Allergic bronchopulmonary aspergillosis: clinical stages

Stage	Clinical features	Chest radiograph	Serum IgE		Peripheral eosinophilia	Precipitating antibody to Af
			Total	IgE-Af		
I Acute	Cough, wheezing, fever, sputum plugs may be present	Transient lung infiltrates	+++	+	+	+
II Remission	Usually no symptoms	No radiographic infiltrate	+	+/-	-	+/-
III Exacerbation	Fever, cough, and wheezing may be absent	Pulmonary infiltrates	+++	+	+	+
IV Corticosteroid dependent asthma	Persistent disabling wheezing	Pulmonary infiltrate usually absent	++	+/-	+/-	+/-
V Fibrotic	Dyspnoea, wheezing, clubbing of the fingers, cyanosis, chronic sputum production	Extensive fibrosis/honey-combing, segmental/lobar atelectasis	+	+/-	-	+/-

IgE: immunoglobulin E; Af: *Aspergillus fumigatus*; IgE-Af: specific IgE direct against Af. +: presence of; -: absence of.

necessarily phases of the disease, and there is not always an inexorable progression of the disease from stage I to the end stage fibrosis of stage V (table 4).

Physical examination may reveal a prolonged expiratory phase and diffuse rhonchi in almost all patients; whereas, crackles or crepitations are present only in those with pulmonary infiltrates.

Eosinophilia is almost always present with absolute counts over 500 cells-mm<sup>-3</sup> and usually over 1,000 cells-mm<sup>-3</sup>; however, ABPA has been identified in patients without elevated eosinophil counts. Sputum eosinophils are often present. Levels of total IgE and specific IgE for aspergillus species (IgE-Af) are increased. IgE-Af determination is useful in excluding mould-sensitive asthmatics without ABPA who either have very low or absent isotypic antibodies to aspergillus. Serum precipitating antibodies or precipitins (IgG) are positive in >90% of cases, but one should not exclude ABPA in a patient with con-

sistent clinical and radiographic findings if precipitating antibody to aspergillus (IgG-Af) is absent. IgE levels are the best indicator of disease activity and should be monitored regularly (fig. 1). However, occasionally, the total serum IgE level may remain elevated in a patient who has otherwise responded to prednisone. In bronchoalveolar lavage fluid, increased levels of IgE-Af are found, reflecting the role of the lung as a specific immunological organ. This observation, however, provides no diagnostic or therapeutic assistance.

Skin test reactivity to aspergillus antigen manifests immediate, IgE-dependent as well as late (4–8 h) reactions. Positive reactions may occur in patients with asthma, aspergilloma, and other chronic pulmonary diseases.

Chest radiographs commonly reveal transient, patchy infiltrates and/or lobar collapse and/or consolidation. Characteristically, these infiltrates favour the upper lung fields. Mucus plugging may cause segmental, lobar or total collapse of the lung. "Tram line", "gloved finger", and "ring" shadows reflect inflammation, thickening and dilation of the bronchial tubes (fig. 2a and b). Bronchiectasis, when it appears, is typically central in location and involves the proximal airways (fig. 3). In the advanced stages, loss of volume of the upper lobes and extensive honeycombing dominate the picture. High resolution computed tomography (CT) scanning is the best way of demonstrating bronchial and pulmonary effects of ABPA [18].

The pathogenesis of ABPA involves the inhalation, trapping, and subsequent germination of aspergillus spores in viscid secretions in the airways of atopic individuals, as well as cystic fibrosis patients. The host response with production of IgE and IgG sets in motion a series of antibody-antigen reactions that result in eosinophilic infiltration and bronchial wall damage. It is the immune complex injury that produces bronchiectasis. The presence of IgE is essential to enhance the tissue-damaging effect of immune complexes. The presence of activated epithelial cells and the exposure of the basement membrane that occurs in asthma, together with oxidant stress, may facilitate the colonization of the asthmatic lung by *A. fumigatus* [19, 20].

Diagnosis of ABPA requires immunological and radiological confirmation in an appropriate clinical setting. RICKETTI *et al.* [21] have proposed a sequential approach to evaluating patients suspected of having ABPA. First begin with skin tests (the prick test), and if necessary, an intra-

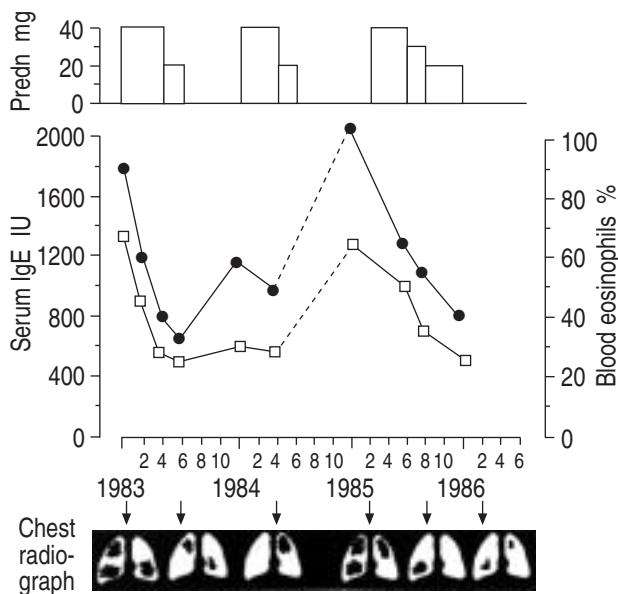


Fig. 1. — Serum immunoglobulin E (IgE) levels and eosinophilia in a patient with allergic bronchopulmonary aspergillosis. The response to corticosteroid treatment (●: serum IgE; □: eosinophils, as percentage of total white blood cells; - - - : lost to follow up). Schematic chest radiographs are also shown. Predn: prednisone (daily). †: when chest radiographs taken.

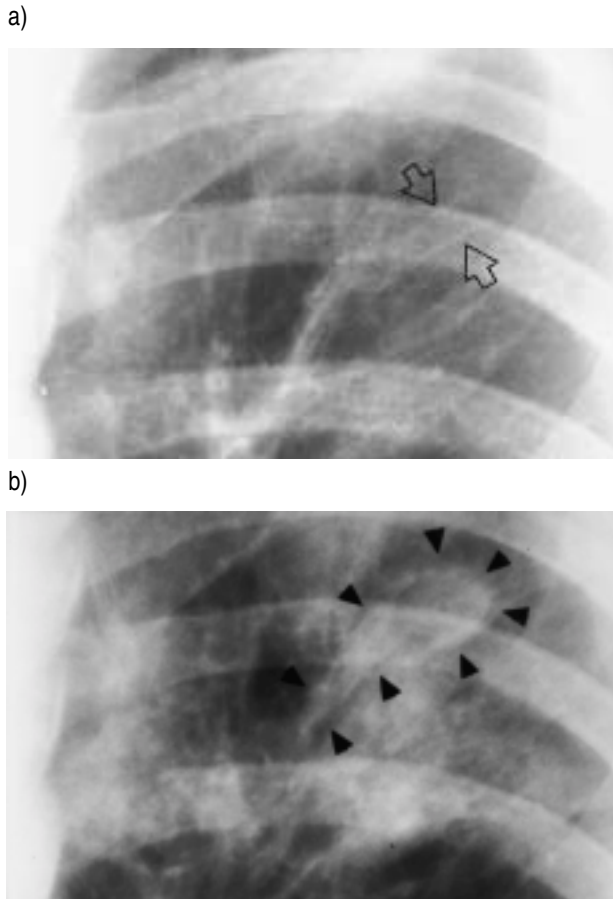


Fig. 2. – Chest radiographs of allergic bronchopulmonary aspergillosis patients showing a) "tram-line" shadows (arrowheads) due to bronchial thickening and dilatation, and b) "club-shaped" shadows (arrows) due to saccular dilatation of proximal bronchi.

dermal test using *Aspergillus* antigen. The immediate reaction appears in a few minutes and lasts 1–2 h, and the late reaction appears after 4–5 h and lasts for 24–36 h. Only the latter reaction is inhibited by corticosteroids. Negative skin tests exclude ABPA. On the other hand, positive results lead to the prompt ordering of serological tests including total serum IgE, radioallergosorbent test (RAST) IgE-Af, and IgG [22, 23].

The most effective treatment of ABPA is with corticosteroids [24]. Prednisone is usually given as a single oral dose of  $0.5 \text{ mg} \cdot \text{kg}^{-1} \cdot \text{day}^{-1}$  for 2 weeks. The same dose is then given on alternate days for 2–3 months and then tapered to the lowest dose needed to control symptoms. Corticosteroids control eosinophilia, decrease lung infiltrates, sputum production, and total IgE level. The role of antifungal drugs is not yet established but there are several reports that describe the beneficial effects of itraconazole in ABPA [25–27].

#### ABPA and cystic fibrosis

*Aspergillus* species are recovered from ~10% of cystic fibrosis patients. The recovery rates increase with age [25–27]. The clinical significance of the fungus in these patients varies. Many patients are asymptomatic with colonized

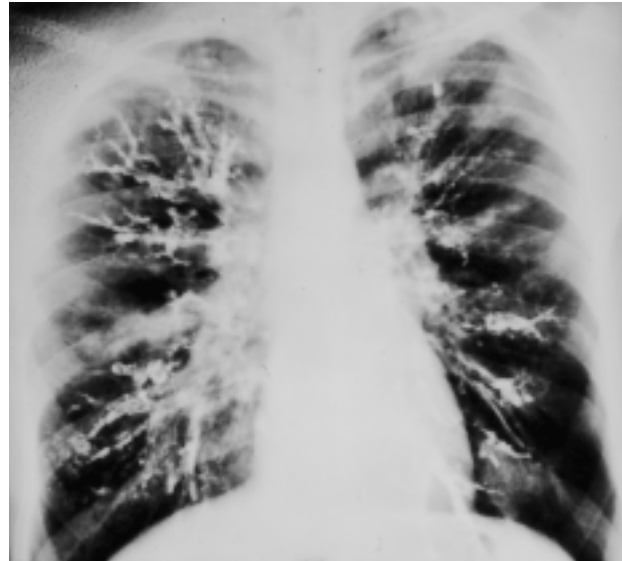


Fig. 3. – Bronchogram in a patient with allergic bronchopulmonary aspergillosis showing extensive medium sized bronchial involvement.

*aspergillus*. However, ABPA may complicate cystic fibrosis. The diagnosis then requires clinical and immunological confirmation, not simply isolation of the fungus. Invasive aspergillosis is not common in cystic fibrosis patients.

#### Extrinsic allergic alveolitis

In 1928, PASTEUR and GIROUD [28] described five workers in a distillery who had inhaled massive amounts of *A. fumigatus* or *A. clavatus*. Several hours afterwards, dyspnoea appeared with fever, cough, and crepitations on auscultation. Serum-precipitating antibodies were present in three patients. The skin test produced a delayed positive reaction. RIDDLE *et al.* [29] reported a 42-yr old brewery worker with interstitial disease due to *A. clavatus* in which the clinical and immunological findings were similar to those of farmer's lung disease. RHODY *et al.* [30] reported a case of extrinsic allergic alveolitis (EAA) due to *A. versicolor* in a 43-yr old female, who was exposed to handling mouldy straw. The EAA caused by aspergillus species is also called malt-worker's lung. It occurs mainly in nonatopic individuals who work in the whiskey and beer-brewing industries, where germinating barley is contaminated by *A. fumigatus* or *A. clavatus*. After initial exposure, there is a latent period of variable duration during which appropriate precipitating antibodies are formed. There are four modes of presentation: 1) acute episodes of fever, cough, dyspnoea, and tightness of the chest occurs in about one third of the patients; 2) progressive dyspnoea seen in ~50% of patients; 3) ~10% present with asthma-like picture (these patients are usually atopic); and 4) a mixed presentation in the remaining 10% of patients [5].

Physical examination in acute stages may reveal cyanosis and tachycardia. Crepitations are present; wheezing is usually absent. In advanced cases, there may be features of right-sided heart failure.

Chest radiographs typically show diffuse, fine nodular infiltration or patchy densities. In the chronic stage,

reticulo-interstitial pattern and honeycombing may be seen. A lung biopsy specimen in acute stages may reveal granulomatous reaction with lymphocytic infiltration. Fibrosis and cyst-formation occur in chronic disease.

Lung function studies reveal a restrictive ventilatory defect caused by reduced lung compliance. Vital capacity, forced expiratory volume in one second (FEV<sub>1</sub>) and diffusing capacity are decreased. Airways obstruction is present, particularly in atopic patients. Corticosteroids are effective for controlling symptoms in acute stages. However, exposure to the aspergillus antigen needs to be avoided in order to prevent recurrence and progression to pulmonary fibrosis.

### Bronchocentric granulomatosis

Although bronchocentric granulomatosis (BG) is a well-defined pathological entity, the clinical diagnosis is often difficult (fig. 4) [31, 32]. BG occurs both in atopic and nonatopic individuals. The atopic patients are generally younger and have a history of asthma. Eosinophilia is present and mucus plugs contain fungal hyphae. The non-atopic individuals constitute a much more heterogeneous group. Immunological mechanisms causing BG are not clearly understood, but the basic abnormality seems to be a hypersensitivity to fungal organisms. Serum precipitin antibodies (IgG) are present in ~40% of atopic patients with BG. Corticosteroids are useful in treating patients with BG who have asthma. The prognosis is not favourable in nonatopic patients, but the information available is limited. One patient with bronchocentric granulomatosis developed severe acute respiratory distress syndrome (ARDS) with peripheral blood eosinophilia. The patient was intubated and treated with high-dose corticosteroid therapy. The illness subsided and showed no recurrence during the 20-yr follow-up [33].

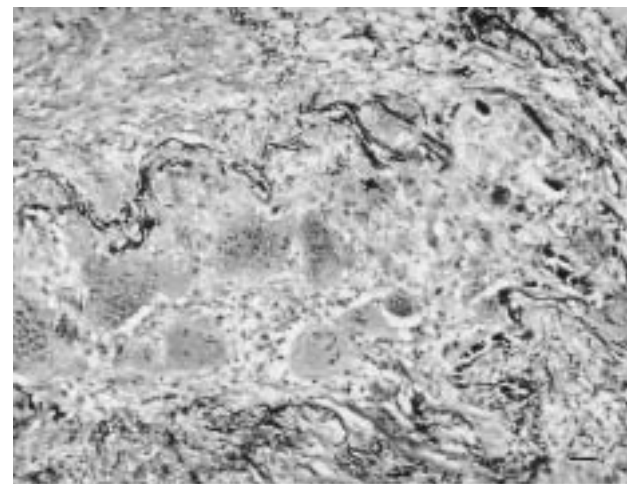
### Invasive (disseminated) aspergillosis

Invasive pulmonary aspergillosis is characterized by proliferation of fungal mycelia in the pulmonary parenchyma. Invasion of the pulmonary vasculature may result in haemorrhagic infarction. Invasive fungal infection can remain dormant for some time, and then produce septic shock precipitously [34]. Factors which predispose to the development of invasive aspergillosis are neutropenia, leukaemia, carcinoma, immunosuppression with corticosteroids or immunosuppressive agents including cyclosporine, bone marrow or solid organ transplants, and chronic granulomatous disease of childhood. Therefore, a high index of suspicion should be maintained in such patients. Patients with human immunodeficiency virus (HIV) are not at a high risk unless other factors are present. A comparison of aspergillosis in HIV-positive and HIV-negative patients was carried out by *ADDRIZIO-HARRIS et al.* [35]. In both groups, tuberculosis and sarcoidosis were significant risk factors. In HIV-positive patients, prior *Pneumocystis carinii* pneumonia (PCP) also seemed to be a risk factor as 3 of the 10 HIV infected patients with aspergillosis had prior episodes of PCP. Invasive aspergillosis has been rep-

orted in HIV patients with CD4 cell counts <500 cells·mL<sup>-1</sup> [36, 37]. Because neutrophils and other phagocytic cells are the principal defence against aspergillus, profound neutropenia (<1,000 cells·mm<sup>-3</sup>) that persists for >3 weeks is the most significant risk factor. Macrophages are the first line of defence; they kill conidia. The second line of defence consists of neutrophils, which dispose of mycelia. Neither humoral antibodies nor T-cell-mediated immunity play a significant protective role against the fungus [38]. Invasive aspergillosis is rare in normal healthy people and less than 20 such cases have been described. In immunocompetent hosts marijuana smoking and broad spectrum antibiotics can contribute to invasive aspergillosis [39, 40].

The typical victim of invasive aspergillosis is a neutropenic (<1,000 cells·mm<sup>-3</sup>) individual who is receiving cancer chemotherapy. The patients have persistent fever for which they have either received, or are receiving, multiple antibiotics. Fever may be associated with nasal and sinus congestion, chest pain, cough, dyspnoea, and either blood streaking of the sputum or frank haemoptysis. The following forms of invasive aspergillosis often occur together, but they may also be seen independently.

a)



b)

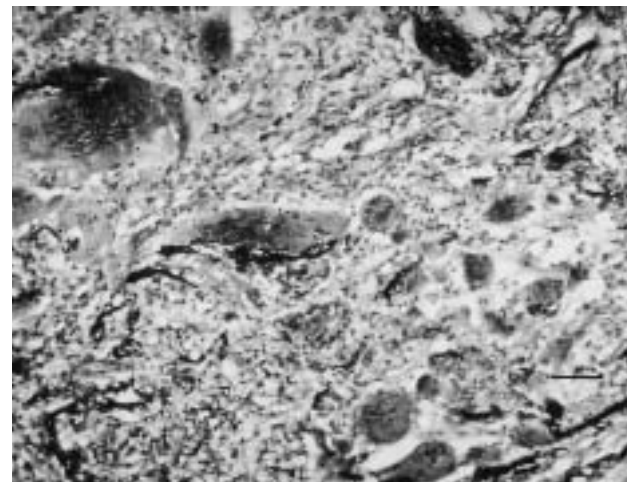


Fig. 4. — Bronchocentric granulomatosis: a) granulomatous replacement of the bronchiolar mucosa with occlusion of the lumen; b) destruction of the bronchial wall is evidenced by the giant cell reaction with damaged multilaminated elastic lamellae. (Internal scale bars=25 µm.)

### *Aspergillus pneumonia*

The clinical picture resembles any acute bacterial or fungal pneumonia. Initially chest radiographs show only a patchy infiltrate or pneumonitis that may progress to dense consolidation involving one or both lungs [41]. Despite such extensive disease, isolation of aspergillus from sputum samples has been possible in less than half the cases [42–44].

### *Angioinvasive aspergillosis*

This spreads by vascular dissemination. It causes thrombosis and necrosis. The symptoms are intense pleuritic chest pain, sudden dyspnoea, tachypnoea and haemoptysis. In approximately one third of patients, the chest radiographs are normal if they are obtained on the day of onset of symptoms. However, if obtained later, the chest radiograph may show a triangular or oval infiltrate with or without pleural effusion. CT scans of the chest may reveal a round or triangular mass with a characteristic "halo". Pathologically, these lesions represent well-circumscribed nodules with a pale yellow centre of coagulative necrosis surrounded by a haemorrhagic periphery [41, 45].

### *Aspergillus bronchitis/tracheobronchitis*

This is a localized form of airway disease characterized by ulcers and membrane formation. Aspergillus hyphae invade the airways and form plugs consisting of mycelia, inflammatory cells, and necrotic debris. These plugs along with the membranes produce airway obstruction resulting in wheezing and dyspnoea. Approximately 10% of patients who have invasive aspergillosis develop tracheobronchitis either alone or with pneumonia. A new antifungal drug terbinafin has been successfully used to treat aspergillus bronchitis in a lung transplant recipient [46]. Aspergillus sinusitis can occur in patients with HIV infection [47].

### *Pleural effusion or empyema*

This is a rare manifestation of invasive aspergillosis.

### **Diagnosis of invasive aspergillosis**

The clinical course of invasive aspergillosis is often fulminant and fatal. In many instances this is traceable to a delay in the diagnosis. Such delays are partly related to the fact that the diagnosis is not considered (especially in immunocompromised hosts) partly because the sputum smear or culture lacks sensitivity and specificity in establishing the diagnosis. To avoid the diagnostic pitfalls the clinician must maintain a high index of suspicion for invasive aspergillosis: 1) invasive aspergillosis should always be included in the differential diagnosis of fever, pulmonary infiltration, cavity formation or pleural effusion in an immunocompromised host; 2) repeatedly positive sputum cultures for aspergillus in a susceptible individual should always point towards this diagnosis; and 3) in a granulo-

cytic patient with acute leukaemia a single isolation of aspergillus from sputum; bronchial washing or brushing may be highly significant.

Definite diagnosis, however, requires the demonstration of mycelia, morphologically consistent with aspergillus, invading lung parenchyma in addition to a positive fungal culture. These are often not considered practical requirements in patients with acute leukaemia or a recent bone marrow or solid organ transplant. Empirical treatment should never be withheld in a neutropenic patient in whom invasive aspergillosis is considered.

Aspergillus from sputum samples in patients with invasive pulmonary aspergillosis can be isolated in approximately half of the cases, but it usually lags behind the clinical onset by a week [42–44]. Similarly, the finding of aspergillus in surveillance cultures lacks sensitivity. Bronchoscopy has an overall yield of approximately 50% for recovery of aspergillus. HARVATH and DUNNER [48] analysed 82 lower respiratory tract cultures for aspergillus species in 80 patients at risk for invasive disease. Definite or probable invasive pulmonary aspergillosis was diagnosed in 72% of episodes from patients with haematological malignancy, granulocytopenia or bone marrow transplants; in 58% of those with solid tumours or receiving corticosteroids; and in 14% with HIV. Thus, recovery of aspergillus from the lower respiratory tract in susceptible individuals constitutes presumptive evidence of fungal invasion [48].

Counter immunoelectrophoresis, immunofluorescence and complement fixation tests are used to detect aspergillus antibodies. However, these tests, as well as radioimmune assays, depend on a normal host immune response - often absent in immunosuppressed patients. A more recent technique based on detecting the circulating galactomannan antigen appears to be promising; but further studies are needed before the test becomes available for general use [49–52].

Similarly, a polymerase chain reaction to detect aspergillus species deoxyribonucleic acid (DNA) in bronchoalveolar lavage fluid is under study [53].

Thus, in most cases of immunosuppressed patients, serological monitoring is insensitive. On the other hand, in the post lung transplant patients, a situation similar to aspergilloma patients exists [54]. TOMEE *et al.* [55] studied four patients with postlung transplant *A. fumigatus* infection. Increasing specific IgG antibody levels paralleled the cytological or microbiological identification and the lung function impairment. Successful treatment resulted in a decrease in the antibody level. These observations require confirmation.

Radiographic findings in patients with invasive aspergillosis include solitary and multiple nodules. CT changes are helpful in detecting early changes that are not present on chest radiographs. Bronchoscopy and/or high resolution CT were performed in a study of 33 patients [34]. The sensitivity of bronchoalveolar lavage (BAL) fluid and washings were 33% and 50% respectively. CT signs of fungal infection were found in 16 (84%) of 19 episodes. More frequent use of bronchoscopy and CT leads to earlier institution of antifungal therapy, resulting in improved survival [56]. Fiberoptic bronchoscopy and bronchial biopsy are safe procedures if performed in patients with normal coagulation studies and platelet counts  $>50,000\text{-mm}^{-3}$ . When fiberoptic bronchial biopsy is negative, and the clinical



suspicion of invasive aspergillosis remains, an open lung biopsy should be performed.

The treatment for invasive aspergillosis is amphotericin-B. It is begun empirically in neutropenic patients. The overall response rate to amphotericin-B is 55%. However, in patients with bone marrow transplants, mortality rates as high as 94% have been reported [57]. Early treatment with high doses of amphotericin-B achieves a good response. BURCH *et al.* [44] empirically treated 15 cases of invasive pulmonary aspergillosis associated with acute leukaemia, 13 responded. In another study, 85% of those treated within 24 h of the onset of aspergillosis in patients with chemotherapy-induced neutropenia survived as compared with 52% of those who were treated after 24 h [58]. A low or inadequate dose of amphotericin-B does not effectively control the disease [44, 59–61]. Amphotericin-B liposomal complex should be given to those patients who cannot tolerate high-dose amphotericin-B because of renal toxicity [62]. The combination of amphotericin-B and flucytosine is not only synergistic but allows the dosage of amphotericin to be reduced to less toxic levels [63]. Ketoconazole has a significant activity against *Aspergillus* spp. *in vitro*, but it is difficult to obtain therapeutic inhibitory serum levels of the drug in patients [64]. The combination of amphotericin-B and rifampin has been used in those cases where primary resistance to flucytosine was encountered.

Itraconazole, a new oral antifungal agent, is active against the *Aspergillus* spp. [64]. The drug must be given with food. DENNING *et al.* [66] found itraconazole to be as effective as amphotericin-B, however, its role needs to be further studied. Itraconazole is also used empirically as a prophylaxis against aspergillus in high-risk patients with neutropenia or on long-term corticosteroid therapy [67–71].

In the management of a dreaded disease like invasive aspergillosis, prevention is the best therapy. The immunosuppressed host should be carefully monitored by: 1) frequent sputum examinations; 2) weekly nasal cultures; 3) serial chest radiograph films; 4) frequent serological measurements of aspergillus antibody and antigens; and 5) bronchoscopic examination and BAL.

### Chronic necrotizing pulmonary aspergillosis

Chronic necrotizing pulmonary aspergillosis (CNPA) is an indolent, cavitating lesion that occurs due to localized invasion of the lung tissue by aspergillus. In a review of 22 cases, BINDER *et al.* [72] found these patients to usually be middle-aged with evidence of generalized immunosuppression in the form of diabetes mellitus, malnutrition, corticosteroid or radiation therapy, and collagen vascular diseases. Fever, cough, and expectoration was always present. Chest radiographs showed a patchy infiltrate with a cavity. In many cases such a lesion can be mistakenly diagnosed as tuberculosis, histoplasmosis, coccidioidomycosis, anaerobic pneumonia, or vasculitis. Diagnosis is established by tissue evidence of invasive aspergillus. Serum precipitating (IgG) antibodies are present. The treatment includes antifungal agents and surgical resection of the lesion [72].

### Saprophytic colonization

#### *Aspergilloma*

Aspergilloma or a fungus ball is the most common form of the clinical syndromes caused by aspergillus, but there is little epidemiological data to support the assertion. All species of aspergillus including *A. fumigatus* and *A. niger* may colonize old stable pulmonary cavities, bullae or cysts. Patients who develop aspergillomas are usually nonatopic and have chronic underlying lung diseases that include advanced (Stage IV) sarcoidosis, fibrocystic tuberculosis, histoplasmosis, bronchiectasis, interstitial fibrosis or emphysema. The most common primary lung disease that predisposes to aspergilloma is an open healed tuberculous cavity. The interval between the diagnosis of pulmonary tuberculosis and development of the aspergilloma may vary from 1 to 30 yrs. Although aspergillomas, when discovered, may be asymptomatic and benign in appearance, they have the potential to cause life-threatening haemoptysis. Approximately 75–90% of the patients have haemoptysis; most have minor, insignificant bleeding but approximately one quarter of these patients may experience massive haemoptysis. The cause of haemoptysis is erosion of a bronchial artery. Neither the size of the lesion nor associated clinical features predict the development of life-threatening haemoptysis.

The diagnosis of aspergilloma is based on the characteristic radiographic findings in the chest of a moveable, homogeneous opacity inside a cavity. The opacity is usually surrounded by a "halo" or an air-crescent. The necrotic mass of matted hyphae, inflammatory cells, fibrin, and blood which usually lies free within the cavity is aptly termed a fungus ball. Although CT scanning dramatically outlines the crescentic radiolucency surrounding the mass, chest radiographs including posteroanterior and decubitus films are all that are required to establish the diagnosis. The aspergillomas are mostly located in the upper lobes; however, other parts of the lung may also be involved. The lesion may be single or multiple and may show calcification. Adjacent pleura are often thickened; this thickening may precede the development of the fungus ball by months to years (figs. 5 and 6).

Serum precipitating antibodies (IgG) are almost always present, initially in high concentrations, but become weaker, and even negative, if the fungus ball is taken out. Spontaneous resolution of an aspergilloma may occur [73].

Treatment of aspergillomas remains frustrating [74, 75]. Medical therapy has a limited role. Except in rare instances, antifungal drugs (whether given orally, intravenously, by inhalation, or by direct instillation into the cavity) have not been consistently effective [76–78]. Amphotericin-B is highly toxic, itraconazole has not been studied in controlled trials [79]. Furthermore, the incidence of recurrence after intracavitary instillation of antifungal agents is high. These agents can be instilled either percutaneously or *via* an intrabronchial catheter. Antifungal agents so far have included amphotericin-B, miconazole, N-acetylcysteine, natamycin, nystatin, sodium iodide, and aminocaproic acid [79].

RUMBAK and KOHLER [80] treated 11 patients with 12 episodes of massive haemoptysis (>600 mL blood·24 h<sup>-1</sup>). These patients had advanced lung disease and were

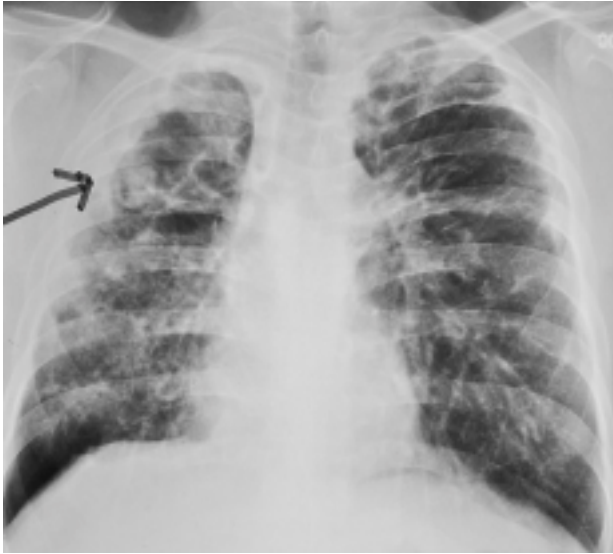


Fig. 5. – Posteroanterior view of the chest showing a typical fungus ball (arrow) in the right upper lobe in a patient with advanced sarcoidosis. Note the adjacent pleural thickening commonly seen in patients with fungus ball.

unsuitable for pulmonary resection (FEV<sub>1</sub> <50% predicted). Haemoptysis stopped within 72 h of intracavitary instillation of potassium or sodium iodide with or without amphotericin-B (fig. 6). The treatment did not result in major side-effects. Although bleeding stopped in all patients, resolution of chest radiograph occurred in only three patients. No patients died of haemoptysis, but five of nine patients for whom follow-up was available died of respiratory failure within 4 yrs. In another study YAMADA *et al.* [81] used amphotericin-B or flucanazole for intracavitary instillation in 12 patients, four of whom had significant haemoptysis. Radiographic resolution occurred in only two patients, whereas, clinical improvement was evident in 10 patients. These are not prospective, double-blind studies. At the present time data are few and do not strongly recommend intracavitary instillation of antifungal agents as a routine therapeutic procedure for every patient with aspergilloma [82]. Furthermore, intracavitary instillation is not a simple procedure. A trained radiologist or a pulmonary specialist is required to perform the procedure.

Bronchial artery embolization should be considered in a patient who is not an ideal candidate for surgery and has not responded to systemic or intracavitary antifungal drugs [83]. The procedure is often unsatisfactory because of the difficulty in identifying the bleeding vessel. Furthermore, even, if an attempt to embolize the vessel succeeds, the bleeding may not stop because of the massive collateral circulation seen so frequently in advanced disease. In one of my patients with advanced sarcoidosis, four attempts at embolization failed to stop haemoptysis. The patient finally died of respiratory failure due to extensive fibrosis. Furthermore, it is not possible to eliminate the fungus ball by embolization.

Surgery offers many clear benefits: the aspergilloma is removed; haemoptysis is controlled; clinical symptoms are abated; quality of life is improved; and finally, life is prolonged. However, surgical resection is a high-risk procedure, particularly in patients with chronic, advanc-

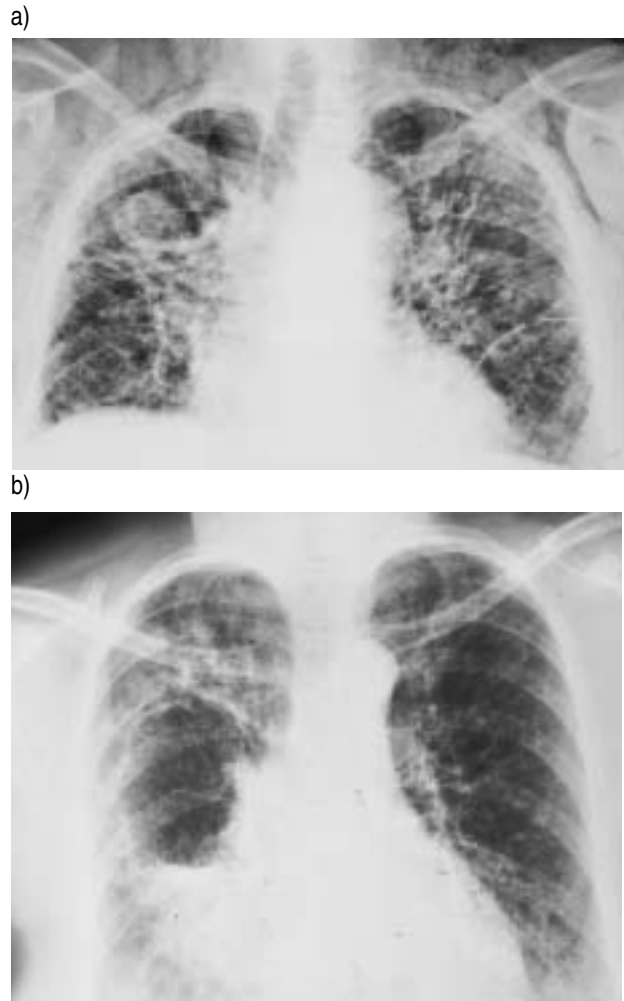


Fig. 6. – Aspergilloma: a) posteroanterior view of the chest showing an egg-shaped fungus ball in the right upper lobe; and b) intracavitary instillation of amphotericin-B caused dissolution of the fungus ball.

ed fibrosis, thickened pleura with obliteration of the pleural

space, and marked mediastinal adhesions. In such patients mortality may be >25% and the incidence of complications related to haemorrhage, bronchopleural fistula, and empyema approaches 60% [76, 84].

Recently, CHEN *et al.* [76] have reported their experience with 67 patients with aspergilloma treated surgically over a 27-yr period. This is the largest series of surgical resection for aspergilloma. Haemoptysis was present in 61 (91.0%) patients. Tuberculosis was the most common pre-existing illness. Systemic antifungal therapy and intra-arterial embolization were unsuccessful in controlling symptoms and eradicating the disease. Most patients (61.4%) underwent lobectomy. There was one death from pneumonia following surgery. Fifteen postoperative complications in 12 patients included: empyema (7); massive bleeding (3); bronchopleural fistula (2); wound infection (2); and Horner's syndrome (1). Postoperatively, most of the patients were symptom free. These results clearly show that with advanced planning, appropriate pre-operative management, and judicious surgical technique, surgery is the preferred treatment for pulmonary aspergilloma. The authors recommend early surgery in all patients with good lung function



before life-threatening haemoptysis or severe pulmonary damage related to the primary disease increases the mortality and morbidity of the operation.

Similar conclusions have been reached by EL OAKLEY *et al.* [85] from the Royal Brompton Hospital, London. They categorized their 27 consecutive patients referred for surgical assessment, over a period of 14 yrs, into four groups: Class I (n=1), fit individual with mild or no symptoms; Class II (n=17), fit individuals with severe symptoms; Class III (n=1), unfit individuals with no symptoms; and Class IV (n=8), unfit individuals with severe symptoms. Lung resection was performed in all 17 patients with Class II disease, comprising segmentectomy in five patients, lobectomy and segmentectomy in seven, and a complete pneumonectomy in five patients. Cavernostomy was performed in seven patients with Class IV disease. There were no operative deaths in patients treated by resection, but two of those who underwent cavernostomy died in the early postoperative period. Surgery was complicated by prolonged air leaks and empyema. Their results clearly stress the importance of good surgical technique to reduce both air leaks and postoperative haemorrhage, and the use thoracoplasty to obliterate the residual pleural space.

Currently, surgical resection is the only logical therapy for aspergilloma. Resection should be planned and performed early before the appearance of a massive fatal haemoptysis or progression of the primary pulmonary disease to such an advanced fibrotic stage making the patient unfit for surgery [86].

#### *Pulmonary mycotoxicosis*

This is primarily a disease of agricultural animals. Inhalation of an overwhelming amount of aspergillus spores may cause chemical pneumonitis. The clinical picture is acute in onset and characterized by fever, dyspnoea, chest tightness and cyanosis. Chest radiographs show diffuse ground glass haziness and nodular infiltrate. The histological picture consists of a mainly cellular infiltrate of polymorphs, lymphocytes, and plasma cells. The response to corticosteroids is excellent.

#### References

- Storm van Leeuwen W. Diagnosis and treatment of allergic diseases. *Neurotherapie* 1922; 6: 1–18.
- Charpin J, Boutin C, Aubert J, Meyer L. Le rôle d'Aspergillus en pathologie bronchopulmonaire. *Lyon Med* 1967; 3: 7–9.
- Pepys J, Riddell R, Citron K, Clayton Y, Short E. Clinical and immunologic significance of *Aspergillus fumigatus* in the sputum. *Am Rev Respir Dis* 1959; 80: 167–172.
- Pennington J. Aspergillus lung disease. *Med Clin North Am* 1980; 64: 475–490.
- Reynolds H. Hypersensitivity pneumonitis. *Clin Chest Med* 1983; 3: 503–515.
- Young R, Bennett J, Vogel C. Aspergillosis: The spectrum of the disease in 98 patients medicine. *Medicine* 1970; 49: 147–173.
- Hinson KFW, Moon AJ, Plummer NS. Bronchopulmonary aspergillosis: a review and report of eight new cases. *Thorax* 1952; 7: 317–333.
- Campbell J, Clayton Y. Bronchopulmonary aspergillosis: a correlation of the clinical and laboratory findings in 272 patients investigated for bronchopulmonary aspergillosis. *Am Rev Respir Dis* 1964; 89: 186–196.
- Frankland A, Davis R. Allergie aux spores de moisissures en Angleterre. *Poumon et Coeur* 1965; 21: 1–11.
- Henderson AH. Allergic Aspergillosis. Review of 32 cases. *Thorax* 1968; 23: 501.
- Simon G. Bronchopulmonary aspergillosis in asthma. Radiological aspects. In: Proceedings of the Fourth International symposium, Vol. 1. Bern, Stuttgart, Vienna, Han Huber, 1971.
- Edge J, Stansfield D, Fletcher D. Pulmonary aspergillosis in an unselected hospital population. *Chest* 1971; 59: 407–413.
- Shaw R, Paulson D, Kee J. Mucoïd impaction of the bronchi. Study of thirty-six cases. *Am Rev Tuberc* 1957; 76: 970.
- Slavin R, Stanczyk D, Lonigro A, Broun G. Allergic bronchopulmonary aspergillosis: a North American rarity. *Am J Med* 1969; 47: 306–308.
- Patterson R, Greenberger P, Halwing J. Allergic bronchopulmonary aspergillosis. Natural history and classification of early disease by serologic and radiologic studies. *Arch Intern Med* 1986; 146: 916–918.
- Greenberger P, Patterson R. Diagnosis and management of allergic bronchopulmonary aspergillosis. *Ann Allergy* 1986; 56: 444–448.
- Lee T, Greenberger P, Patterson R. State V (fibrotic) bronchopulmonary aspergillosis: a review of 17 cases followed from diagnosis. *Arch Intern Med* 1987; 147: 319–323.
- Acquino S, Kee S, Warnock M. Pulmonary aspergillosis: imaging findings with pathologic correlation. *Am J Roentgenol* 1994; 163: 811–815.
- Bromley IM, Donaldson K. Binding of *Aspergillus fumigatus* spores to lung epithelial cells and basement membrane proteins: relevance to the asthmatic lung. *Thorax* 1996; 51: 1203–1209.
- McCarthy DS, Pepys J. Allergic bronchopulmonary aspergillosis: clinical immunology. *Clin Allergy* 1971; 1: 261–286.
- Ricketti J, Greenberger P, Patterson R. Immediate-type reactions in patients with allergic bronchopulmonary aspergillosis. *J Allergy Clin Immunol* 1971; 71: 541–545.
- McCarthy D, Simon G, Hargreave F. The radiological appearances in allergic bronchopulmonary aspergillosis. *Clin Radiol* 1970; 21: 366–375.
- Aslam P, Eastridge C, Hughs F. Aspergillosis of the lung. An eighteen year experience. *Chest* 1971; 59: 28–32.
- Wang J, Patterson R, Roberts M, *et al.* The management of allergic bronchopulmonary aspergillosis. *Am Rev Respir Dis* 1979; 120: 87–92.
- Nikoudo Y, Nagata N, Yamamoto T, Yoshii C, Ohmori H, Kido M. A case of allergic bronchopulmonary aspergillosis successfully treated with itraconazole. *Respir Med* 1998; 92: 118–124.
- De Beule K, De Doncker P, Cauwenbergh G. The treatment of aspergillosis and aspergilloma with itraconazole. Clinical results of an open international study. *Mycoses* 1988; 31: 476–485.
- Denning DW, Van Wye JE, Lewiston NJ, Stevens DA. Adjunctive therapy of allergic bronchopulmonary aspergillosis with itraconazole. *Chest* 1991; 100: 813–819.
- Pasteur V-R, Giroud P. Spromycose des pelleteurs de grains. *Bull Mem Soc Med Hop Paris* 1928; 52: 1632–

- 1636.
29. Riddle R, Channell S, Blyth W, *et al.* Allergic alveolitis in a maltworker. *Thorax* 1968; 23: 271–278.
  30. Rhudy J, Burrell R, Morgan W. Yet another cause of allergic alveolitis. *Scand J Respir Dis* 1971; 52: 177–181.
  31. Liebow A. Pulmonary angitis and granulomatosis. *Am Rev Respir Dis* 1973; 108: 1–18.
  32. Katzenstein A, Liebow A, Friedman P. Bronchocentric granulomatosis, mucoid impaction and hypersensitivity reaction to fungi. *Am Rev Respir Dis* 1975; 111: 497–508.
  33. Brooker A, Sharma O. Bronchocentric granulomatosis and adult respiratory distress syndrome. *Br J Dis Chest* 1982; 76: 189–193.
  34. Von Eiff M, Roos N, Schulten R. Pulmonary aspergillosis: early diagnosis improves survival. *Respiration* 1995; 62: 341–347.
  35. Addrizzio-Harris D, Harkim T, McGuinness G, Nadich D, Rom W. Pulmonary aspergilloma and AIDS: a comparison of HIV-infected and HIV-negative individuals. *Chest* 1997; 111: 612–618.
  36. Denning D, Follansbee S, Scolaro M, *et al.* Pulmonary aspergillosis in the acquired immunodeficiency syndrome. *N Engl J Med* 1991; 324: 654–662.
  37. Miller W, Sais G, Frank I, *et al.* Pulmonary aspergillosis in patients with AIDS: clinical and radiographic correlations. *Chest* 1994; 105: 37–44.
  38. Waldorf A. Pulmonary defense mechanisms against opportunistic fungal infections. *Immunol Ser* 1989; 43: 243–250.
  39. Karam G, Griffin F. Invasive pulmonary aspergillosis in nonimmunocompromised, nonneutropenic hosts. *Rev Infect Dis* 1986; 8: 357–363.
  40. Rodenhuis S, Beaumont F, Kaufmann H, *et al.* Invasive pulmonary aspergillosis in a nonimmunosuppressed patient: successful management with systemic amphotericin and flucytosine and inhaled amphotericin. *Thorax* 1984; 39: 78–79.
  41. Kuhlman J, Fishman E, Siegelman S. Invasive pulmonary aspergillosis in acute leukemia characteristic findings of CT, the CT halo sign, and the role of CT in early diagnosis. *Radiology* 1985; 157: 611–614.
  42. Albelda S, Talbot G, Gerson S, *et al.* Role of fiberoptic bronchoscopy in the diagnosis of invasive pulmonary aspergillosis in patients with leukemia. *Am J Med* 1984; 76: 1027–1034.
  43. Fisher D, Armstrong D, Yu B, Gold J. Invasive aspergillosis: progress in early diagnosis and treatment. *Am J Med* 1981; 71: 571–577.
  44. Burch P, Karp J, Merz W, *et al.* Favorable outcome of invasive aspergillosis in patients with leukemia. *J Clin Oncol* 1987; 5: 1985–1993.
  45. Jamadar D, Kazerooni E, Daly B. Pulmonary zygomycosis: CT appearance. *J Com Asst Tomog* 1995; 19: 733–738.
  46. Harari S, Schiraldi G, Juli E, *et al.* Relapsing aspergillus bronchitis in a double lung transplant patient, successfully treated with a new oral antimycotic agent. *Chest* 1997; 111: 835–836.
  47. Mylonakis E, Rich J, Skolnik R, De Orchis D, Flanigan T. Invasive aspergillus sinusitis in patients with human immunodeficiency virus infection. Report of 2 cases and review. *Medicine* 1997; 76: 249–255.
  48. Harvath JA, Dunner S. The use of respiratory tract cultures in the diagnosis of invasive pulmonary aspergillosis. *Am J Med* 1996; 100: 171–175.
  49. Weiner M, Talbot G, Gerson S, *et al.* Antigen detection in the diagnosis of invasive pulmonary aspergillosis: Utility in controlled, blinded trials. *Ann Intern Med* 1983; 99: 777–782.
  50. Rogers T, Haynes K, Barnes R. Value of antigen detection in prediction of invasive pulmonary aspergillosis. *Lancet* 1990; 336: 1210–1213.
  51. Talbot G, Weiner M, Gerson S, *et al.* Serodiagnosis of invasive aspergillosis in patients with hematologic malignancy: validation of the *Aspergillus fumigatus* antigen radioimmunoassay. *J Infect Dis* 1987; 155: 12–27.
  52. Haynes K, Rogers T. Retrospective evaluation of a latex agglutination test for diagnosis of invasive aspergillosis in immunocompromised patients. *Eur Clin Microbiol Infect Dis* 1994; 13: 670–674.
  53. Bretagne S, Costa J, Marmorat-Khoung A, *et al.* Detection of aspergillus species of DNA in bronchoalveolar lavage samples by competitive PCR. *J Clin Microbiol* 1995; 33: 1164–1168.
  54. Westney GE, Kesten S, Dehoyos A. Aspergillus infection in single and double lung transplants. *Transpl* 1996; 61: 915–919.
  55. Tomee JFC, Mannes GPM, van der By W. Serodiagnosis and monitoring of aspergillus infections after lung transplantation. *Ann Intern Med* 1996; 125: 197–201.
  56. Levy H, Horak D, Tegtmeir B, *et al.* The value of bronchoalveolar lavage and bronchial washings in the diagnosis of invasive pulmonary aspergillosis. *Respir Med* 1992; 86: 243–248.
  57. Denning D, Stevens D. Antifungal and surgical treatment of invasive aspergillosis: review of 2121 published cases. *Rev Infect Dis* 1990; 12: 1147–1201.
  58. Karp J, Merz W, Charache P. Response to empiric amphotericin B during antileukemic therapy induced granulocytopenia. *Rev Infect Dis* 1991; 13: 592–599.
  59. Wheat LJ. Fungal infections in immunocompromised host. In: Rubin RH, Young LS, eds. *Clinical Approach to Infection in the Compromised Host*. 3rd ed. New York, Plenum, 1994; p. 211–237.
  60. Palmer L, Greenberg H, Schiff M. Corticosteroid treatment as a risk factor for invasive aspergillosis in patients with lung disease. *Thorax* 1991; 46: 15–20.
  61. Walsh T, Lee J, Lecciones J, *et al.* Empiric therapy with amphotericin B in febrile granulocytopenic patients. *Rev Infect Dis* 1991; 13: 496–503.
  62. Ng T, Denning D. Liposomal amphotericin B (AmBisome) therapy in invasive fungal infections. *Arch Intern Med* 1995; 155: 1093–1098.
  63. Codish S, Tobias J, Hannigan M. Combined amphotericin-B - flucytosine therapy in aspergillus pneumonia. *J Am Med Assoc* 1979; 241: 2418–2419.
  64. Jennings T, Hardin T. Treatment of aspergillosis with itraconazole. *Ann Pharmacother* 1993; 27: 1206–1211.
  65. Klein N, Cunha B. New antifungal drugs for pulmonary mycosis. *Chest* 1996; 110: 525–532.
  66. Denning D, Lee J, Hostetler J, *et al.* Mycoses Study Group Multicenter trial of oral itraconazole therapy for invasive aspergillosis. *Am J Med* 1994; 97: 135–144.
  67. Behre GF, Schwartz S, Lenz K, *et al.* Aerosol amphotericin-B inhalations for prevention of invasive pulmonary aspergillosis in neutropenic cancer patients. *Ann Hematol* 1995; 71: 287–291.
  68. Dubois J, Bartter T, Gryn J, Pratter M. The physiologic effects of inhaled amphotericin-B. *Chest* 1995; 108: 750–753.
  69. Denning W. Therapeutic outcome in invasive aspergillosis. *Clin Infect Dis* 1996; 23: 608–615.
  70. Keating MR, Guerrero MA, Daly RC. Transmission of invasive aspergillosis from a subclinically infected donor to

- three different organ transplant recipients. *Chest* 1996; 109: 1119–1124.
71. Kuo PH, Lee LN, Yang PC. Aspergillosis laryngotracheo-bronchitis presenting as stridor in a patient with peripheral T-cell lymphoma. *Thorax* 1996; 51: 869–870.
  72. Binder R, Faling J, Pugatch R, *et al.* Chronic necrotizing pulmonary aspergillosis: a discrete clinical entity. *Medicine* 1982; 61: 109–124.
  73. Hammerman K, Christianson C, Huntington I, Hurst G, Zelman M, Tosh P. Spontaneous lysis of aspergillomata. *Chest* 1973; 64: 693–699.
  74. Jewkes J, Kay P, Paneth M, Citron K. Pulmonary aspergilloma: analysis of prognosis in relation to hemoptysis and survey of treatment. *Thorax* 1983; 38: 572–578.
  75. Editorial. Surgical management of pulmonary aspergilloma. *Thorax* 1997; 52: 753–754.
  76. Chen J, Chang Y, Luh S, Lee J, Lee Y. Surgical treatment for pulmonary aspergilloma: a 28 year experience. *Thorax* 1997; 52: 810–813.
  77. Editorial. Quandary about treatment of aspergillomas persists. *Lancet* 1996; 347: 1640.
  78. Massard G, Roeslin N, Wihlm J-M, Dumont P, Witz J-P, Morand G. Pleuro-pulmonary aspergilloma: clinical spectrum and results of surgical treatment. *Ann Thorac Surg* 1992; 54: 1159–1164.
  79. Henderson A, Pearson J. Treatment of bronchopulmonary aspergillosis with observation on the use of natamycin. *Thorax* 1968; 23: 519–523.
  80. Rumbak M, Kohler G, Eastrige C, Winer-Muram H, Gravant M. Topical treatment of life-threatening hemoptysis from aspergilloma. *Thorax* 1996; 51: 253–255.
  81. Yamada H, Kohno S, Koga H, Maesaki S, Kaku M. Topical treatment of pulmonary aspergilloma by antifungals: Relation between duration of the disease and efficacy of therapy. *Chest* 1993; 103: 1421–1425.
  82. Diot P, Rivoire B, Le Pape A, *et al.* Deposition of amphotericin-B aerosols in pulmonary aspergilloma. *Eur Respir J* 1995; 8: 1263–1268.
  83. Uflacker R, Kaemmerer A, Neves C, Picon P. Management of massive hemoptysis by bronchial artery embolization. *Radiology* 1983; 146: 627–634.
  84. Daly R, Pairolero P, Piehler J, Trastek V, Payne W, Bernatz P. Pulmonary aspergilloma. *Ann Thorac Surg* 1986; 92: 981–988.
  85. El Oakley R, Petreri M, Goldstrai P. Indications and outcome of surgery for pulmonary aspergilloma. *Thorax* 1997; 52: 813–815.
  86. Kilman J, Ahn C, Andrews N, Klassen K. Surgery for pulmonary aspergillosis. *J Thorac Cardiovasc Surg* 1969; 57: 642–647.