

## CASE REPORT

# Late recurrence of Wegener's granulomatosis presenting as solitary upper lobe pulmonary mass

T.S. van der Werf\*, C.A. Stegeman\*\*, K.J. Meuzelaar+, W. Timens++

*Late recurrence of Wegener's granulomatosis presenting as solitary upper lobe pulmonary mass. T.S. van der Werf, C.A. Stegeman, K.J. Meuzelaar, W. Timens. ©ERS Journals Ltd 1994.*

**ABSTRACT:** Recurrent Wegener's granulomatosis (WG) was diagnosed in a 40 year old man presenting with a solitary mass in the right lung apex and with possible lymph node enlargement in the anterior mediastinum, resembling malignancy.

Eight years previously, a first episode of WG involving the upper airways and kidneys, but not the lungs, had been successfully treated with prednisolone and cyclophosphamide, which could be stopped after 2 yrs. The antineutrophil cytoplasmic antibody titres (anti-protease 3), which had been very high during the first disease episode, failed to predict the recurrence.

*Eur Respir J., 1994, 7, 1365–1368.*

Depts of \*Pulmonary Diseases, Intensive and Respiratory Care, \*\*Nephrology, +Thoracic Surgery, and ++Pathology, Groningen University Hospital, The Netherlands.

Correspondence: T.S. van der Werf  
Depts of Pulmonary Diseases, Intensive and Respiratory Care  
Groningen University Hospital  
PO Box 30.001  
9700 RB Groningen  
The Netherlands

Received: October 14 1993

Accepted after revision February 11 1994

Wegener's granulomatosis (WG) is a systemic vasculitic syndrome, which affects mainly the upper and lower airways. Death used to result from renal failure, before effective therapy with cyclophosphamide and prednisolone became available. Males are affected slightly more often than females, and the peak incidence in most reported series of this condition is in the fifth decade. The usual radiological presentation of lung involvement is a multinodular pattern, predominantly in the lower fields; diffuse alveolar haemorrhage, pleural involvement, and endobronchial presentations with atelectasis are less common [1–3]. Anti-neutrophil cytoplasmic antibodies (ANCA) are detected in almost all patients with active WG [4, 5], although lower rates of cytoplasmic-ANCA (c-ANCA) positivity have been reported with limited disease activity [6, 7]. After initial effective therapy, relapses generally occur during the tapering of immunosuppressive therapy, usually at a site similar to the first presentation [8]. Recurrences are usually heralded by a rise in ANCA titres [7, 9]. We report a case of recurrent WG with several unusual features.

### Case report

A 40 year old man complained of a dry cough, night sweats and slight malaise of 2 weeks duration. He had been a regular cigarette smoker since he was aged 16 yrs, with 25 pack-years. His medical history was remarkable in that 8 yrs earlier, he was diagnosed as having WG with renal failure and perforation of the nasal septum, without involvement of the lower respiratory tract. At that time, he first developed nasal stuffiness and arthralgias, later on complicated by severe renal failure,

within a period of 4 weeks. The nadir creatinine clearance was 10 ml·min<sup>-1</sup>. There was eosinophilia in the peripheral blood of 900–1,000 cells·mm<sup>-3</sup>, and c-ANCA were present in high titres. Endonasal biopsies revealed necrotizing vasculitis with eosinophilic infiltration and granulomas, and a renal biopsy showed focal, local intra- and extracapillary proliferative glomerulonephritis. These findings were consistent with WG, and immunosuppressive treatment with cyclophosphamide and prednisolone was initiated, with rapid and complete restoration of his renal function. The patient sustained several complications, including a perforation of the nasal septum, deep venous thrombosis, which was successfully treated with coumarin, and a transient steroid-induced diabetes mellitus, but eventually, he had a full recovery. His immunosuppressive treatment could gradually be tapered and cyclophosphamide was stopped 2 yrs after it was started. c-ANCA titres further classified by enzyme-linked immunosorbent assay (ELISA) as antiproteinase 3 had dropped and they remained low, varying from 1:16 to 1:64. The patient was in good health, apart from periods with slight nasal stuffiness, with symptoms of nasal discharge which grew *S. aureus*, for which courses of antibiotic treatment were occasionally given, with good results.

On examination, he was not dyspnoeic and appeared well. On percussion, a slight dullness of the medial part of the right clavicle was noticed. Otherwise, the physical examination was unremarkable. Laboratory tests showed a recent-onset slightly elevated C-reactive protein (CRP). Haemoglobin level, total white blood cells and differential count were normal, without blood eosinophilia or any other abnormalities. Renal function was normal, without proteinuria or haematuria. c-ANCA

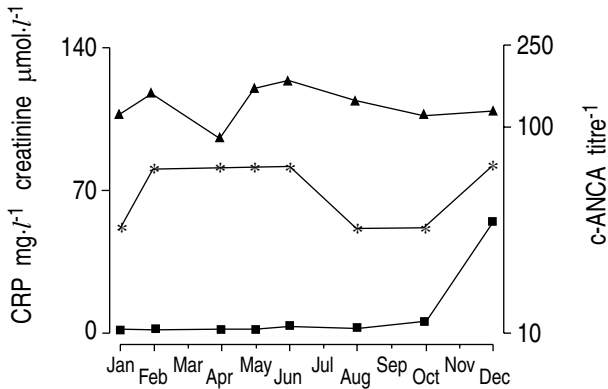


Fig. 1. — Serum-creatinine (—▲—), C-reactive protein (CRP) (—■—), and cytoplasmic-anti-neutrophil cytoplasmic antibodies (c-ANCA) (—\*—) during the last year before presentation with pulmonary mass.

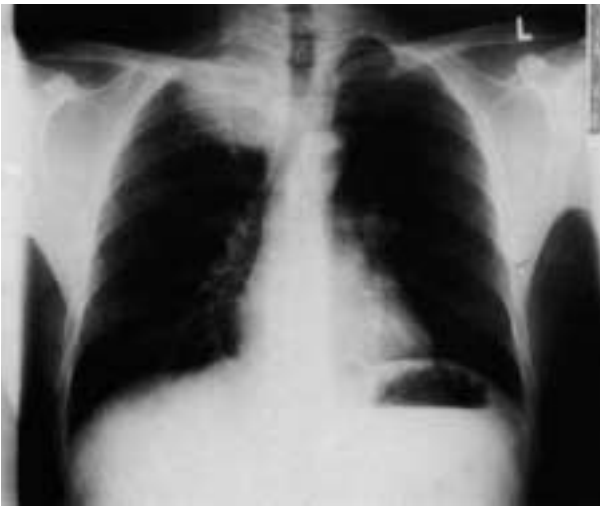

Fig. 2. — Posteroanterior chest radiograph showing a dense right apical mass.

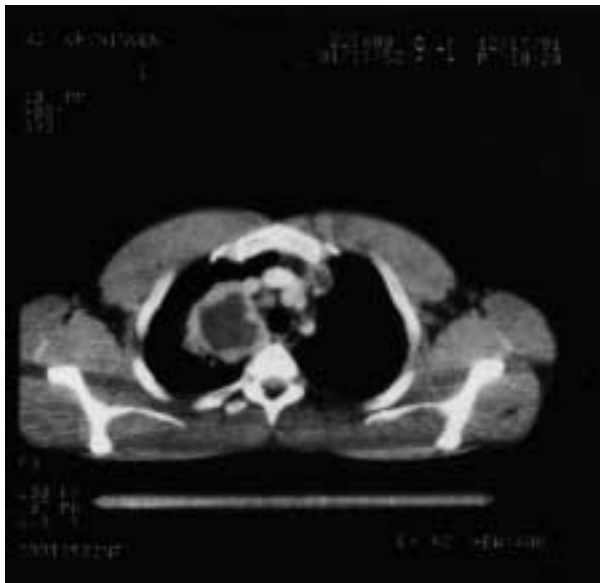


Fig. 3. — Computed chest tomography showing a right apical pulmonary mass with central necrosis, and two masses in the anterior mediastinum, one adjacent to the aortic arch and one in the pretracheal area.

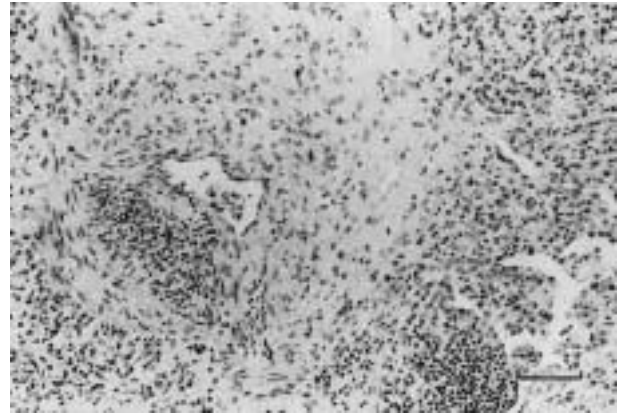


Fig. 4. — Large magnification ( $\times 140$ ; bar=100 µm) of the open lung biopsy specimen showing an inflammatory infiltrate with eosinophils near arterioles without necrosis (centre-left). Note residual lung tissue at left side of figure with interstitial inflammation and fibrosis.

levels were stable in the range similar to that of recent years (fig. 1). The chest radiograph showed a dense mass in the apex of the right upper lobe, which was not present on the film made 2 yrs previously (fig. 2). A computed tomography scan revealed central necrosis in this lesion, and two smaller densities were seen in the anterior mediastinum, which were believed to represent lymph node involvement (fig. 3). Lung volumes were in the normal range.

Fibreoptic bronchoscopy was performed, with bronchial washings, brushings and transbronchial biopsies. No bacilli, including acid fast bacilli or fungal hyphae, were detected and the cultures remained negative. Cytology of brushings and washings, and pathological examination of transbronchial biopsies did not reveal malignancy, infection, or vasculitis; only slight, aspecific inflammation was noticed, and these results were regarded non-diagnostic. A percutaneous transthoracic biopsy procedure with a trucut needle failed, as the mass was of such a very firm consistency that the needle could not penetrate. A cervical mediastinoscopy was undertaken, but failed to yield a diagnosis. Primary malignancy, *e.g.* squamous cell carcinoma, was suspected because of the appearance of central necrosis within the lesion on CT, in the absence of signs or symptoms suggesting active WG.

Subsequently, an open lung biopsy through a right lateral thoracotomy was performed.

At thoracotomy, a firm mass adherent to the trachea and the mediastinum was found at the apex of the right upper lobe. A preoperative frozen section procedure did not reveal malignancy or vasculitis. On definitive histological examination, after fixation and paraffin embedding of the tissue, dense extracellular scar collagenous tissue was observed, that had apparently been the cause of the firm consistency of the mass (fig. 4). In the central part of the process, there was necrosis with polymorphonuclear cell inflammation and with extensive eosinophilic infiltration, with infiltration in a vascular wall, but without necrosis, giant cells or granulomas.

Two days after thoracotomy, the c-ANCA level in a blood

specimen, taken preoperatively, appeared to have risen to 1:256. CRP had also increased, and a diagnosis of WG pulmonary reactivation was made. Immunosuppressive treatment was reinstated, and the response was favourable, the chest lesion became smaller and cavitated.

### Comment

The usual radiological pattern of WG in the lung is the presence of multiple round lesions, widely distributed over both lungs, although many other patterns, including solitary lesions, have been described [1–3, 10]. Mediastinal lymph node involvement is rare, however; the patient described by GUTIÉRREZ-RAVÉ and AYERZA [11] presented with diffuse pulmonary haemorrhage, with wide-spread involvement of the digestive tract, and lymph node involvement but no pulmonary nodules. Unlike other granulomatous disorders, such as sarcoidosis and postprimary tuberculosis, a solitary lesion in the upper lobes is not suggestive for WG [12, 13]. Although cases of WG presenting with a solitary pulmonary nodule have been described [3, 14], a solitary nodule in the upper lobe apex is not common.

The absence of more characteristic histopathology in the presence of predominantly eosinophilic inflammation and the abundance of scar tissue in WG have been recognized infrequently [15–17]. YOSHIKAWA and WATANABE [16] reported five cases of "fibrous scar type" WG in a series of 22 autopsies, and YOUSEM and LOMBARD [17] reported four cases of open lung biopsies with an unusual histological variant of WG, with extensive necrosis and eosinophilic inflammation.

KALLENBERG *et al.* [18] have recently reviewed the literature on ANCA in WG. It has been established that c-ANCA has not only proven value for the diagnosis of WG, but also for monitoring of disease activity: a rise in c-ANCA level generally precedes the clinical relapse, even with only limited disease activity [19]. In our patient, the rise in c-ANCA occurred only after surgery had been carried out, and failed to predict the clinical relapse. In limited WG, c-ANCA is presented in 67–86% of reported series (reviewed in [18]).

Finally, the patient relapsed at a site which was not involved during the first disease episode, whilst the sites which were involved during the first episode were unaffected. Relapses are far more common during the tapering of immunosuppressive therapy than late recurrences, and when patients relapse, they usually do so at the site of first disease activity [8, 10]. Whether this attenuated course was to some extent an incomplete response to intermittent antimicrobial treatment is speculative, but treatment with cotrimoxazole has been reported to be effective in limited WG, *i.e.* when only the lungs are involved [20–22].

This patient underwent several invasive diagnostic procedures, with a substantial risk for morbidity and even mortality, because a differential diagnosis of malignancy was considered. Would a less invasive procedure, such as bronchoalveolar lavage (BAL) study with determination of ANCA in the BAL fluid, have obviated the

need for an explorative thoracotomy to reach diagnostic certainty? Recent reports suggest that ANCA in WG patients are produced in the respiratory tract [23, 24], but the possible role of BAL as a diagnostic method has not been addressed in published studies.

In conclusion we have described a patient with an isolated pulmonary relapse of WG with several uncommon features and diagnostic difficulties in reaching the correct diagnosis.

### References

1. Fraser RG, Paré JAP, Paré PD, Fraser RS, Genereux GP. Diagnosis of diseases of the chest. 3rd Edn. Philadelphia, W.B. Saunders Co, 1989; II: p. 1245.
2. Cordier J-F, Valeyre D, Guillemin L, Loire R, Brechot J-M. Pulmonary Wegener's granulomatosis: a clinical and imaging study of 77 cases. *Chest* 1990; 97: 15–29.
3. Papiris SA, Manoussakis MN, Drosos AA, *et al.* Imaging of thoracic Wegener's granulomatosis: the computed tomographic appearance. *Am J Med* 1992; 93: 529–536.
4. van der Woude FJ, Rasmussen N, Lobatto S, *et al.* Autoantibody against neutrophils and monocytes: tool for diagnosis and marker of disease activity in Wegener's granulomatosis. *Lancet* 1985; ii: 425–429.
5. Lüdemann G, Gross WL. Autoantibodies against cytoplasmic structures of neutrophil granulocytes in Wegener's granulomatosis. *Clin Exp Immunol* 1987; 69: 350–357.
6. D'Cruz DP, Baguley E, Asherson RA, Hughes GRV. Ear, nose and throat symptoms in subacute Wegener's granulomatosis. *Br Med J* 1989; 299: 419–422.
7. Cohen Tervaert JW, van der Woude FJ, Fauci AS, *et al.* Association between active Wegener's granulomatosis and anticytoplasmic antibodies. *Arch Intern Med* 1989; 149: 2461–2465.
8. Farrelly CA. Wegener's granulomatosis: a radiological review of the pulmonary manifestations at initial presentation and during relapse. *Clin Radiol* 1982; 33: 545–551.
9. Specks U, Wheatly CL, McDonald TJ, Rohrbach MS, DeRemee RA. Anticytoplasmic autoantibodies in the diagnosis and follow-up of Wegener's granulomatosis. *Mayo Clin Proc* 1989; 64: 28–36.
10. Dugowson CE, Aitken ML. Unusual presentation of recurrent Wegener's granulomatosis. *Chest* 1991; 99: 781–784.
11. Gutiérrez-Ravé VM, Ayerza MA. Hilar and mediastinal lymphadenopathy in the limited form of Wegener's granulomatosis. *Thorax* 1991; 46: 219–220.
12. Gurney JW, Schroeder BA. Upper lobe disease: physiologic correlates. *Radiology* 1988; 167: 359–366.
13. Viggiano RW, Swensen SJ, Rosenow EC III. Evaluation and management of solitary and multiple pulmonary nodules. *Clin Chest Med* 1992; 13: 83–95.
14. Gohel VK, Dalinka MK, Israel HL, *et al.* The radiological manifestations of Wegener's granulomatosis. *Br J Radiol* 1973; 46: 427–432.
15. Travis WD, Hoffman GS, Leavitt RY, Pass HI, Fauci AS. Surgical pathology of the lung in Wegener's granulomatosis. *Am J Surg Pathol* 1991; 15: 315–333.
16. Yoshikawa Y, Watanabe T. Pulmonary lesions in Wegener's granulomatosis: a clinicopathologic study of 22 autopsy cases. *Hum Pathol* 1986; 17: 401–410.

17. Yousem SA, Lombard CM. The eosinophilic variant of Wegener's granulomatosis. *Hum Pathol* 1988; 19: 682–688.
18. Kallenberg CGM, Mulder AHL, Cohen Tervaert JW. Antineutrophil cytoplasmic antibodies: a still-growing class of autoantibodies in inflammatory disorders. *Am J Med* 1992; 93: 675–682.
19. Cohen Tervaert JW, Huitema MG, Hené RJ, *et al.* Relapses of Wegener's granulomatosis: prevention by treatment based on antineutrophil cytoplasmic antibody levels - a controlled prospective study. *Lancet* 1990; 336: 709–712.
20. De Remeé RA, McDonald TJ, Weiland LH. Wegener's granulomatosis: observations on treatment with antimicrobial agents. *Mayo Clin Proc* 1985; 60: 27–32.
21. De Remeé RA. The treatment of Wegener's granulomatosis with trimethoprim/sulfamethoxazole: illusion or vision? *Arthritis Rheum* 1988; 31: 1068–1072.
22. Roberts DE, Curd JG. Sulfonamides as anti-inflammatory agents in the treatment of Wegener's granulomatosis. *Arthritis Rheum* 1990; 33: 1590–1593.
23. Hoffman GS, Sechler JMG, Gallin JI, *et al.* Bronchioalveolar lavage analysis in Wegener's granulomatosis. A method to study disease pathogenesis. *Am Rev Respir Dis* 1991; 143: 401–407.
24. Baltaro RJ, Hoffman GS, Sechler JMG, *et al.* Immunoglobulin G antineutrophil cytoplasmic antibodies are produced in the respiratory tract of patients with Wegener's granulomatosis. *Am Rev Respir Dis* 1991; 143: 275–278.