

## CASE REPORT

# Chronic eosinophilic pneumonia as a presenting feature of Churg-Strauss syndrome

J.-J. Hueto-Perez-de-Heredia\*, F.-J. Dominguez-del-Valle\*, E. Garcia\*,  
M.-L. Gomez\*\*, J. Gallego\*\*\*

*Chronic eosinophilic pneumonia as a presenting feature of Churg-Strauss syndrome. J.-J. Hueto-Perez-de-Heredia, F.-J. Dominguez-del-Valle, E. Garcia, M.-L. Gomez, J. Gallego. ©ERS Journals Ltd 1994.*

**ABSTRACT:** We report on a case of Churg-Strauss syndrome in a 30 year old male with a history of perennial rhinitis. The syndrome began nine months earlier with clinico-radiological features typical of chronic eosinophilic pneumonia. Diagnosis of vasculitis was made by skin biopsy, and at that time there was multi-systemic involvement with pulmonary, cardiac, renal, cutaneous and muscular disease, and right vocal chord paralysis, which improved with corticosteroids and cyclophosphamide.

This case report illustrates the possible overlap of chronic eosinophilic pneumonia and the Churg-Strauss syndrome.

*Eur Respir J., 1994, 7, 1006-1008.*

\*Section of Pneumology, \*\*Service of Pathology, and \*\*\*Service of Neurology, Hospital de Navarra, Pamplona, Spain.

Correspondence: J.-J. Hueto, Seccion de Neumologia, Hospital de Navarra, c./ Irunlarrea, 3, 31008 Pamplona, Spain

Keywords: Chronic eosinophilic pneumonia  
Churg-Strauss syndrome

Received: April 20 1993

Accepted after revision December 5 1993

Churg-Strauss syndrome (CSS) is a relatively unusual disease, characterized by hypereosinophilia and systemic vasculitis, that develops in people with asthma and allergic rhinitis. The clinico-pathological parameters initially established by CHURG and STRAUSS [1] were subsequently modified [2, 3].

Chronic eosinophilic pneumonia (CEP) was described as a single entity by CARRINGTON and co-workers [4, 5]. It is characterized by fever, dyspnoea, cough and weight-loss. In a typical manifestation, pulmonary infiltrates appear as negatives of acute pulmonary oedema. Pulmonary, and usually blood, eosinophilia dramatically responds to corticosteroid treatment, but there is a tendency to relapse, with reappearance of radiological infiltrates. Both diseases belong to the group of eosinophilic pneumonias, and the presence or absence of systemic vasculitis differentiates them. Reports of vasculitis initiating as CEP [6-8] are scarce. We present a case of CSS that had started nine months before as a pulmonary eosinophilia with a clinico-radiological picture compatible with CEP, and which in its vasculitis phase involved a paralysis of a vocal chord.

## Case report

A male aged 29 yrs, with a 10 yr history of rhinitis, was admitted to our hospital in July 1990. He had not had hyposensitization treatment at any time, or drugs before admission, except for some sporadic treatment with ampicillin. For the past 5 months he had presented dyspnoea, respiratory noises, dry cough with some

blood-stained sputum and constitutional symptoms, with 10 kg weight-loss. In the days preceding admission, fever, pleural pain and purulent expectoration were also present. Physical examination revealed a temperature of 39°C, a slight redness of the pharynx and global decrease of vesicular breathing, with disseminated rhonchi at pulmonary auscultation. The physical examination was otherwise normal.

Laboratory analyses performed produced the following observations: white blood cell (WBC) count  $15.17 \times 10^9 \cdot l^{-1}$  (eosinophils 7.8%), erythrocyte sedimentation rate (ESR) 80 mm in the first hour, total immunoglobulin E (IgE) 467 IU·ml<sup>-1</sup>. Data for basal arterial blood gases were pH 7.51, arterial oxygen tension (Pao<sub>2</sub>) 7.8 kPa, arterial carbon dioxide tension (Paco<sub>2</sub>) 4.3 kPa. Two sputum cultures for fungi, *Aspergillus* precipitins and a study of parasites in faeces were negative. The lung function tests (LFT) showed: forced vital capacity (FVC) 3.46 l (69% predicted), forced expiratory volume in one second (FEV<sub>1</sub>) 2.40 l (57% pred), FEV<sub>1</sub>/FVC (69%) with positive bronchodilator test. Lung diffusion capacity was not measured.

On the chest X-ray film (fig. 1) bilateral peripheral pulmonary infiltrates were present in axillar regions. Fibreoptic bronchoscopy revealed an inflamed bronchial mucosa, and bronchoalveolar lavage (BAL) cell count comprised 48% eosinophils, and no fungi. Bronchial biopsy revealed a submucosal infiltrate of leucocytes, with polymorphonuclear cells and eosinophils predominating. A diagnosis of chronic eosinophilic pneumonia was made, and treatment was initiated with 60 mg·day<sup>-1</sup> of prednisone, resulting in rapid clinical improvement,

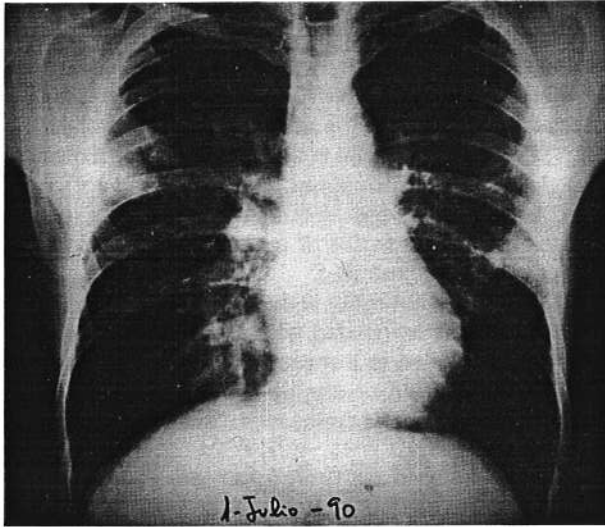


Fig. 1. — Chest X-ray showing bilateral peripheral pulmonary infiltrates in axillar regions.

disappearance of pulmonary infiltrations and blood hyper-eosinophilia, as well as normalization of LFT and ERS after 8 days.

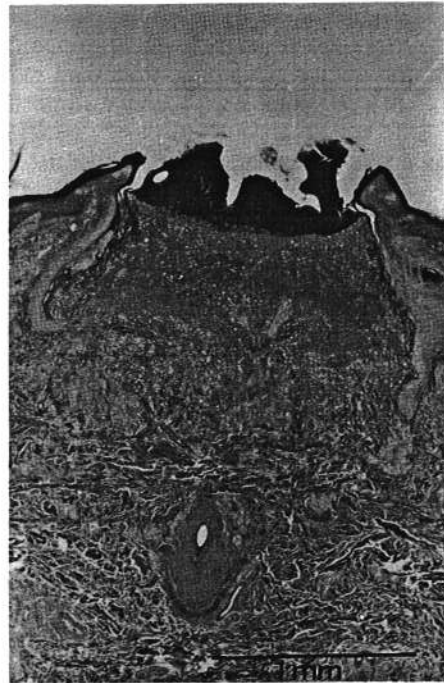In September 1990, coinciding with a reduction in the corticosteroid dose, the patient began to experience a recurrence of coughing, expectoration, and respiratory sounds, without pulmonary infiltrates, blood hyper-eosinophilia or alterations in respiratory function. Later, on his own initiative, he reduced the dose of prednisone to 5 mg·day<sup>-1</sup>, which led to progressive physical deterioration for four months. He was readmitted to hospital in March 1991, with an increase of respiratory symptomatology, coughing, expectoration (sometimes blood-stained), dyspnoea, loss of weight (about 19 kg), slight fever, widespread myalgias, skin lesions and voice dysfunction. On physical examination the patient was in a generally poor condition, with pale skin, and semispherical papules with whitish adherent scales and ecchymoses, especially on the elbows, palmar zone of the fingers, ear lobes and the outer part of both ankles. Cardiac auscultation revealed a systolic murmur audible at each heart valve focus. Pulmonary auscultation revealed bilateral basal crepitations. WBC count was  $23.72 \times 10^9 \cdot l^{-1}$  (eosinophils 47%), haemoglobin 91 g·l<sup>-1</sup>, haematocrit 29%, ESR 128 mm in the first hour, immunoglobulin G (IgG) 38.6 g·l<sup>-1</sup>, and total IgE 1,251 IU·ml<sup>-1</sup>. In the urine, proteins were 2.1 g·24 h<sup>-1</sup>, and blood 0.6 mg·l<sup>-1</sup> with 50–80 red cells·field<sup>-1</sup> in the sediment. Serum viral hepatitis B markers were negative, as were the *Aspergillus* precipitins. Data for basal arterial blood gases were pH 7.46,  $P_{aCO_2}$  4.83 kPa,  $P_{aO_2}$  9.97 kPa.

On chest X-ray, the cardiac silhouette was normal, with a slight right basal pulmonary interstitial pattern. Lung function tests showed: FVC 2.48 l (49% pred); FEV<sub>1</sub> 1.92 l (45% pred); FEV<sub>1</sub>/FVC 77%; total lung capacity (TLC) 5.46 l (78% pred); single-breath diffusing capacity for carbon monoxide (SB-Tlco) 8.34 mmol·min<sup>-1</sup>·kPa<sup>-1</sup> (71 % pred), SB-Tlco/alveolar ventilation (SB-Tlco/ $\dot{V}_A$ ) 1.91 mmol·min<sup>-1</sup>·kPa<sup>-1</sup>·l<sup>-1</sup> (90 % pred). We discovered a right band paralysis by laryngoscopy.

The echocardiogram showed an aortic valve regurgitation grade II/IV, moderate mitral regurgitation and volume left ventricular overload with normal ejection fraction.

On skin biopsy (fig. 2a and b) the most remarkable finding was a central ulceration with a granulomatous

a)



b)

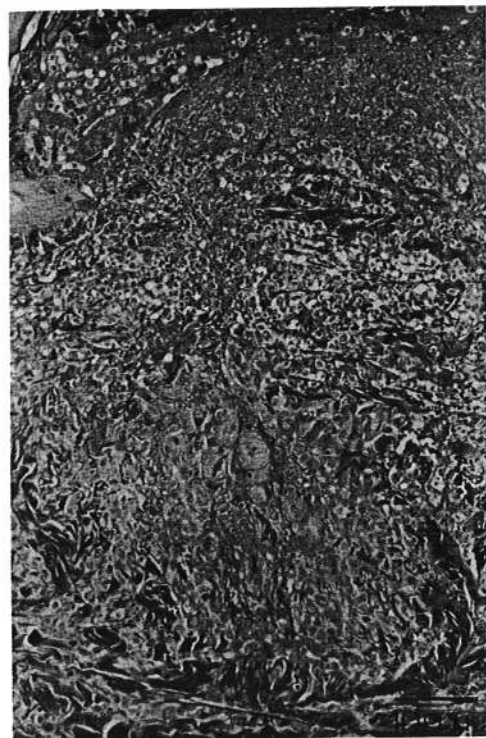


Fig. 2. — a) Skin lesion with central ulceration and granulomatous infiltrate at the bottom. (Haematoxylin and eosin; magnification  $\times 38$ ). b) Detail of extravascular granulomatous foci with central fibrin, collagen degeneration, necrotic neutrophils and eosinophils, histiocytes and fibroblasts. (Haematoxylin-eosin; magnification  $\times 146$ ).

infiltrate. The granulomatous lesions were extravascular, with a central zone of fibrinoid necrosis, collagen degeneration, and necrotic neutrophils and eosinophils. There were no recognized vascular structures within the necrosis. The vessels located in this area also showed fibrinoid necrosis.

The patient was treated with prednisone and cyclophosphamide, with a good response including rapid disappearance of respiratory symptoms, fever and myalgias during the first week, total normalization of eosinophil count and ESR after two weeks and of IgE after five weeks, progressive disappearance of the dermal lesions and vocal chord dysfunction with total recovery after two months, and normalization of the respiratory function (volumes and TLCO) after one month. A slight TLCO/ $\dot{V}_A$  deficit (average 72 % pred) persisted after total normalization of lung volumes. The echocardiogram, repeated 11 months later, was unchanged.

### Discussion

CSS and CEP are two infrequent disorders, probably of immunological aetiology, in which the eosinophil, a cell currently considered as cytotoxic [9], plays a critical role. Although both entities had very different characteristics in their original description [1, 4], it is often difficult to distinguish between them. In pure CEP, the systemic expression of vasculitis never appears.

According to LANHAM *et al.* [10] up to 40% of cases of CSS can present with pulmonary infiltrations, asthma and eosinophilia before the development of the systemic vasculitis. There are some reports of vasculitis initiating as CEP several years before the appearance of systemic disease [6-8].

The current case report illustrates the possible relationship between CSS and CEP. The patient, with rhinitis as the only antecedent, initially presented with pulmonary and blood eosinophilia, pulmonary infiltrations and asthma, without any other systemic involvement. The response to corticosteroid treatment was dramatic; chest X-ray was typical, BAL findings were characteristic, and parasites and fungi, (especially *Aspergillus*) were not found. Moreover, the patient had no previous drug treatment except for sporadic cycles of ampicillin, with no relationship to the evolution and progress of the disease. He thus complied with the definition of CEP [4], before progression, 9 months later, to systemic vasculitis.

Regarding this evolution, two possibilities are to be considered. The first is that initial CEP later progressed towards a vasculitis, the second is that CSS simply began as CEP. We feel that the close relationship between both

entities could favour idiopathic CEP being a part of the CSS complex.

Mononeuritis multiplex is the most usual neurological manifestation in CSS, but cranial nerves can also be affected, especially the optic nerve. Lesions of the II, III, VII and VIII nerves [10-13] have less frequently been described. We found no previous reports of vocal chord paralysis like that observed in our patient, which reverted after two months of treatment with cyclophosphamide and corticosteroid.

In agreement with other authors [3, 10], we think that several disorders associated with asthma and eosinophilia may be included in a spectrum of diseases, in which the eosinophil could determine the development of the lesions.

### References

1. Churg J, Strauss L. Allergic granulomatosis, allergic angiitis and periarteritis nodosa. *Am J Pathol* 1951; 27: 277-301.
2. Chumbley LC, Harrison EG, De Remee RA. Allergic granulomatosis and angiitis (Churg-Strauss syndrome): report and analysis of 30 cases. *Mayo Clin Proc* 1977; 52: 477-484.
3. Churg J, Strauss L. Interstitial eosinophilic pneumonitis, pleuritis and angiitis (letter). *N Engl J Med* 1981; 304: 611.
4. Carrington CB, Addington WW, Golf AM, *et al.* Chronic eosinophilic pneumonia. *N Engl J Med* 1969; 280: 787-798.
5. Liebow AA, Carrington CB. The eosinophilic pneumonias. *Medicine (Baltimore)* 1969; 48: 251-285.
6. McCarthy DS, Pepys J. Cryptogenic pulmonary eosinophilia. *Clin Allergy* 1973; 3: 339-351.
7. Cogen FC, Maycock RL, Zweiman B. Chronic eosinophilic pneumonia followed by polyarteritis nodosa complicating the course of bronchial asthma. *J Allergy Clin Immunol* 1977; 600: 377-382.
8. Kinsella DL, Simpson HN. Loeffler's pneumonia terminating in fatal periarteritis nodosa. *J Am Med Assoc* 1967; 202: 101-103.
9. Venge P, Dahl R, Fredens K, Peterson C. Epithelial injury by human eosinophils. *Am Rev Respir Dis* 1988; 138: S54-57.
10. Lanham J, Elkon K, Pusey C, Hughes G. Systemic vasculitis with asthma and eosinophilia: a clinical approach to the Churg-Strauss syndrome. *Medicine (Baltimore)* 1984; 63: 65-81.
11. Cooper BJ, Bacal E, Patterson R. Allergic angiitis and granulomatosis. *Arch Intern Med* 1978; 138: 367-371.
12. Moore P, Cupps T. Neurological complications of vasculitis. *Ann Neurol* 1983; 14: 155-167.
13. Sigal L. The neurological presentation of vasculitic and rheumatoid syndromes. *Medicine* 1987; 66: 157-180.