

HLA-DRB1* alleles and symptoms associated with Heerfordt's syndrome in sarcoidosis

P. Darlington^{1,2}, L. Tallstedt³, L. Padyukov⁴, I. Kockum⁵, K. Cederlund⁶, A. Eklund² and J. Grunewald².

¹ Department of Medicine, Division of Respiratory Medicine, Södersjukhuset (Stockholm South General Hospital), Stockholm, Sweden. ² Department of Medicine, Division of Respiratory Medicine, Karolinska University Hospital, Solna, Sweden. ³ St. Erik Eye Hospital, Stockholm, Sweden. ⁴ Department of Medicine, Division of Rheumatology, Karolinska University Hospital, Solna, Sweden. ⁵ Department of Clinical Neurosciences, Neuroimmunology unit, Centrum for Molecular Medicine, Karolinska University Hospital, Solna, Sweden. ⁶ Department of Clinical Science, Intervention and Technology (CLINTEC), Division of Radiology, Karolinska University Hospital, Huddinge, Sweden. All from Karolinska Institutet, Stockholm, Sweden.

Running title: HLA-DRB1 *04 and Heerfordt's syndrome

Key words: eye involvement, Heerfordt's syndrome, human leukocyte antigen, ocular sarcoidosis, sarcoidosis.

Correspondence:

Pernilla Darlington

Department of Medicine, Division of Respiratory Medicine, Södersjukhuset (Stockholm South General Hospital), Sjukhusbacken 10, 118 83 Stockholm, Sweden.

Telephone: 46-733826902

E-mail: pernilla.darlington@sodersjukhuset.se

Abstract

Background: Heerfordt's syndrome (HS), consists in its complete form of uveitis, parotid or salivary gland enlargement and cranial nerve palsy. The objective of the present study was to analyze if there are links also between HLA-DRB1* alleles and HS, since it is a specific phenotype of sarcoidosis.

Methods: 1000 patients with sarcoidosis, out of which 83 had symptoms associated with HS, were included in the study together with a group of 2000 healthy individuals from the same population, matched for gender and age. HLA-DRB1* allelic groups were determined for all individuals, and comparisons were made between different disease subgroups and between patients and healthy controls.

Results: We found that the HLA-DRB1*04 allele was overrepresented in patients with symptoms associated with HS. Eighty-three (8.3%) of all patients had one or more of the symptoms and forty-six (55%) of them were HLA-DRB1*04 positive. Forty-four (55%) of the patients with ocular sarcoidosis, i.e. the most common symptom associated with HS, were HLA-DRB1*04 positive, compared to 35.9% of healthy controls ($p=0.0008$), and only 26.6% of the whole group of sarcoidosis patients ($p<0.0001$).

Conclusions: HLA-DRB1*04 seems to protect against overall sarcoidosis, but to be a significant risk factor for ocular sarcoidosis as well as for other manifestations associated with HS.

Introduction

Sarcoidosis is a systemic granulomatous disease of unknown etiology. It is characterized by formation of non-caseating granulomas in the affected organs. The lungs and/or thoracic lymph nodes are engaged in more than 90 % of all cases but almost any organ such as the eyes, skin, heart and the nervous system can be involved (1, 2). The course of the disease varies significantly. Many patients recover but some develop chronic disease with pulmonary fibrosis and eventually respiratory failure. The first line of treatment is oral corticosteroids. Treatment is usually initiated in patients with progressive loss of lung function, but also extra-pulmonary manifestations such as involvement of the heart, eyes and nervous system are common indications for treatment (1).

Studies have earlier shown that there are links between certain HLA-class II alleles and distinct clinical manifestations of sarcoidosis such as the well known association of HLA-DRB1*03 and Löfgren's syndrome (LS) (3, 4). LS is characterized by an acute onset usually with fever, bilateral ankle arthritis and/or erythema nodosum and bilateral hilar lymphadenopathy with in some cases parenchymal infiltrates (5). LS is common in Scandinavia but very rare in patients of Japanese origin in whom DRB1*0301 is virtually missing (6). Heerfordt's syndrome (HS) is another, more unusual manifestation of sarcoidosis described in the literature. This syndrome was originally termed "Febris uvea-parotidea subchronica" and was described by Christian Heerfordt in 1909. He described three patients with uveitis, parotid swelling, cranial nerve palsy and fever (7). In 1937, Jan Waldenström classified it as a distinct manifestation of sarcoidosis (8). The complete form of HS are considered to consist of uveitis, parotid or salivary gland enlargement and cranial palsy, especially the facial, and fever is also common (9).

In patients with ocular sarcoidosis, uveitis is by far the most common manifestation and sometimes co-existing with symptoms associated with HS such as cranial nerve palsy and engagement of parotid and/or salivary glands. The incidence of eye involvement in patients with sarcoidosis varies from 5% in Finland to more than 70% in Japan, supporting the notion of a genetic influence on signs of disease presentation (10-12). Other examples of eye involvement are lacrimal gland inflammation, optic neuritis and conjunctival granulomas. Commonly, both eyes are engaged (11). Anterior uveitis is reported to be more common in African Americans (70-75%) while posterior uveitis is more common in Caucasians (65-83%) (13). In patients with sarcoidosis with anterior uveitis, treatment with topical corticosteroids is commonly sufficient, while posterior uveitis usually requires more frequent monitoring and is more difficult to treat (12).

Since HS is a distinct phenotype of sarcoidosis, and there is a strong genetic influence as suggested by sharp differences in disease phenotypes in patients with different ethnic origin, we hypothesized that there might be associations between specific HLA-DRB1* alleles and HS. The objective of the present study was therefore to analyze if there are links between HLA-DRB1* alleles and symptoms associated with HS such as uveitis, engagement of parotid and/or salivary glands or cranial nerve palsy, with particular focus on uveitis.

Materials and Methods

Study subjects

A total of 1000 HLA-typed patients were included in the study of which 383 were classified as having Löfgren's syndrome. All included were consecutive patients referred to the out-patient clinic at the Division of Respiratory Medicine, Karolinska University Hospital, Solna,

Sweden, but also patients from the South General Hospital, Sweden, were included. All patients were referred for diagnostic investigation and activity assessment to the respective out-patient clinic. The vast majority of patients were seen by one of the authors (A.E), essentially from 1994 and onwards. Patients were diagnosed with sarcoidosis through typical clinical and radiographic manifestations, findings at bronchoscopy with bronchoalveolar lavage (BAL) including an elevated CD4/CD8 cell ratio, and positive biopsies, using the criteria outlined by the World Association of Sarcoidosis and other Granulomatous disorders (WASOG)(14). All patients with ocular involvement were examined by ophthalmologists and had findings compatible with ocular sarcoidosis according to International Criteria for the Diagnosis of Ocular Sarcoidosis (11). In total 80 of the 1000 patients were found to have ocular sarcoidosis i.e. inflammatory activity located to the eye, secondary to the sarcoidosis disease. Only patients with symptoms from the eyes (such as pain, photophobia and blurred vision) were seen by an ophthalmologist, in the vast majority by one of the authors (L.T) at St. Erik Eye Hospital. Patients with uveitis were classified according to anterior, posterior, unilateral or bilateral involvement. Ocular manifestation with only iridocyclitis without signs of posterior uveitis were defined as anterior uveitis and patients with vitreous floaters/snowballs, venous vasculitis, neovascularization, choroidal granulomas, macular oedema, papilloedema or chororetinal peripheral lesions were classified as having posterior uveitis. Patients were judged to have involvement of parotid and salivary glands if it was biopsy-proven and/or if there was an obvious enlargement and simultaneously co-existing findings compatible with sarcoidosis. Patients were defined as having neurosarcoidosis according to Zajicek criteria (in this study, only patients with cranial nerve palsy and coexisting findings compatible with sarcoidosis were included) (15). Chest radiographs were evaluated and findings staged by one of the authors (K.C), who is subspecialized in chest radiology, with long experience of interstitial pulmonary disease. Chest radiographs were

controlled at the time of diagnosis and at two years follow up. Chest radiographs in patients with sarcoidosis were classified into five stages: Stage 0 - normal; Stage I - bilateral hilar lymphadenopathy; Stage II - bilateral lymphadenopathy with parenchymal infiltrates; Stage III – parenchymal infiltrates alone; Stage IV - fibrotic bands and volume retraction (16). The study was approved by the Regional Ethical Committee and all patients included gave their informed consent.

All 1000 patients were characterized by age, gender, HLA-type, treatment / no treatment, resolving / non-resolving disease and Löfgren's syndrome / non-Löfgren's syndrome (Table 1). Non-resolving disease was defined as disease duration >2 years with remaining signs of active disease as evaluated by the chest radiographic findings, recurrent uveitis, and other disease parameters (i.e. fatigue, cough and fever). Patients were in general followed at the outpatient clinic for at least two years and longer if signs of active disease. Symptoms associated with Heerfordt's syndrome (HS) were defined as uveitis, engagement of parotid and/or salivary glands and cranial nerve palsy. Patients with uveitis and one of the other symptoms were regarded having an incomplete form of HS and patients with all three symptoms to have the complete form. The control group consisted of healthy individuals from the same population, 1138 female and 862 males, and were matched for the distribution of age and gender with the patients.

HLA typing

Genomic DNA was extracted from whole blood samples and HLA-DRB1* allelic groups were determined (Table 2) for every patient using the PCR-SSP technique (Olerup SSP DR low resolution kit, Saltsjöbaden, Sweden) (17). For the controls the majority were HLA-typed

using PCR-SSP but some of the HLA-DRB1* alleles were determined with restriction length polymorphism (18, 19).

Statistical analysis

Data were analyzed by the Chi-square test or in the case of small numbers by Fisher's Exact Test. Statistical analysis were performed with Graph Pad Prism 4.03. When comparing different allele frequencies $p < 0.003$ ($p < 0.05/13$) was regarded as significant (after Bonferroni correction for the number of alleles ($n=13$), and otherwise $p < 0.05$ was regarded as significant.

Results

Among all 1000 HLA-typed sarcoidosis patients, 80 (8%) were found to have eye involvement and 72 of them had uveitis, 19 (2%) were found to have engagement of parotid or salivary glands and facial nerve palsy occurred in 11 (1%) (Figure 1). Uveitis, involvement of parotid or salivary glands and cranial nerve palsy are three different symptoms known to be associated with Heerfordt's syndrome (HS), and simultaneous presence of all symptoms represents the complete form of this syndrome. The majority of patients with ocular engagement had uveitis, often bilateral and usually a prolonged disease course. For the patients with involvement of parotid and salivary glands, they were bilateral in eight cases and

unilateral in nine cases (in two cases unknown). In all cases the salivary gland enlargement gradually subsided. The cranial nerve palsy was unilateral and transient in all 11 cases. In patients with symptoms associated with HS, the diagnosis was verified with biopsy in the majority of patients and most of them were taken from parotid and salivary glands, peripheral lymph nodes, skin lesions, lungs and in rare cases also from the eyes. The remaining patients had except for the extra pulmonary manifestations, typical chest x-ray findings, Löfgren's syndrome, high CD4/CD8 ratio in bronchoalveolar lavage fluid and/or an elevated serum ACE-level. Thirteen patients had radiological stage 0 and eight of these patients had the diagnosis confirmed via biopsy taken from peripheral lymph nodes, skin biopsies or parotid glands. The other five were patients that met the criteria by having typical ocular findings as judged by an experienced ophthalmologist and also laboratory tests supporting the diagnosis.

Together, 83 patients had uveitis and/or engagement of parotid or salivary glands and/or cranial palsy and 46 (55%) of them were HLA-DRB1*04 positive. Forty (55%) of the patients with uveitis were HLA-DRB1*04 positive, ten of the patients (53 %) with involvement of parotid and salivary glands and eight of the patients (73 %) with cranial nerve palsy also carried the same allele. Out of the 83 patients with at least one of the symptoms associated with HS, there were 16 patients who had two or three of the symptoms, ten (62.5 %) were HLA-DRB1*04 positive (Figure 2 a+ b). Among the 80 patients with ocular sarcoidosis, eight patients had not uveitis and were therefore not counted as having symptoms associated with HS. Several of these patients had instead conjunctival granulomas. These eight patients were included, however, in the whole group of patients with ocular sarcoidosis (i.e. inflammatory activity located to the eye, secondary to the sarcoidosis disease). Four of these patients (50%) were HLA-DRB1*04 positive.

HLA-DRB1*04 was present in 266 (26.6%) of all 1000 patients compared with 718 (35.9%) in healthy controls ($p<0.0001$). The HLA-DRB1*04 allele was strongly connected to the HLA-DQB1*03 allele (data not shown). Among the 266 HLA-DRB1*04 positive patients 46 (17%) had uveitis and/or engagement of parotid and salivary glands and/or cranial nerve palsy. Among the 734 HLA-DRB1*04 negative patients, these combinations occurred in only 37 patients (5%) ($p<0.0001$). Thus, there was a 3.4 times increased risk for having HS-associated manifestations in HLA-DRB1*04 positive patients. Twenty-one of the whole group of sarcoidosis patients were homozygous for HLA-DRB1*04 and 7 (33%) of them had eye disease, in two cases with concomitant facial palsy. Patients homozygous for HLA-DRB1*04 therefore had a 6.6 times increased risk for HS associated symptoms (Figure 3). Thirty-three of the 44 HLA-DRB1*04 positive patients with ocular sarcoidosis were sub-typed, and 28 (85%) of them carried the HLA-DRB1*0401 allele (Figure 4).

In patients with ocular sarcoidosis, other extra-pulmonary manifestations were common, as 32 patients (40%) had at least one other manifestation (e.g. skin lesions, cranial nerve palsy and hypercalcemia).

Löfgren's syndrome was less common in patients with ocular sarcoidosis ($p<0.0001$) compared to patients without. Also the HLA-DRB1*03 allele significantly associated with this syndrome was less common among patients with eye involvement compared to patients without ($p=0.0002$). The HLA-DRB1*03 allele was also less common among patients with incomplete or complete form of HS where only two (12.5%) had the allele. In addition, the frequency of HLA-DRB1*01 was also significantly lower among patients ocular sarcoidosis compared to healthy controls and seemed to be protective against contracting overall sarcoidosis as well (Table 2).

Most of the patients with ocular engagement had uveitits (n=72). Among 68 patients where we had access to more detailed information, 36 (53%) had posterior uveitis, and the uveitis was bilateral in 45 (66%) (Table 3). The localisation of uveitis did not differ significantly between the HLA-DRB1*04 positive and negative patients.

Fifty-eight of the patients with ocular sarcoidosis were followed with chest x-ray at onset of disease and two years later. After two years, chest radiograph showed enlarged lymph nodes and/or infiltrates in 49 (84.5%) of 58 patients (Figure 5). In seventy patients with ocular engagement, where there was information available regarding disease course, only 6 had a resolving disease and four of these had Löfgrens's syndrome. As shown in Figure 6 a, there was no obvious difference between HLA-DRB1*04 negative and HLA-DRB1*04 positive patients with ocular sarcoidosis with regard to disease progress. Among HLA-DRB1*04 positive patients without ocular engagement (n=202), 101 (50%) had a resolving disease (Figure 6 b) compared to only 5 (12.5 %) with ocular disease ($p<0.0001$).

Discussion

Complete Heerfordt's syndrome (HS) consists of bilateral uveitis, parotid or salivary gland swelling and cranial nerve palsy. The complete form of the syndrome is rare as also described by Scadding (9). Among our 1000 patients only three showed the complete syndrome. In accordance with Scadding's modification of HS, we have divided the patients as having incomplete or complete forms of HS. We have also added patients with only uveitis and patients without uveitis but with the other two manifestations and described them as having symptoms associated with HS. Fever is described to be common in HS, but we have chosen to exclude this parameter, as information about the body temperature usually was lacking. Christian Heerfordt who originally described the syndrome, did not include pulmonary engagement as a part of the syndrome (7). In our study 67 (81%) of the patients with HS associated symptoms had thoracic involvement. The patients with cranial nerve palsy and parotid or salivary glands are few. It is, however, interesting that 10/11 patients with cranial

nerve palsy also had uveitis and this strong connection strengthens that this is a syndrome. Half of the patients with parotid and salivary gland enlargement did not have ocular engagement and 6/10 were HLA-DRB1*04 positive. This also indicates that the connection to HLA-DRB1*04 is not only driven by the uveitis. The high frequency of HLA-DRB1*04 in these patients seems to be a possible genetic link which could explain why these symptoms known to be part of HS, occur simultaneously. Out of the patients with other ocular inflammatory manifestations than uveitis, half of them were HLA-DRB1*04 positive.

We found an overrepresentation of HLA-DRB1*04, particularly HLA-DRB1*0401, in patients with the HS-associated manifestations uveitis, parotid and salivary glands as well as cranial nerve palsy. HLA-DRB1*04 has otherwise, in this as well as in some previous studies, shown to be protective against sarcoidosis (20, 21). There are other studies that support our findings of a genetic association to symptoms associated with HS. For example associations between HLA-DRB1*0401 and ocular sarcoidosis have been suggested, but in significantly smaller patient cohorts and where patients of different ethnic origins were included (22, 23). Correlations between HLA-DRB1*0401 and involvement of parotid and salivary glands were noted in a study by Rossman et al (22), however the correlation was significant only for Afro-Americans and not for Caucasians. In a more recent study by Sato et al, a link between DRB1*0803 and neurosarcoidosis was reported in Japanese patients as well as between DRB1*0401/DQB1*0301 and uveitis in a UK population (23). Previous studies have also shown genetic associations for uveitis in sarcoidosis with the HSP70/Hom rs2075800 G allele in patients from the UK and with CTLA-4 gene polymorphism in patients from Japan (24, 25). There are also studies about genetic

similarities between inflammatory bowel disease and sarcoidosis, both diseases associated with an increased risk for uveitis (26, 27). One possible explanation to the genetic linkage with a specific HLA-allele is cross reactivity, i.e. that there are proteins for example in the eye that resembles the antigen which the immune system initially reacted against. HLA-DRB1*04 allows according to this theory an adequate antigen presentation of eye derived proteins. Patients who are homozygous for HLA-DRB1*04 may have a more efficient antigen presentation, leading to an inflammatory reaction.

In our study, the uveitis was often bilateral and posterior and no significant differences between the HLA-DRB1*04 positive and negative patients were found. The presence of the HLA-DRB1*03 allele, previously shown to be associated with good prognosis in Scandinavian patients (4, 28) was significantly reduced in patients with ocular sarcoidosis. However, in all patients the frequency of the allele was higher compared to healthy controls and it seemed to be associated with an increased risk of contracting the sarcoidosis disease. HLA-DRB1*01, which previously was found to strongly protect against non-Löfgren sarcoidosis (21) was found to protect also against eye involvement (Table 2).

Eighty patients (8.0 %) were found to have ocular sarcoidosis and this prevalence is low compared with several other studies, probably for several reasons. One explanation may be our relatively strict criteria for the patients diagnosed with ocular sarcoidosis. Only patients with obvious symptoms were examined for eye involvement. Patients with conjunctivitis sicca were for example excluded in our study but included in others (29, 30). Seventy patients were followed for two years, and among these we found no significant difference in outcome between the HLA-DRB1*04 positive or negative patients. In comparison with patients

without ocular sarcoidosis, patients with eye involvement had a significantly poorer prognosis with higher frequency of non-resolving disease. Therefore, ocular engagement seems to be of greater prognostic importance than HLA-type. This in contrast to patients with Löfgren's syndrome, where the HLA-type (HLA-DRB1*03) could be a prognostic marker (2, 4). Ethnicity is also likely to have an impact on the prevalence of ocular sarcoidosis, and it is known that for example in Japan the incidence is considerably higher than in Scandinavia (10). Most of the patients with ocular sarcoidosis in our study had non-resolving disease which sharply differs from the Japanese sarcoidosis patients where ocular engagement often is associated with good prognosis (31). In a study by Pietinalho et al where Finnish and Japanese patients with sarcoidosis were compared, ocular sarcoidosis was found in more than half of the Japanese patients compared with 5 % in the Finnish cohort. The majority of the Japanese patients had a normal chest radiograph after two years (32).

The vast majority of the patients were from one single centre, likely representative of the general population since these patients are normally investigated at a respiratory department rather than in an out patient clinic. However, a possible bias against mild forms of sarcoidosis could not be ruled out. Patients with one episode of uveitis might not always be investigated for sarcoidosis and patients with only cranial nerve palsy are probably not routinely investigated with chest x-ray.

In conclusion, we set-out to analyze associations between HLA-DRB1* alleles and symptoms linked to HS in a large well-characterized, homogenous Scandinavian sarcoidosis population, and we specifically investigated ocular involvement. The results of our study show that there is a significant correlation between HLA-DRB1*04 and symptoms linked to HS. However in sharp contrast to another syndrome where also a genetic association is known, Löfgren's

syndrome, HS have a prolonged disease course. Therefore, it seems reasonable to suggest that HLA-DRB1*04 positive patients should be closely monitored for particularly uveitis, but also parotid or salivary gland enlargement and cranial nerve palsy. Also, involvement of one of these organs calls for increased awareness of possible non-resolving disease and a more intensive follow-up.

Acknowledgements

The authors would like to thank Heléne Blomquist, Benita Engvall, Benita Dahlberg, Margita Dahl, Gunnel De Forest, Abraham Roos and Bo Hedquist for their assistance. The Swedish Childhood diabetes study, Diabetes Incidence Study in Sweden and Epidemiological Investigation of Multiple Sclerosis (EIMS) and EIRA study group are acknowledged for sharing HLA genotypes from their controls.

This study was supported by The Swedish Heart-Lung Foundation, The King Oscar II Jubilee Foundation, the Swedish Research Council, Torsten and Ragnar Söderberg's Foundation, Karolinska Institutet, support was also given through the regional agreement on medical training and clinical research (ALF) between Stockholm County Council and the Karolinska Institutet. None of the funding sources had any influence on the production of this manuscript.

Authors contribution

PD designed and coordinated the study, characterized patients, summarized data and drafted the manuscript. LT co-designed the study and characterized patients, interpreted data and helped writing the manuscript. LP interpreted clinical information and HLA-data. IK interpreted clinical information and HLA-data. KC classified radiographs. AE co-designed the study and characterized patients, interpreted data and helped writing the manuscript. JG co-

designed the study and characterized patients, interpreted data and helped writing the manuscript.

Competing interest

The authors declare that they have no competing interest.

Figure legends

Figure 1

Patients with uveitis, parotid and salivary gland enlargement and facial nerve palsy. The numbers of patients are given. As shown, some of the patients had two or three of the symptoms.

Figure 1

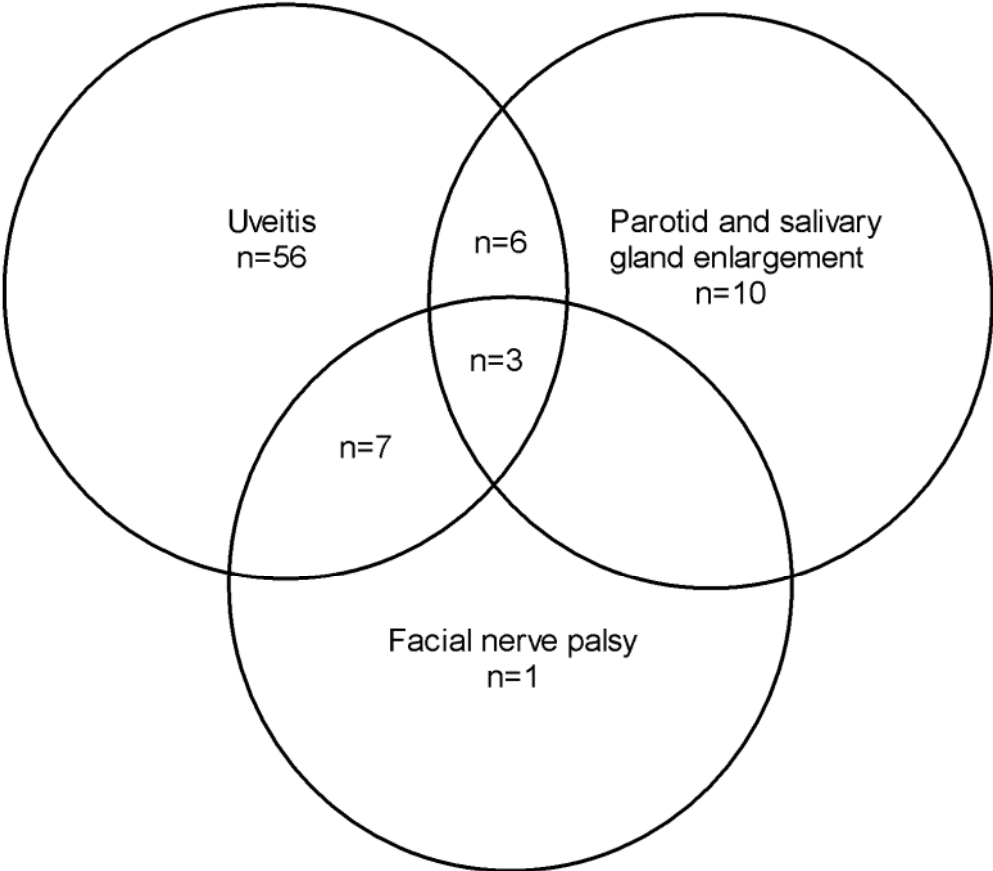


Figure 2

Figure a shows frequency of HLA DRB1*04 in healthy controls, all sarcoidosis patients and patients with ocular sarcoidosis. Figure b shows frequency of HLA DRB1*04 in healthy controls, in patients with symptoms associated with HS (uveitis, parotid and/or salivary gland enlargement and cranial nerve palsy), and in patients with incomplete HS i.e. simultaneous occurrence of at least two of the three symptoms or all three of them i.e. complete HS. P-value of the frequency is in comparison to healthy controls.

Figure 2

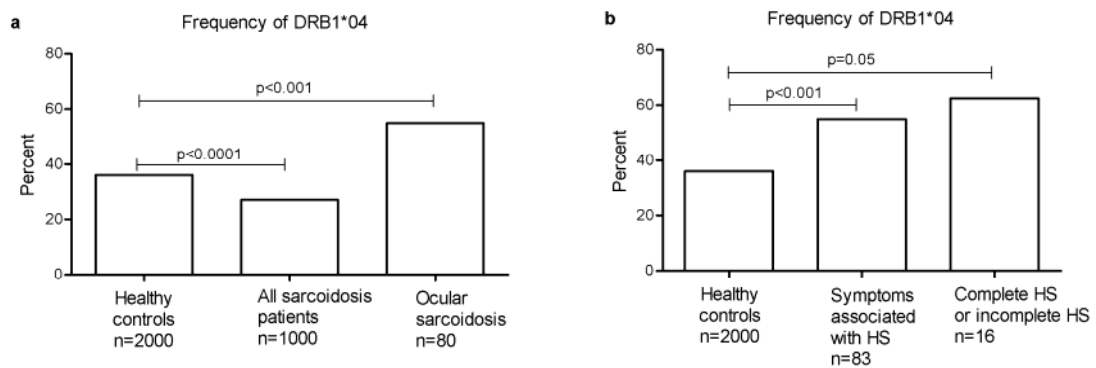


Figure 3

Frequency of patients with symptoms associated with HS (uveitis, parotid and/or salivary gland enlargement and cranial nerve palsy) among HLA-DRB1*04 negative, HLA-DRB1*04 heterozygous and HLA-DRB1*04 homozygous patients. P-value of the frequency is in comparison to HLA-DRB1*04 negative patients.

Figure 3

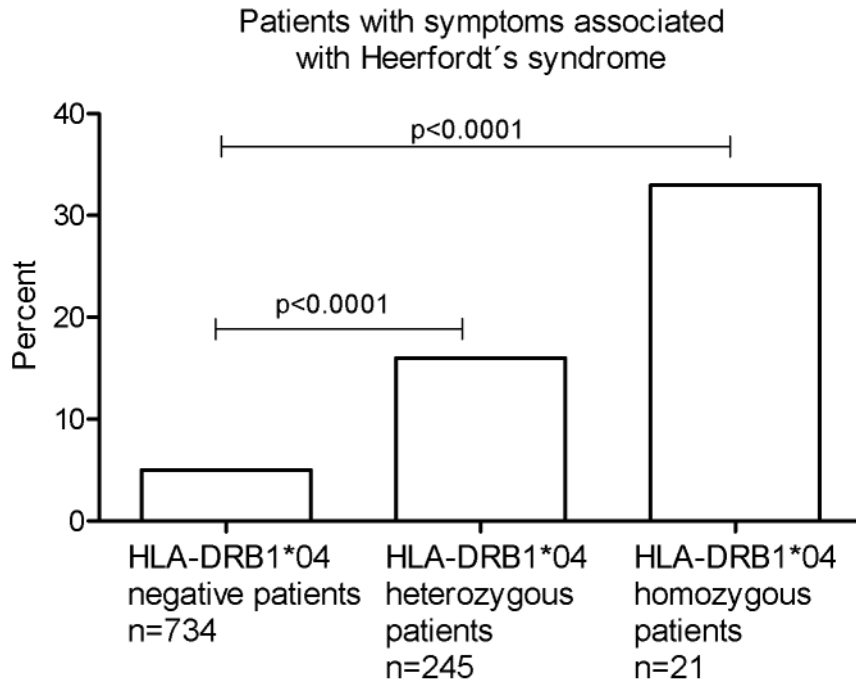


Figure 4

HLA sub typing of DRB1*04 positive patients with ocular sarcoidosis (n=33). Results are presented in percentage of patients belonging to each subgroup.

Figure 4

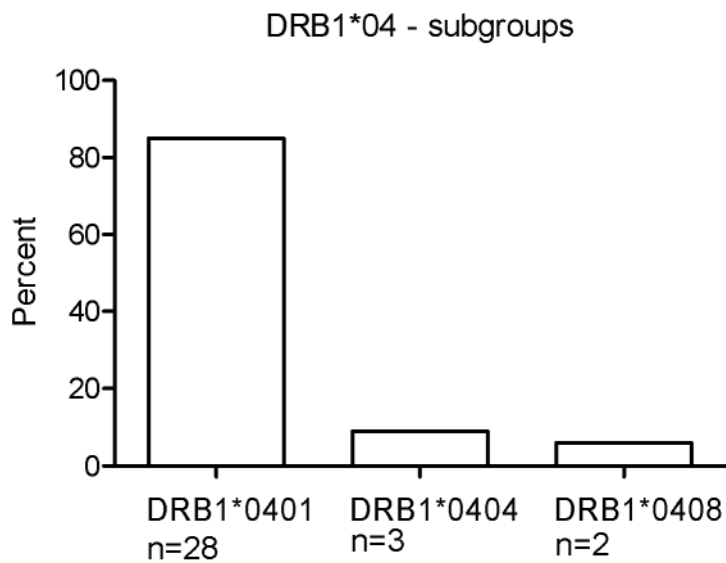


Figure 5

Fifty-eight patients with ocular sarcoidosis and their radiographic stage at onset of disease and two years after diagnosis. Results are presented in percent of patients who belong to radiographic stage 0-IV, respectively.

Figure 5

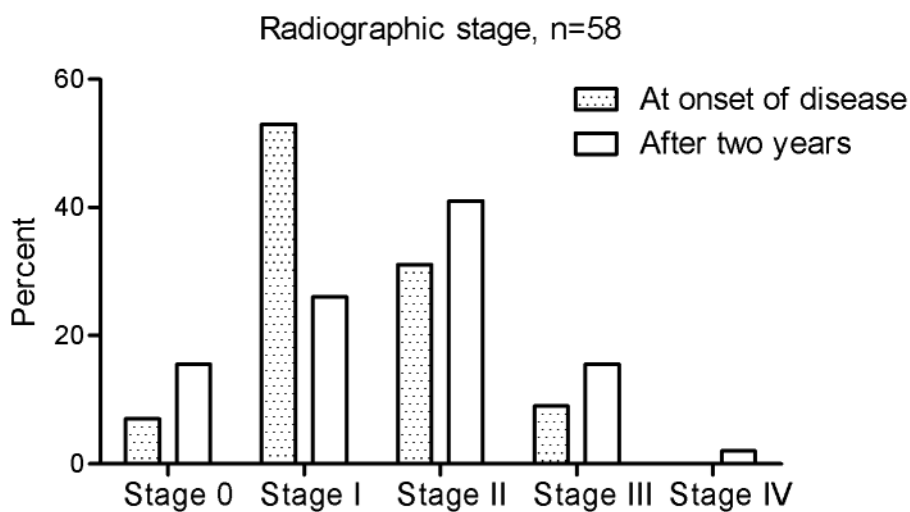


Figure 6

Figure a shows seventy patients with ocular sarcoidosis where there was information available regarding resolving or non-resolving disease. The patients are divided into HLA-DRB1*04 positive and negative, respectively. The numbers of patients with resolving and non-resolving disease are given. In figure b corresponding data on out-come of the disease is given in 202 HLA-DRB1*04 positive and 633 HLA-DRB1*04 negative patients without ocular involvement. There were a significant difference in outcome depending on if they had ocular or non-ocular sarcoidosis ($p < 0.0001$).

Figure 6

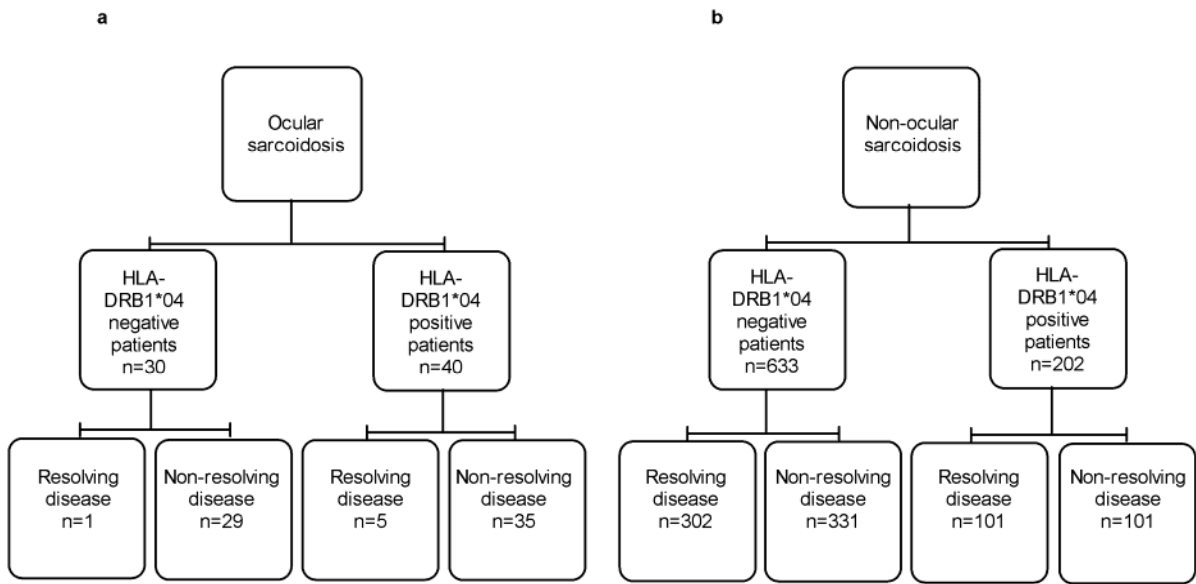


Table 1. Clinical characteristics in patients with ocular sarcoidosis, all sarcoidosis patients and healthy controls.

	Ocular sarcoidosis	All patients with sarcoidosis	Healthy controls
Subjects	80	1000	2000
Gender M/F	40/40	570/430	1138/862
Age, years	37 (19-75)	38 (9-78)	42 (15-73)
Radiographic stage, 0/I/II/III/IV	13/40/21/6/0	61/484/323/104/28	
Never smoker/ever smoker/unknown	38/40/2	553/433/14	
Löfgren/ non-Löfgren	10/70 ***	383/617	
Resolving/non-resolving/unknown	6/64/10 ***	409/493/98	

Age, years: values are medians (min – max)

***= p<0.0001 compared to patients without ocular sarcoidosis

Radiographic stage, see Materials and Methods

Table 2. Carrier frequency (%) of HLA-DRB1 alleles

	Control subjects n=2000	All patients with sarcoidosis n=1000	Ocular sarcoidosis n=80
*01	22.3	12.7***	7.5**
*03	22.7	37.9***	18.8
*04	35.9	26.6***	55.0**
*07	15.9	11.4**	10.0
*08	8.4	8.9	10.0
*09	3.4	2.5	1.2
*10	1.1	1.7	1.2
*11	12.5	12.4	5.0
*12	4.2	5.2	5.0
*13	26.6	26.3	20.0
*14	4.1	8.5***	7.5
*15	27.6	33.1**	36.3
*16	1.5	0.7	1.2

=p value <0.003 and *=p value <0.0001 compared to healthy controls.

Table 3. Characterization and localization of uveitis in anterior/posterior and uni-/bilateral in HLA-DRB1*04 positive (n=36) and negative (n=32) sarcoidosis patients.

Uveitits	All patients n=68		HLA-DRB1*04 positive n=36		HLA-DRB1*04 negative n=32	
	Unilateral	Bilateral	Unilateral	Bilateral	Unilateral	Bilateral
Anterior	19%	28%	17%	36%	22%	19%
Posterior	15%	38%	17%	30%	12%	47%

Note that out of 72 patients with ocular symptoms compatible with Heerfordt's syndrome (i.e. uveitis), there were information about 68 whether it was posterior or anterior.

References

1. Newman LS, Rose CS, Maier LA. Medical progress - Sarcoidosis. *N Eng J Med* 1997;336(17):1224-1234.
2. Iannuzzi MC, Rybicki BA, Teirstein AS. Sarcoidosis. *N Eng J Med* 2007;357(21):2153-2165.
3. Hedfors E, Lindstrom F. HLA-B8/Dr3 in Sarcoidosis - Correlation to Acute Onset Disease with Arthritis. *Tissue Antigens* 1983;22(3):200-203.
4. Berlin M, Fogdell-Hahn A, Olerup O, Eklund A, Grunewald J. HLA-DR predicts the prognosis in Scandinavian patients with pulmonary sarcoidosis. *Am J Respir Crit Care Med* 1997;156(5):1601-1605.
5. Löfgren S. Erythema nodosum. Studies on etiology and pathogenesis in 185 adult cases. *Acta Med Scand* 1946; suppl. 174:1-197.
6. Grunewald J, Shigematsu M, Nagai S, Mikuniya T, Wigzell H, Izumi T, Eklund A. T-cell receptor V gene expression in HLA-typed Japanese patients with pulmonary sarcoidosis. *Am J Respir Crit Care Med* 1995;151(1):151-156.
7. Heerfordt CF. Über eine "Febris uveo-parotidea subchronica" an der Glandula parotis und der Uvea des Auges lokalisiert und häufig mit Paresen cerebrospinaler Nerven kompliziert. *Arch Ophthalmol* 1909;70:254-273.
8. Waldenström J. Some observations on uveoparotitis and allied conditions with special reference to the symptoms from the nervous system. *Acta Med Scand* 1937;91(1-2):53-68.
9. Scadding JG. Sarcoidosis. London: Eyre and Spottiswoode; 1967.
10. Pietinalho A, Ohmichi M, Hiraga Y, Selroos O. The Prognosis of Pulmonary Sarcoidosis in Finland and Hokkaido, Japan - a Comparative-Study. *Sarcoidosis* 1992;9:443-444.

11. Herbort CP, Rao NA, Mochizuki M. International Criteria for the Diagnosis of Ocular Sarcoidosis: Results of the First International Workshop on Ocular Sarcoidosis (IWOS). *Ocul Immunol Inflamm* 2009;17(3):160-169.
12. Baughman RP, Lower EE, Kaufman AH. Ocular Sarcoidosis. *Semin Respir Crit Care Med* 2010;31(4):452-462.
13. Rothova A. Ocular involvement in sarcoidosis. *Brit J Ophthalmol* 2000;84(1):110-116.
14. Costabel U, Hunninghake G. ATS/ERS/WASOG. Statement on Sarcoidosis. Sarcoidosis Statement Committee. American Thoracic Society, the European Respiratory Society, and the World Association of Sarcoidosis and Other Granulomatous Disorders. *Am J Respir Crit Care Med* 1999;160(2):736-755.
15. Zajicek JP, Scolding NJ, Foster O, Rovaris M, Evanson J, Moseley IF, Scadding, JW, Thompson EJ, Chamoun V, Miller DH, McDonald WI, Mitchell D. Central nervous system sarcoidosis diagnosis -- management. *QJM* 1999;92(2):103-117.
16. Scadding JG. Prognosis of Intrathoracic Sarcoidosis in England - a Review of 136 Cases after 5 Years Observation. *Br Med J* 1961;2(526):1165-1172.
17. Olerup O, Aldener A, Fogdell A. HLA-DQB1 and HLA-DQA1 Typing by PCR Amplification with Sequence-Specific Primers (PCR-SSP) in 2 Hours. *Tissue Antigens* 1993;41(3):119-134.
18. Sanjeevi CB, Lybrand TP, Dewese C, LandinOlsson M, Kockum I, Dahlquist G, Sundkvist G, Strenger D, Lernmark A. Polymorphic Amino-Acid Variations in HLA-DQ Are Associated with Systematic Physical Property Changes and Occurrence of Iddm. *Diabetes* 1995;44(1):125-131.
19. Kockum I, Sanjeevi CB, Eastman S, Landin-Olsson M, Dahlquist G, Lernmark A. Complex interaction between HLA DR and DQ in conferring risk for childhood type 1 diabetes. *Eur J Immunogenet* 1999;26(5):361-372.

20. Foley PJ, McGrath DS, Puscinska E, Petrek M, Kolek V, Drabek J, Lympany PA, Pantelidis P, Welsh KI, Zielinski J, du Bois RM. Human leukocyte antigen-DRB1 position 11 residues are a common protective marker for sarcoidosis. *Am J Respir Cell Mol Biol* 2001;25(3):272-277.
21. Grunewald J, Brynedal B, Darlington P, Nisell M, Cederlund K, Hillert J, Eklund A. Different HLA-DRB1 allele distributions in distinct clinical subgroups of sarcoidosis patients. *Respir Res* 2010;11:25.
22. Rossman MD, Thompson B, Frederick M, Maliarik M, Iannuzzi MC, Rybicki BA, Pandey JP, Newman LS, Magira E, Beznik-Cizman B, Monos D. HLA-DRB1*1101: A significant risk factor for sarcoidosis in blacks and whites. *Am J Hum Genet* 2003;73(4):720-735.
23. Sato H, Woodhead FA, Ahmad T, Grutters JC, Spagnolo P, van den Bosch JMM, Maier LA, Newman LS, Nagai S, Izumi T, Wells AU, du Bois RM, Welsh KI. Sarcoidosis HLA class II genotyping distinguishes differences of clinical phenotype across ethnic groups. *Hum Mol Genet* 2010;19(20):4100-4111.
24. Hattori N, Niimi T, Sato S, Achiwa H, Maeda H, Oguri T, Bessho Y, Ito H, Shimizu S, Ueda R. Cytotoxic T-lymphocyte antigen 4 gene polymorphisms in sarcoidosis patients. *Sarcoidosis Vasc Diffuse Lung Dis* 2005;22(1):27-32.
25. Spagnolo P, Renzoni EA, Wells AU, Copley SJ, Desai SR, Sato H, Grutters JC, Abdallah A, Taegtmeyer A, du Bois RM, Welsh KI. C-C chemokine receptor 5 gene variants in relation to lung disease in sarcoidosis. *Am J Resp Crit Care Med* 2005;172(6):721-728.
26. Sato H, Williams HRT, Spagnolo P, Abdallah A, Ahmad T, Orchard TR, Copley SJ, Desai SR, Wells AU, du Bois RM, Welsh K I. CARD15/NOD2 polymorphisms are associated with severe pulmonary sarcoidosis. *Eur Respir J* 2010;35(2):324-330.

27. Fischer A, Nothnagel M, Franke A, Jacobs G, Saadati HR, Gaede KI, Rosenstiel P, Schürmann M, Müller-Quernheim J, Schreiber S, Hofmann S. Association of inflammatory bowel disease risk loci with sarcoidosis, and its acute and chronic subphenotypes. *Eur Respir J* 2011;37(3):610-616.
28. Grunewald J, Eklund A, Olerup O. Human leukocyte antigen class I alleles and the disease course in sarcoidosis patients. *Am J Respir Crit Care Med* 2004;169(6):696-702.
29. Ohara K, Okubo A, Sasaki H, Kamata K. Intraocular Manifestations of Systemic Sarcoidosis. *Jpn J Ophthalmol* 1992;36(4):452-457.
30. Evans M, Sharma O, LaBree L, Smith RE, Rao NA. Differences in clinical findings between Caucasians and African Americans with biopsy-proven sarcoidosis. *Ophthalmology* 2007;114(2):325-333.
31. Baughman R, Costabel U, du Bois R. Treatment of Sarcoidosis. *Clin Chest Med* 2008;29(3):533-548.
32. Pietinalho A, Ohmichi M, Hirasawa M, Hiraga Y, Lofroos AB, Selroos O. Familial sarcoidosis in Finland and Hokkaido, Japan - a comparative study. *Respir Med* 1999;93(6):408-412.