

CASE FOR DIAGNOSIS

Cough, chest pain and haemoptysis in a young nurse

A.F. Mobeireek

Case report

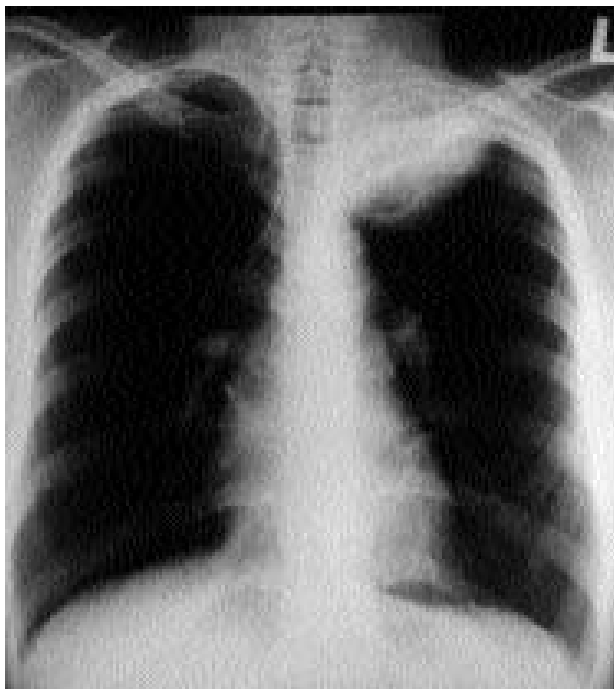A 26 year old female nurse, of East African origin, presented with a 4 month history of intermittent cough, left-sided chest pain in the upper region, and mild haemoptysis for 2 days prior to admission. She gave a history of low grade intermittent fever and night sweats, and weight loss of about 3 kg over the previous 4 months, but denied anorexia. She had a long-standing history of intermittent breathlessness, cough, wheeze, runny nose and sneezing related to smells dating back to childhood. She was diagnosed to have mild asthma and allergic rhinitis, and responded to treatment with inhaled salbutamol and intranasal steroid sprays. She was, otherwise in excellent health, and was never admitted to hospital. She admitted possible contact with tuberculous patients 1 year earlier, when she was training as a student nurse at a chest hospital. She was a nonsmoker. Her family history was unremarkable.

Physical examination revealed a well-built female with normal vital signs. The examination was unremarkable except for some dullness over the left apex.

Investigations showed a white blood cell (WBC) count of 4.63×10^9 cells·L⁻¹ (differential: neutrophils 59%, lymphocytes 33%, eosinophils 6%). Spirometry showed a forced expiratory volume in one second (FEV₁) of 2.68 L (103% predicted) and forced vital capacity (FVC) of 3.03 L (110% predicted). Sputum was negative for acid-fast organisms. Tuberculin skin test (5 units) was strongly positive (30 mm). Serum immunoglobulin E (IgE) was 341 IU·mL⁻¹. Other immunoglobulins were within the normal range. Standard skin-prick tests revealed mild-to-moderate skin reactions (3–5 mm) to house dust mite, cat, moulds, *Aspergillus clavatus* and *repens*, Mucor and some pollens.

The chest radiographic images are shown in figure 1. Fine needle aspiration of the visible mass revealed many giant cells, epitheloid cells and polymorphs, in keeping

a)

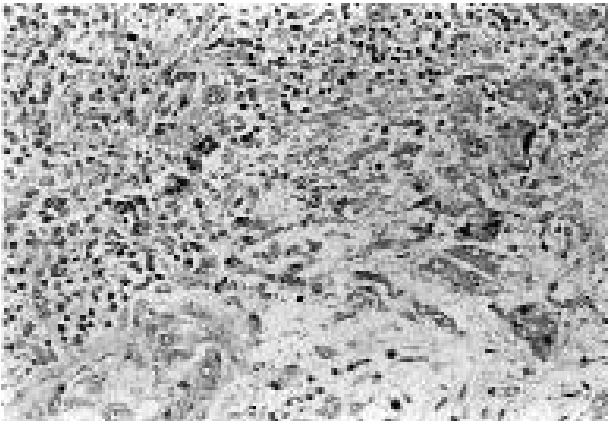


b)

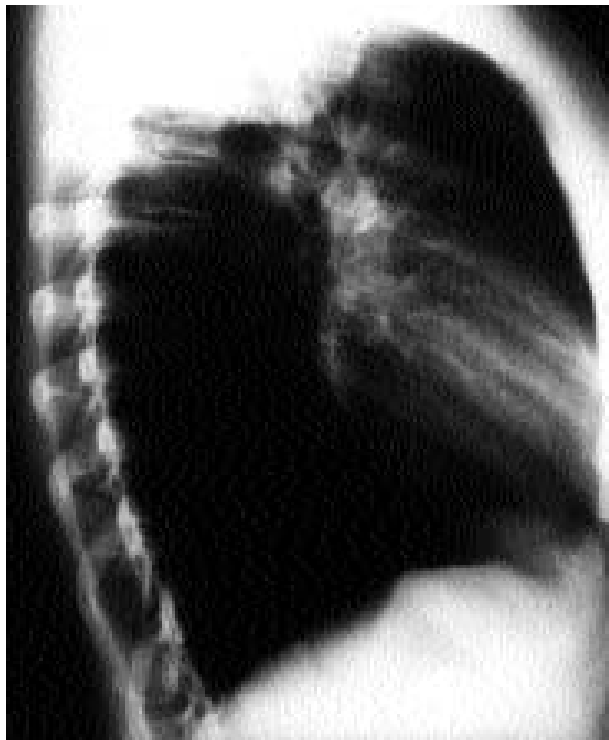

Fig. 1. – Chest radiograph. a) frontal; and b) lateral.

a)



b)

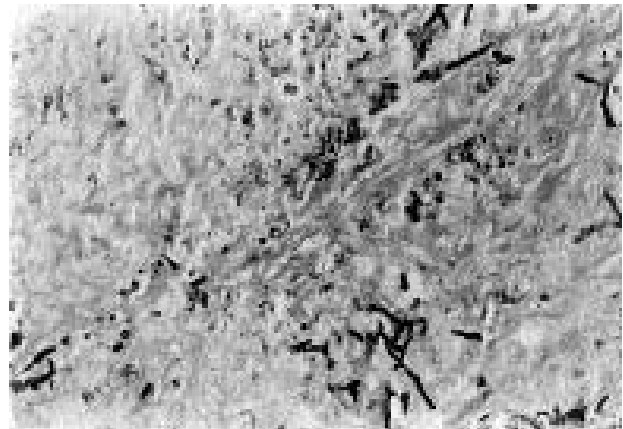


Fig. 2. – Microscopic view of the tumour: a) haematoxylin and eosin stain; and b) Grocott's stain. (Original magnification $\times 100$).

with granulomatous inflammation. Acid-fast stain and fungal smear were negative and no malignant cells were seen.

A provisional diagnosis of tuberculosis was made and the patient was started on a four anti-tuberculosis drug trial. Three months later, there were no clinical or radiological

changes and she underwent thoractomy. A tumour was found, which was adherent to the chest wall and infiltrating the apex of the lung, T₁ and T₂ roots, the sympathetic plexus and the first two intercostal spaces. The mass was resected, and histopathological examination is presented in figure 2.

BEFORE TURNING THE PAGE: INTERPRET THE CHEST RADIOGRAPH AND BIOPSY SPECIMEN AND SUGGEST A DIAGNOSIS

Interpretation of chest radiograph

The frontal chest radiograph (fig. 1a) shows a well-circumscribed oval mass in the left apical region. There was no evidence of calcification, cavitation, or erosion of the ribs or adjoining vertebral bodies. The lateral image (fig. 1b) shows a posterior location of the mass.

Interpretation of the specimen

Histopathological examination (fig. 2a) shows lung parenchyma effaced by acute and granulomatous inflammation admixed with neutrophilic infiltrate. Van Gieson's stain did not show any bronchioles. Grocott's stain (fig. 2b) shows *Aspergillus* hyphae.

DIAGNOSIS: "Fungal granuloma" (*Aspergillus flavus*)

Clinical course

The patient's postoperative recovery was uneventful. Antifungal therapy was not given because the mass was removed almost completely. She was kept under close follow-up for the following 2 years without relapse or occurrence of any unusual infections. Further tests for phagocyte function by chemiluminescence and nitroblue tetrazolium (NBT) slide test failed to show evidence of chronic granulomatous disease. Serology for human immunodeficiency virus (HIV) was also negative.

Discussion

Pulmonary aspergillosis continues to be a fascinating topic to clinicians of different specialities, in terms of the complex pathogenic mechanisms and the protean clinical manifestations. These range from immune-mediated (such as, allergic bronchopulmonary aspergillosis (ABPA) and hypersensitivity pneumonitis), infectious (acute and chronic forms) to symbiotic (aspergilloma). The list, however, goes beyond such simple classification to include many other unusual entities, for example, bronchocentric granulomatosis (BCG) [1], bronchiolitis obliterans [2], and an overlap of some of these conditions [3].

This patient presented with a lung mass, which pathologically appeared to be an *Aspergillus* granuloma (fig. 2). Although fungal granulomas in the lung secondary to *Histoplasma*, *Coccidioides* and *Blastomyces* are well-known [4], *Aspergillus*, has rarely been implicated. Pulmonary infection with chest wall involvement by aspergillosis is unusual in the immunocompetent host and has been reported only in association with chronic granulomatous disease [5, 6] and previous tuberculosis [7]. The former was excluded in our patient by appropriate tests. It is conceivable, however, in view of her strongly positive tuberculin test that the disease started in an area damaged by tuberculous infection.

Aspergillus organisms have been associated with BCG in asthmatic patients [1]. A careful pathological examination showed no evidence of bronchocentric location, proximity to a pulmonary artery or tissue eosinophilia, essential features for this diagnosis. In addition, the patient had some criteria of ABPA, including asthma, positive skin-prick test, precipitins and a low titre of specific IgE for *Aspergillus*. Nonetheless, these were insufficient to make such a diagnosis [1].

Different species of *aspergillus* may predominate as pathogens, depending on the climatic and geographic factors [4, 8]. In this patient, of East African origin, *Aspergillus flavus* was isolated. This organism was shown to be one of the main pathogens responsible for pulmonary aspergillosis in that area [9]. A paranasal form also occurs mainly in Africa, and is again related to the same fungus [10].

In summary, this case illustrates an unusual manifestation of pulmonary aspergillosis. The diversity of pulmonary pathology caused by *Aspergillus* spp. makes it necessary to consider aspergillosis in patients with respiratory symptoms, particularly asthmatics.

Keywords: *Aspergillus flavus*, pulmonary granuloma.

Acknowledgements: The author is grateful to M. Al-Sohaibani for assistance in presenting the histopathology, and A. Al-Tweajri and R. Soliman for performing the chemiluminescence and NBT tests.

References

1. Sulavic SB. Bronchocentric granulomatosis and allergic bronchopulmonary aspergillosis. *Clin Chest Med* 1988; 9: 609–621.
2. Sieber SC, Cole SR, McNap JM, Shore R. Bronchiolitis associated with the finding of the fungus *aspergillus*: report of two cases. *Conn Med* 1994; 58: 13–17.
3. Katzenstein AL, Liebow AA, Friedman PJ. Bronchocentric granulomatosis, mucoid impaction and hypersensitivity reactions to fungi. *Am Rev Respir Dis* 1975; 111: 497–537.
4. Fraser RG, Pare JAP, Pare PD, Fraser RS, Genereux GP. Diagnosis of diseases of the chest. 3rd edn. Volume II. Mycotic and actinomycotic pleuropulmonary infection. Philadelphia, W.B. Saunders, 1989; p.940.
5. Kwon-Chung KJ, Bennett JE. Medical mycology: aspergillosis. Philadelphia, Lea & Febiger, 1992; p.201.
6. Atman AR. Thoracic wall invasion secondary to pulmonary aspergillosis: a complication of chronic granulomatous disease of childhood. *AJR* 1977; 129: 140–142.
7. Hillerdal G. Pulmonary *aspergillus* infection invading the pleura. *Thorax* 1981; 36: 745–751.
8. Laham MN, Jeffery B, Carpenter JL. Frequency of clinical isolation and winter prevalence of different *Aspergillus* species at a large South Western Army Medical Center. *Ann Allergy* 1982; 48: 215–219.
9. Mahgoub ES, El-Hassan AM. Pulmonary aspergillosis caused by *Aspergillus flavus*. *Thorax* 1972; 27: 33–37.
10. Gumaa SA, Mahgoub ES, Hay RJ. Postoperative response of paranasal *Aspergillus* granuloma to itraconazole. *Trans R Soc Trop Med Hyg* 1992; 86: 93–94.