

## CASE STUDY

# Exogenous lipid pneumonia complicated by *Mycobacterium fortuitum* and *Aspergillus fumigatus* infections

I. Jouannic\*, B. Desrues\*, H. Léna\*, M.L. Quinquenel\*,  
P.Y. Donnio\*\*, Ph. Delaval\*

*Exogenous lipid pneumonia complicated by Mycobacterium fortuitum and Aspergillus fumigatus infections. I. Jouannic, B. Desrues, H. Léna, M.L. Quinquenel, P.Y. Donnio, Ph. Delaval. ©ERS Journals Ltd 1996.*

**ABSTRACT:** We report the case of a nonimmunocompromised female patient, who developed exogenous lipid pneumonia with *Mycobacterium fortuitum* infection at diagnosis, later followed by *Aspergillus fumigatus* infection.

The association of exogenous lipid pneumonia with atypical mycobacterial infection is uncommon but well-recognized, but, to our knowledge, association with *A. fumigatus* infection has not previously been reported.

*Eur Respir J., 1996, 9, 172-174.*

\*Service de Pneumologie, \*\*Laboratoire de Bactériologie-Virologie, Hôpital Pontchaillou, Centre Hospitalier Régional et Universitaire, Rennes, France.

Correspondence: Ph. Delaval, Service de Pneumologie, Hôpital Pontchaillou, CHRU, 35 033 Rennes Cedex, France

Keywords: *Aspergillus fumigatus*, lipid pneumonia, *Mycobacterium fortuitum*

Received: April 28 1995

Accepted after revision August 30 1995

## Case report

A 56 year old woman, with a history of cholecystectomy, excision of a nasal melanocytic hyperplasia and chronic depression, was admitted following chest pains and episodes of fever in June 1989. She was a non-smoker. Her usual medication included antidepressant drugs: alprazolam, meprobamate-aceprometazine and tianeptine. Since 1988, she had complained of cough initially dry, which progressively worsened, producing whitish or purulent expectorations. Her general health status declined and exertional dyspnoea developed. On questioning, she mentioned a long-standing, 10 year, daily ingestion of several glassfuls of liquid paraffin for chronic constipation.

Her temperature was 36.7°C, pulse 76 beats·min<sup>-1</sup>, blood pressure 160/90 mmHg and respiratory rate 20 breaths·min<sup>-1</sup>. There were rales and crepitations at the left posterior base. Results of cardiac and abdominal examination were unremarkable. Laboratory investigation revealed a white blood cell (WBC) count of 17.1×10<sup>9</sup>·L<sup>-1</sup>; and the erythrocyte sedimentation rate was 125 mm. Arterial blood gas analysis with the patient breathing room air showed a pH of 7.45, an arterial carbon dioxide tension (P<sub>a</sub>CO<sub>2</sub>) of 5.5 kPa and an arterial oxygen tension (P<sub>a</sub>O<sub>2</sub>) of 8.3 kPa. Chest radiography revealed bilateral heterogeneous opacities involving the right upper, middle and lower lobes and the left lower lobe (fig. 1). Computed tomographic (CT) scan showed multiple alveolar opacities and condensation of the left lower lobe (fig. 2).

Chronic liquid paraffin ingestion suggested the diagnosis of exogenous lipid pneumonia, which was confirmed by bronchoalveolar lavage (BAL). Oil red O colouration was positive and the analysis of BAL fluid

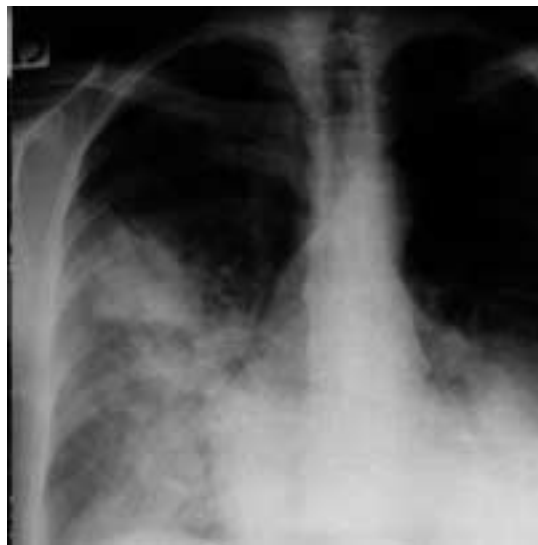

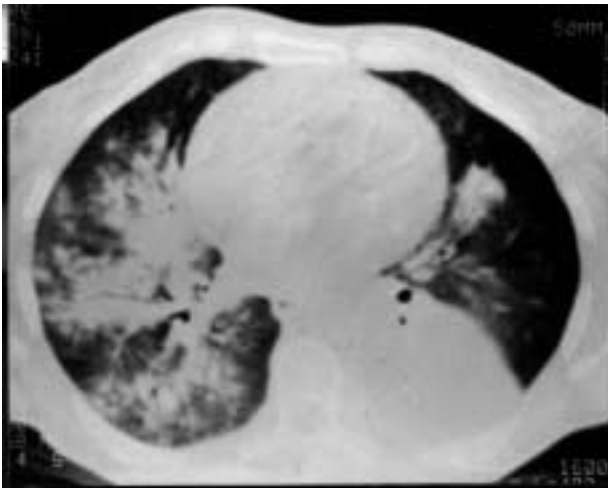
Fig. 1. - Bilateral opacities involving the right upper, middle and lower lobes and the left lower lobe.

by infra-red spectrophotometry identified an aliphatic carbohydrate with the same spectrum as liquid paraffin.

Microbiological studies identified acid-fast bacilli in sputum, gastric aspiration products and BAL fluid. Cultures grew quickly, within 1 week, on 12 successive samples, with identification of *Mycobacterium fortuitum*.

Treatment consisted in discontinuation of use of the oil and, after an initial period with an antituberculosis medication regimen, an association of ciprofloxacin-minocycline was prescribed for 3 months according to the susceptibility testing. Purulent expectorations disappeared and the patient gained 10 kg in 6 months. Bacteriological examinations of the sputum became negative, but the radiographic images remained unchanged.

a)



b)

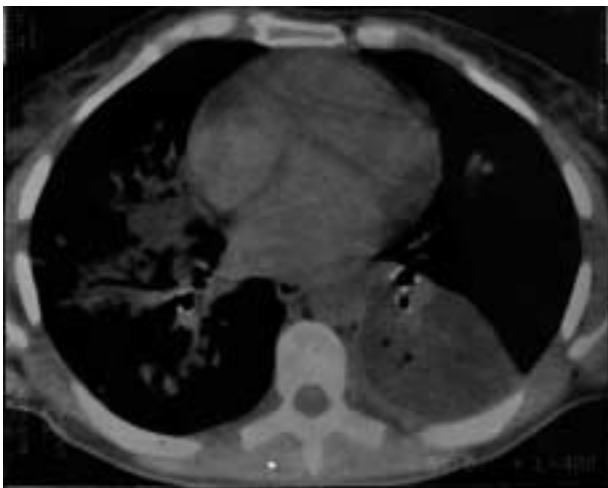


Fig. 2. – Alveolar opacities with an alveologram and condensation of the left lower lobe. a) parenchymal window; b) mediastinal window.

One year later, the clinical situation again deteriorated, with weight loss and vomiting. The chest radiograph showed an air fluid level demonstrating an abscess in the left lower lobe. The CT scan revealed multiple cavities (fig. 3). BAL was performed, but was negative for acid-fast bacilli at direct examination and after culture. However, there were several mycelia, and culture led to the identification of *Aspergillus fumigatus*. The deterioration of the clinical situation, together with radiographic and tomographic evidence of continuing disease plus a highly positive aspergillus serology with four arcs of precipitation, led to treatment with intravenous amphotericin B. The daily dose was  $1 \text{ mg} \cdot \text{kg}^{-1}$  to a total dose of 1.5 g. The patient improved rapidly and regained weight. The initial inflammatory syndrome regressed. The aspergillus serology was not controlled at the end of the treatment. The chest radiograph remained unchanged. Four years later, the clinical situation is satisfactory; although no improvement in the radiological images has been observed.

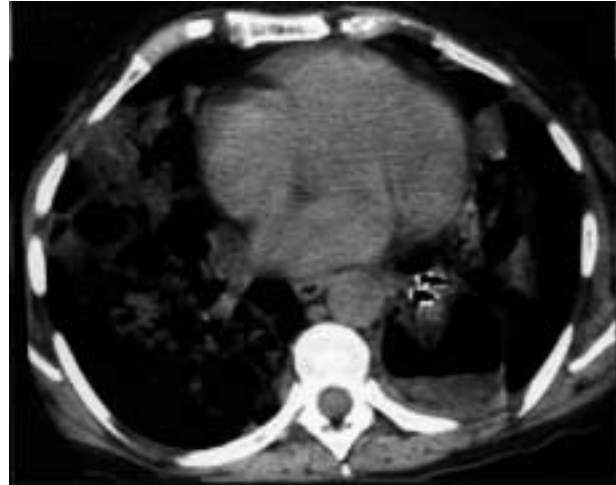


Fig. 3. – Multiple bilateral cavities on the computed tomographic (CT) scan with an air fluid level in the left lower lobe.

### Discussion

Exogenous lipid pneumonia generally results from chronic aspiration of oily substances, which is usually encountered in two situations: ingestion of paraffin for chronic constipation and use of oily nasal preparations for rhinopharyngeal obstruction. These oily substances are mineral oils and are not cleared by the lungs. They inhibit the cough reflex and motor function of ciliated mucosa [1]. Biochemical analysis of the BAL fluid easily confirmed the diagnosis by the staining reactions for fat and by infra-red spectrophotometry [2]. Long-term outcome cannot be readily predicted but chronic respiratory failure is not uncommon [1].

Cases associating exogenous oil aspiration pneumonia and infection with atypical mycobacteria are known, but rare, 11 cases being reported in the literature. In all the reported cases, the atypical Mycobacterium was considered to be the pathogenic agent. In seven of these case reports, *M. fortuitum* was identified [3–9], and *M. smegmatis* in one [10]. In the three remaining cases, bacterial identification at the species level was not reported probably due to the lack of microbiological techniques available at the time of these publications [6, 11, 12].

Lipids would have an effect on the pathogenicity of mycobacteria through a poorly understood mechanism. According to some authors, lipids play a role as a mechanical protector for the mycobacteria [6], while for others, a high concentration of free fatty acids would be a factor favouring necrotizing haemorrhagic pneumonia with secondary superinfection [13].

To our knowledge, an association between oil aspiration pneumonia and *A. fumigatus* has never been described. Based on clinical, morphological, bacteriological and serological evidence and due to the lack of any other identifiable cause, *A. fumigatus* was considered to be the causative agent in the necrotizing pneumonia observed in this case. The favourable clinical course after treatment with amphotericin B, with weight gain and disappearance of fever, would give proof of the diagnosis. A surgical biopsy specimen, to confirm the diagnosis, was

not performed because of the well-known risk of severe haemorrhage in previously identified lipid pneumonia [14].

In conclusion, few cases associating lipid pneumonia and superinfection with *M. fortuitum* have been reported. This association should, however, be carefully investigated since lipid pneumonia may favour the development of atypical mycobacteria. For *Aspergillus*, no former report has been found but we may question the role of lipids in the pathogenicity of *A. fumigatus*.

#### References

- Dongay G, Levade T. Etude biochimique et cytologique du liquide de lavage alvéolaire dans 4 cas de pneumopathies huileuses. *Presse Méd* 1986; 15: 1863–1866.
- Levade T, Salvayre R. Chemical analysis of the bronchoalveolar washing fluid in the diagnosis of lipid pneumonia. *J Clin Chem Biochem* 1987; 25: 46–48.
- Banzerjee R, Hall R, Hugues GRV. Pulmonary *Mycobacterium fortuitum* infection in association with achalasia of the oesophagus. *Br J Dis Chest* 1970; 64: 112–118.
- Dixon C, Bolivar R, Katz R. Lipoid pneumonia and *Mycobacterium fortuitum* pulmonary infection: successful treatment with sulfisoxazole. *Texas Med* 1985; 8: 57–60.
- Dreisin RB, Scoggin C, Davidson PT. The pathogenicity of *Mycobacterium fortuitum* and *M. chelonae* in man: a report of seven cases. *Tubercle* 1976; 57: 49–57.
- Hutchins GN, Boitnott JK. Atypical mycobacterial infection complicating mineral oil pneumonia. *J Am Med Assoc* 1978; 240: 539–541.
- Patri B, Tenaillon A, Jaqueson A. Insuffisance respiratoire aiguë au cours d'une pneumopathie huileuse diffuse. *Ann Méd Interne* 1978; 129: 543–546.
- Varghese G, Shepard R, Watt D, Bruce JH. Fatal infection with *Mycobacterium fortuitum* associated with oesophageal achalasia. *Thorax* 1988; 43: 151–152.
- Vincent M, Chambon M, Fougerat J. Pneumonie lipidique et surinfection par *Mycobacterium fortuitum*. *Rev Mal Respir* 1987; 4: 335–338.
- Vonmoos S, Leuenberger P, Beer V, De Haller R. Pleuropneumopathy infection caused by *Mycobacterium smegmatis*: case description and literature review. *Schweiz Med Wschr* 1986; 116: 1852–1856.
- Gibson JB. Infection of the lungs by saprophytic mycobacteria in achalasia of the cardia with report of fatal case showing lipid pneumonia due to milk. *J Path Bact* 1953; 65: 239.
- Guest JL Jr, Areal VM. Groupe IV atypical *Mycobacterium* infection occurring in association with mineral oil granuloma of lungs. *Am Rev Respir Dis* 1967; 95: 656–662.
- Kennedy JP, Costello P, Balikian JP. Exogenous lipid pneumonia. *Am J Roentgenol* 1981; 136: 1145–1149.
- Even R, Vibert J, Sors Ch. Les hémorragies foudroyantes au cours des pneumopathies huileuses. *J Fr Méd Chir Thorac* 1957; 11: 681–692.