

Respiratory muscle activity and oxygenation during sleep in patients with muscle weakness

J.E.S. White*, M.J. Drinnan**, A.J. Smithson**, C.J. Griffiths**, G.J. Gibson*

Respiratory muscle activity and oxygenation during sleep in patients with muscle weakness. J.E.S. White, M.J. Drinnan, A.J. Smithson, C.J. Griffiths, G.J. Gibson. ©ERS Journals Ltd 1995.

ABSTRACT: Patients with respiratory muscle weakness show nocturnal hypoventilation, with oxygen desaturation particularly during rapid eye movement (REM) sleep, but evidence in individuals with isolated bilateral diaphragmatic paresis (BDP) is conflicting. The effect of sleep on relative activity of the different respiratory muscles of such patients and, consequently, the precise mechanisms causing desaturation have not been clarified.

We have studied eight patients, four with generalized muscle weakness and four with isolated BDP during nocturnal sleep with measurements including oxygen saturation and surface electromyographic (EMG) activity of various respiratory muscle groups.

Nocturnal oxygenation correlated inversely with postural fall in vital capacity, an index of diaphragmatic strength. During REM sleep, hypopnoea and desaturation occurred particularly during periods of rapid eye movements (phasic REM sleep). In most subjects, such events were "central" in type and associated with marked suppression of intercostal muscle activity, but two subjects had recurrent desaturation due to "obstructive" hypopnoea and/or apnoea. Expiratory activity of the external oblique muscle was present whilst awake and during non-rapid eye movement (NREM) sleep in seven of the eight subjects in the semirecumbent posture. This probably represents an "accessory inspiratory" effect, which aids passive caudal diaphragmatic motion as the abdominal muscles relax at the onset of inspiration. Expiratory abdominal muscle activity was suppressed in phasic REM sleep, suggesting that loss of this "accessory inspiratory" effect may contribute to "central" hypopnoea.

We conclude that, in patients with muscle weakness, nocturnal oxygenation correlates with diaphragmatic strength. During sleep, episodes of oxygen desaturation are predominantly due to reduced muscle activity in association with eye movements during REM sleep resulting in central hypopnoea, though obstructive events may also occur.

Eur Respir J., 1995, 8, 807-814.

It is well recognized that patients with respiratory muscle weakness are at risk of hypoxaemia and hypercapnia during sleep, especially rapid eye movement (REM) sleep [1, 2]. The likely mechanism is the normal reduction in respiratory drive associated with sleep acting on muscles with reduced capacity due to disease. Data in normal subjects during REM sleep suggest differential suppression of various muscle groups, with relative preservation of activity of the diaphragm [3-5]. It might, therefore, be expected that patients with the most severely impaired diaphragmatic function would be the most vulnerable during REM sleep. LAROCHE *et al.* [6] studied patients with isolated bilateral diaphragmatic paresis (BDP) and suggested that this was not the case, and that significant nocturnal hypoxaemia was seen only in the presence of generalized respiratory muscle weakness.

Hypopnoea and desaturation might also result if the

Depts of *Respiratory Medicine and **Medical Physics, Freeman Hospital, Newcastle-upon-Tyne, UK.

Correspondence: J.E.S. White
Dept of Respiratory Medicine
Freeman Hospital
Newcastle-upon-Tyne
NE7 7DN
UK

Keywords: Apnoea
diaphragmatic paralysis
muscle weakness
oxygenation
sleep

Received: April 11 1994

Accepted after revision January 17 1995

activity of the upper airway muscles were disproportionately suppressed, leading to narrowing or occlusion of the upper airway. In a recent study of patients with Duchenne's muscular dystrophy, it was inferred that apnoeas were predominantly obstructive [7]. Furthermore, the frequency of obstructive apnoea or hypopnoea in patients with muscle weakness may be underestimated if reliance is placed on conventional sleep measurements, such as chest wall motion [8].

In awake subjects with severe weakness or paralysis of the diaphragm, the abdominal muscles may have an important role as accessory inspiratory muscles [9], but such an effect is dependent on gravity and it is not known whether it is relevant during sleep.

We have, therefore, performed detailed investigation of respiratory muscle activity during REM and non-rapid eye movement (NREM) sleep in patients with either

generalized muscle weakness or isolated BDP, in order to assess the contribution of the different muscle groups to hypopnoea (hypoventilation) and consequent hypoxaemia. In particular, we have concentrated on: 1) the comparative severity of hypoxaemia associated with generalized weakness and BDP alone; 2) the respective contributions of "obstructive" and "central" hypopnoea and their mechanisms; 3) the activity of the abdominal muscles as possible accessory inspiratory muscles during sleep.

Subjects and methods

Eight subjects were studied, four (Nos. 1–4) had generalized muscle disease and four (Nos. 5–8) had isolated BDP with normal maximal expiratory pressures measured at the mouth and no evidence of weakness of other skeletal muscles. Their diagnoses, characteristics and pulmonary function are shown in table 1. All except one (No. 1) showed paradoxical abdominal motion in the posteroanterior dimension both awake and asleep when semi-recumbent. No subject was taking any drugs which might have affected respiration. Subjects were recruited to the study on the basis of willingness to participate and absence of significant airway obstruction (forced expiratory volume in one second/vital capacity (FEV₁/VC) $\geq 60\%$). Neither the presence nor absence of sleep related symptoms was a criterion for selection. All participants gave informed consent prior to participation in the study, which was approved by the local Ethics Committee.

All subjects had standard polysomnographic signals recorded overnight in hospital following one acclimatization night. Arterial oxygen saturation (Sa_{o₂}) was recorded by a pulse oximeter using a finger probe (Biox 3700e, Ohmeda, Louisville, USA), airflow by thermistors at the mouth and nose (Oxford Medical, Oxford, UK). Postero-anterior ribcage (RCPA) and posteroanterior abdominal (ABPA) motion were recorded using linearized magnetometers [10]. A single channel electroencephalogram (EEG) C_z/O_z was recorded, and an electro-oculogram

(EOG) from left and right eyes arranged as a single channel, as previously validated [11], to allow sleep staging. In addition, for the purpose of the present study, surface electromyographic (EMG) activity was recorded from selected respiratory muscles, using 10 mm silver/silver chloride cup electrodes (SLE, Croydon, Surrey, UK) applied to carefully cleaned and abraded skin with an impedance less than 1 k Ω . Pairs of electrodes were placed at least 2 cm apart over the five muscle groups studied. The muscles sampled were those of the upper airway ("genioglossus group", EMG_{ge}), placed 1 cm lateral to the midline midway between the chin and the hyoid bone; parasternal intercostal (EMG_{int}), lateral to the sternum in the second intercostal space; diaphragm (EMG_{di}), in the seventh or eighth intercostal space in the anterior axillary line, on the right to reduce cardiac artefact; rectus abdominis (EMG_{ra}) 2 cm lateral to the umbilicus; and external oblique (EMG_{exob}), midway between the inferior costal margin and the iliac crest in the midclavicular line. Signals were passed through preamplifiers and amplifiers, filtered 40–1,000 Hz, rectified and smoothed using a first order low-pass filter with a time constant of 50 ms. Both processed and raw EMG were recorded onto digital tape (EDR 128, Earthdata, Southampton, UK). Posture was recorded by viewing the subject with a low light camera (Panasonic, Japan) under infra-red illumination and recording onto 3 h VHS tape using a videorecorder (NV-G18 Panasonic, Japan) running at half standard speed, to give a study time of 6 h. [12]. Synchronization of the digital and videotape recorders was achieved by using a clock in view of the camera. Each subject slept in his or her preferred position, which in every case was semirecumbent.

Epochs of wakefulness, NREM and REM sleep, as assessed by standard criteria after RECHTSCHAFFEN and KALES [13], were identified from a hard copy of the whole study replayed on a chart recorder (TA4000 Gould, Ilford, UK). REM sleep was further divided into phasic REM sleep (pREM) or tonic REM sleep (tREM) depending on the presence or absence of eye movements. Sections of recordings of stable signal quality with the subject

Table 1. – Subject characteristics

Sub. No.	Sex	Age yrs	Diagnosis	BMI kg·m ⁻²	FEV ₁ % pred	VC erect % pred	Δ VC %	FRC % pred	P _{di,sniff} cmH ₂ O	P _{i,max} cmH ₂ O	P _{e,max} cmH ₂ O	Awake* Sa _{o₂}
1	F	36	Mitochondrial myopathy	32.0	62	61	12	92	39	-17	32	98
2	F	53	Unclassified myopathy	41.3	86	61	49	124	9	-36	74	94
3	M	44	Acid maltase deficiency	34.5	52	49	71	94	22	-30	74	91
4	M	68	Unclassified myopathy	23.6	61	51	40	95	-	-82	67	96
5	M	71	Idiopathic BDP	26.6	54	61	39	108	7	-18	75	97
6	M	57	Idiopathic BDP	26.2	50	63	47	139	16	-35	80	97
7	M	51	BDP in association with diabetes mellitus	32.6	63	61	83	54	5	-78	124	94
8	M	63	BDP post-cardiac surgery	36.6	41	51	81	149	8	-16	132	85
Mean (sd)		55 (12)		31.7 (6)	58 (13)	57 (6)	53 (24)	107 (30)	15 (12)	-39 (26)	82 (32)	94

Sub: subject; M: male; F: female; BDP: bilateral diaphragmatic paresis. BMI: body mass index (weight/height²); FEV₁: forced expiratory volume in one second; VC: vital capacity; Δ VC: percentage fall in VC from erect to supine; FRC: functional residual capacity; P_{i,max}: maximal inspiratory pressure measured at the mouth at FRC; P_{e,max}: maximal expiratory pressure measured at the mouth at total lung capacity (TLC); P_{di,sniff}: maximal transdiaphragmatic pressure during a maximal sniff from FRC. *: in sleeping (semi-recumbent) posture.

in the constant preferred posture were transferred to a personal computer using an analogue to digital converter (Dash-16, Metrabyte, Taunton, MA, USA). A total of 28 periods of NREM and 16 periods of REM sleep (ranges 3–6 and 1–5 per subject, respectively) were captured from the six subjects who had at least one epoch of REM sleep. These periods included mean (SD) numbers of 65 (15) and 73 (20) breaths, respectively. Analysis of EMG activity was performed using a specifically developed software package which calculated the peak level of EMG activity for each muscle for each breath, and for the captured section as a whole. Results were expressed as ratios between sleep stages.

Apnoea was defined as cessation of airflow and hypopnoea as a reduction in ribcage excursion of at least 50%, both for at least 10 s. Events were further classified as "central" if there was either an absence of, or an overall reduction in, inspiratory muscle activity and "obstructive" if the event was accompanied by persisting or increasing muscle activity with, at termination, a large burst of activity in EMG_{ge}, all in the presence of snoring. Since in most cases posteroanterior ribcage and abdominal motion was continually out of phase due to diaphragmatic weakness, this conventional criterion for the development of upper airway obstruction could not be used. An episode of desaturation was defined as a fall in Sa_{o2} of at least 4%.

Statistical comparisons of the changes in magnitude of EMG between sleep stages were performed by paired t-test after logarithmic transformation of the ratio of activity during pREM and NREM sleep.

Results

Sleep

The duration and quality of sleep varied considerably between individuals. Subjects Nos 1 and 4 had no REM sleep. Three subjects (Nos. 4, 5 and 8) had no slow wave (stage 3–4) sleep. Subject No. 4 slept particularly poorly, spending more than 60% of the study time awake. He had recurrent arousals related to hypopnoea, resulting in gross sleep fragmentation.

Table 2. – Oxygenation data

Subject	Total sleep time			NREM sleep			REM sleep		
	Mean Sa _{o2} %	Nadir Sa _{o2} %	Desat. rate n·h ⁻¹	Mean Sa _{o2} %	Nadir Sa _{o2} %	Desat. rate n·h ⁻¹	Mean Sa _{o2} %	Nadir Sa _{o2} %	Desat. rate n·h ⁻¹
1	97	94	0	97	94	0	-	-	-
2	93	68	13	93	85	3	91	68	41
3	87	58	15	88	86	0	83	58	36
4	93	67	21	93	67	21	-	-	-
5	95	65	16	95	66	6	95	65	139
6	96	88	7	96	90	4	93	88	17
7	90	62	15	90	89	0	84	62	31
8	72	50	21	72	62	6	67	50	58
Mean	90	69	14	91	80	7	86	65	54

Desat rate: desaturation rate; Sa_{o2}: arterial oxygen saturation; REM: rapid eye movement; NREM: non-REM.

Oxygenation

Table 2 shows oxygenation data for all the subjects for the whole study and by sleep stage. Only one subject (No. 1) had a relatively normal overnight saturation profile; it was noteworthy that she had no REM sleep. Otherwise, the nadir Sa_{o2} of the subjects was markedly reduced below normal. Recurrent desaturations were recorded in all except subject No. 1. They occurred most frequently, and generally were most severe, during REM sleep. However desaturations were also seen in NREM sleep in five subjects (Nos. 2, 4–6 and 8). In the six subjects who had at least one epoch of REM sleep, mean and nadir Sa_{o2} during REM were lower than during NREM sleep ($p < 0.02$) (table 2).

Daytime pulmonary function and nocturnal oxygenation

There was a significant negative correlation between overnight oxygenation (whether expressed as mean Sa_{o2} or nadir Sa_{o2}) and the fall in vital capacity when changing from erect to supine posture (ΔVC) (fig. 1a and b) ($r = -0.73$ and -0.78 , respectively; both $p < 0.05$). Other measures of lung volume, e.g. functional residual capacity (FRC), measurements of maximum static respiratory pressures and transdiaphragmatic pressure during a maximal sniff (P_{di,sniff}) showed no significant correlations with nocturnal oxygenation.

Muscle activity - wakefulness and NREM sleep

Phasic inspiratory activity in EMG_{ge} was seen in all subjects during sleep. During wakefulness, this was obscured in most cases by high levels of tonic activity. All subjects showed inspiratory activity in EMG_{int} during wakefulness and NREM sleep. Inspiratory activity in EMG_{di} during wakefulness and NREM sleep was recorded in four subjects (Nos. 1, 2, 5 and 6). In the others (Nos. 3, 4, 7 and 8), apparent expiratory activity was present, but since this corresponded completely in timing and pattern with activity in EMG_{exob} it was considered to be contaminant.

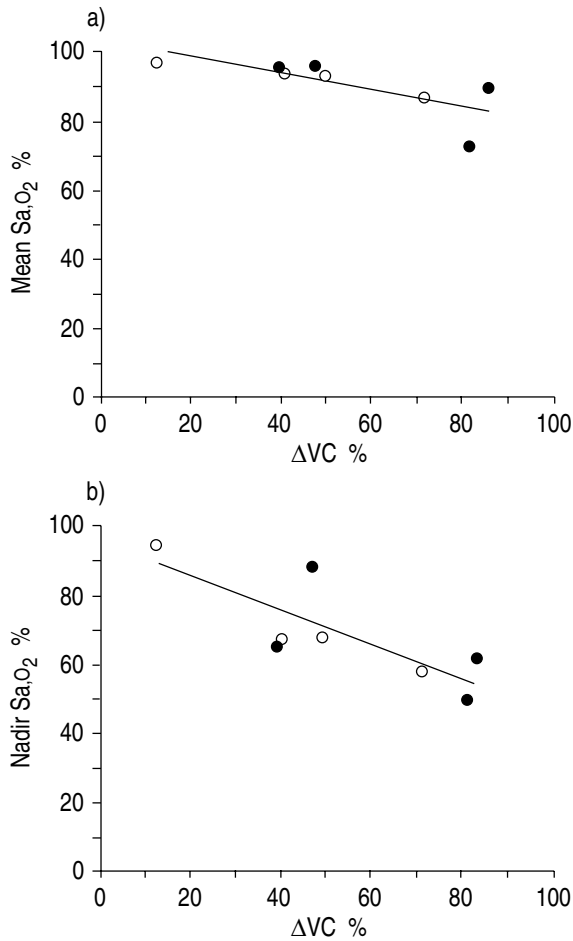


Fig. 1. – Relationship between nocturnal: a) mean oxygen saturation (mean Sa_{O_2}); and b) nadir oxygen saturation (nadir Sa_{O_2}) and fall in vital capacity on lying supine (ΔVC) for patients with isolated bilateral diaphragmatic weakness (●) and generalized respiratory muscle weakness (○). Both show a significant negative correlation ($r=-0.73$ and $r=-0.78$, respectively; both $p<0.05$).

Activity of EMG_{exob} which was always expiratory in timing, was detected in seven of the eight subjects during most of the study period whilst awake and in NREM sleep. In two of these subjects (Nos 6 and 8) expiratory activity in EMG_{exob} during NREM sleep was at times of considerable magnitude; such bursts of activity were accompanied by reduced abdominal paradox (fig. 2). No factors could be identified which were associated with these episodes of increased EMG_{exob} activity; in particular, they were not related to changes in posture. Little activity was seen in EMG_{gra} in any of the subjects; where present it was expiratory in timing and mirrored the pattern of EMG_{exob} .

Muscle activity - REM sleep

Six of the eight subjects (Nos. 2, 3 and 5–8) had at least one epoch of REM sleep. During pREM, intercostal muscle activity was significantly less than during NREM sleep ($p<0.001$) (fig. 3). Differences in genioglossus activity were more variable, with two subjects (Nos. 2 and 3) showing a small increase during pREM

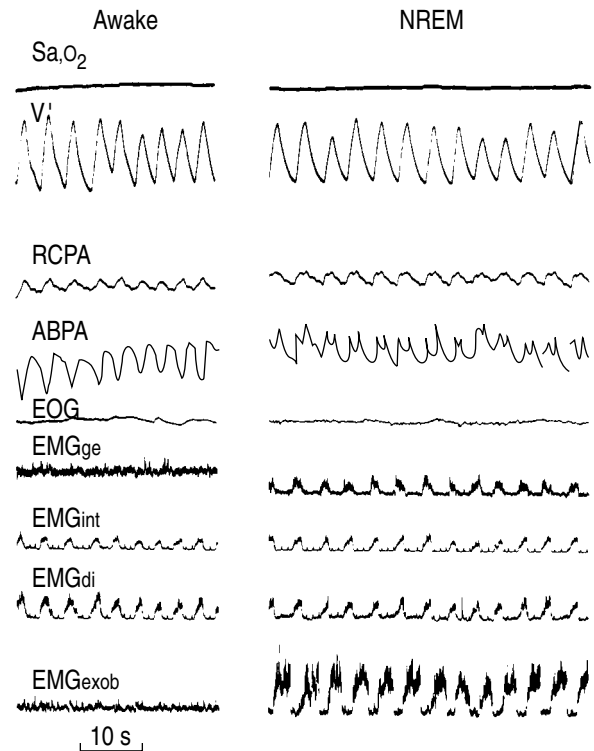


Fig. 2. – Recordings from subject No. 6 during wakefulness (left hand panel) and non-rapid eye movement (NREM) sleep (right hand panel). The recordings are in order, from the top: oxygen saturation (Sa_{O_2}); airflow (V'); posteroanterior ribcage motion (RCPA); posteroanterior abdominal motion (ABPA); electro-oculogram (EOG); genioglossus group electromyographic (EMG) activity (EMG_{ge}); intercostal EMG (EMG_{int}); diaphragmatic EMG (EMG_{di}); external oblique EMG (EMG_{exob}). Note inspiratory activity in all three muscle groups and marked expiratory activity of EMG_{exob} in NREM sleep. During wakefulness there is paradoxical abdominal motion throughout inspiration, but paradox only in late inspiration during NREM sleep.

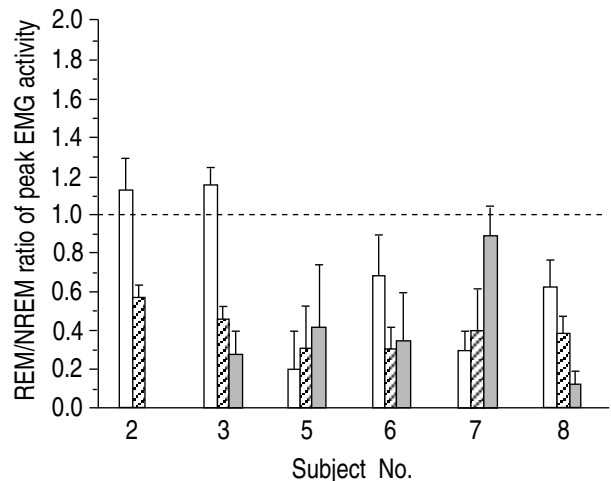


Fig. 3. – Ratios of average peak EMG activity (error bar=1 SD) during phasic REM and NREM sleep recorded from genioglossus, intercostal and external oblique muscle groups in six subjects. (Nos. 1 and 4 had no pREM sleep). Intercostal activity was significantly less in pREM than in NREM sleep ($p<0.02$). Subject No. 2 showed no activity in EMG_{exob} . REM: rapid eye movement; pREM: phasic REM; NREM: non-REM. For further abbreviations see legend to figure 2. □: genioglossus; ▨: intercostal; ■: external oblique.

Table 3. – Hypopnoeas and apnoeas

Subject No.	NREM			REM sleep		
	Central hypopnoea	Obstructive hypnoea	Obstructive apnoea	Central hypopnoea	Obstructive hypopnoea	Obstructive apnoea
1	-	-	-	-	-	-
2	-	-	-	37	-	-
3	-	-	-	45	-	-
4	160	-	-	-	-	-
5	-	27	24	3	3	21
6	-	17	3	5	-	-
7	-	-	-	22	-	-
8	-	-	-	18	-	-

REM: rapid eye movement; NREM: non-REM.

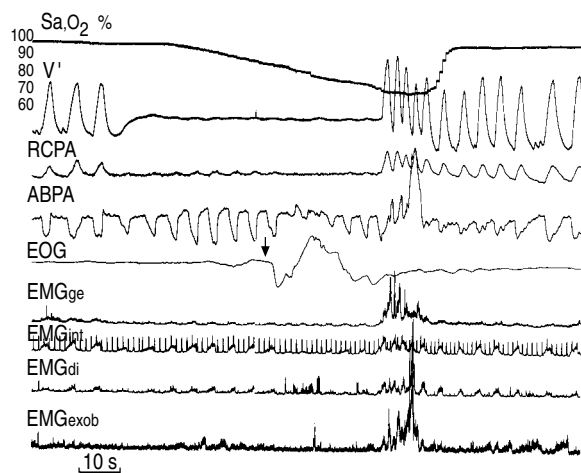


Fig. 4. – Recording from subject No. 5 during rapid eye movement (REM) sleep. Signals are detailed in legend to figure 2. Note apnoea and resulting desaturation. The event is primarily "obstructive" in type as indicated by the loss of cardiac artefact in airflow and continuing respiratory effects. At the onset of rapid eye movements (arrowed) there is a marked reduction in intercostal activity, thus adding a "central" component to the event. For abbreviations see legend to figure 2.

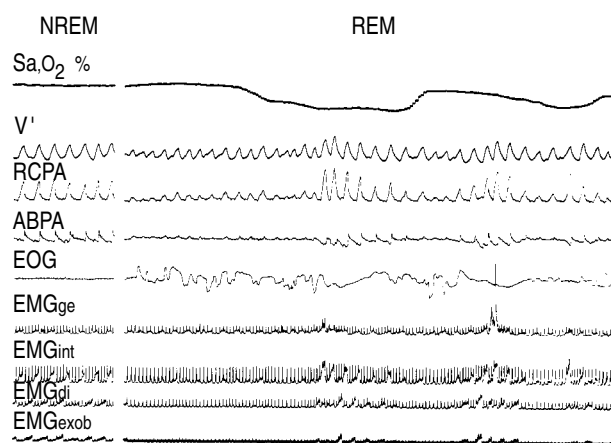


Fig. 5. – Recordings during NREM and REM sleep from subject No. 2. Signals are detailed in legend to figure 2. Note consistent expiratory activity in EMG_{exob} during NREM sleep, which, like inspiratory EMG_{int}, is suppressed in REM sleep in association with phasic eye movements. The apparent EMG_{di} activity is expiratory and is presumed to represent contamination by abdominal expiratory muscle activity, which it clearly resembles. For abbreviations see legend to figure 2.

sleep and the other subjects showing a reduction. Expiratory activity of EMG_{exob} was present both during NREM and pREM in five subjects: its magnitude was significantly less in pREM sleep ($p < 0.05$) (fig. 3). Of the three subjects (Nos. 2, 5 and 6) who showed inspiratory activity of EMG_{di} during pREM sleep, this was similar to the activity in NREM sleep in two subjects (Nos. 2 and 6) and less in the other.

Mechanisms of hypoxaemia and hypopnoea

No episodes of desaturation or periods of hypopnoea were recorded in subject No. 1. The numbers of hypopnoeas and apnoeas of different types for the other subjects are shown in table 3. Events during REM sleep were generally more prolonged and accompanied by more severe desaturation than during NREM sleep. Subject No. 4 (who had no REM sleep) showed a fall in Sa_o₂ every time he entered light sleep, due to "central" hypopnoea associated with a reduction in EMG_{int} activity, followed at termination of each event by an arousal. Two subjects (Nos. 5 and 6) had periodic desaturation during both NREM and REM sleep. During NREM sleep, the desaturations were associated with "obstructive" events, with approximately equal numbers of apnoeas and hypopnoeas in one subject (No. 5), and predominantly hypopnoeas in the other (No. 6). During REM sleep, subject No. 5 again had predominantly "obstructive" apnoeas, although the mechanism was sometimes more complex, as illustrated in figure 4 where a long obstructive apnoea encompasses a brief "central" component due to reduced intercostal muscle activity associated with phasic eye movements. During such "obstructive" events, there was an increase in abdominal motion, which remained paradoxical throughout the study. Desaturation during REM sleep in all subjects other than subject No. 5 was due to "central" hypopnoea. These episodes during REM sleep were closely associated with phasic eye movements (fig. 5).

Discussion

Background. Few studies of the activity of the inspiratory muscles during sleep have been reported even in normal subjects. In general, they show a reduction in

intercostal muscle activity during REM compared with NREM sleep, usually, but not exclusively in association with eye movements. In healthy individuals, however, activity of the diaphragm is generally preserved or even increased in REM compared with NREM sleep [3–5]. If a similar pattern were to occur in REM sleep in patients with weakness of the respiratory muscles, particularly the diaphragm, profound consequences might be expected.

A number of studies of nocturnal ventilation in subjects with muscle weakness have been reported. NEWSOM DAVIS *et al.* [14] studied eight patients with severe BDP, seven of whom had generalized neuromuscular disorders. Blood gas values during sleep showed a marked deterioration. SKATRUD *et al.* [1] reported the case of a man with BDP due to limb girdle dystrophy, who had alveolar hypoventilation when awake which worsened during sleep. They inferred from reduced chest wall movement that the numerous repetitive desaturations seen during REM sleep resulted from inhibition of intercostal muscle activity, but no direct measurements were made. BYE *et al.* [2] showed markedly reduced accessory muscle activity in REM sleep in one patient with BDP secondary to polio. Nocturnal studies of patients with myotonic dystrophy have shown that periodic desaturation can result from either "central" or "obstructive" events [15], and a recent study in patients with Duchenne's muscular dystrophy found predominantly obstructive events during sleep [7]. A further study of patients with Duchenne's muscular dystrophy [8] noted that "obstructive" events may be misinterpreted as "central" if conventional sleep recordings are made in patients with muscle weakness unable to generate large inspiratory pressures.

The above studies investigated patients with BDP in the context of generalized muscle disease and there have been fewer studies on patients with isolated BDP. STRADLING and WARLEY [16] reported one such patient who had normal daytime blood gases but recurrent episodes of oxygen desaturation during sleep, which they deduced were due to "central apnoeas". KREITZER *et al.* [17] described a non-obese patient with apparently isolated BDP, who presented in respiratory failure. They noted that respiratory failure was worse in the supine than the erect posture and that there was further deterioration during sleep, but the mechanism was not studied. By contrast, LAROCHE *et al.* [6] studying six patients thought to have isolated BDP concluded that they did not have marked nocturnal hypoventilation. Three of their patients were said to have brief episodes of mild oxygen desaturation, but detailed information was not given.

We report the detailed recordings of respiratory muscle activity during REM and NREM sleep in patients with generalized muscle weakness and isolated BDP in order to assess the contributions of the different muscle groups to hypopnoea or apnoea and consequent hypoxaemia. In particular, we have concentrated on: 1) the severity of hypoxaemia associated with BDP alone; 2) the respective contributions of "obstructive" and "central" events and their mechanisms; and 3) the role of abdominal muscles as potential accessory inspiratory muscles during sleep.

Technical considerations. Despite an acclimatization night to minimize the "first night effect" our subjects generally slept poorly. We did, however, obtain good quality recordings during REM sleep in six of the eight subjects. The data available for analysis were also limited by restricting measurements to those obtained in a constant posture.

Surface EMG recordings have the disadvantage of reduced specificity compared with those obtained using needle electrodes. The electrode placements were, however, chosen to reflect EMG activity of the relevant muscles with least contamination from other muscles. Moreover, in the case of genioglossus, previous work has shown EMG activity from transmandibular electrodes to be qualitatively similar to signals from intramuscular electrodes [18]. We found that contamination of EMG_d by abdominal muscle activity was easily differentiated from that of the diaphragm itself by its expiratory timing. Since the abdominal muscle most commonly active in healthy awake subjects during stimulated breathing is transversus abdominis [19], this muscle may also have been active in our patients. It is, however, unlikely that the expiratory EMG activity that we observed originated from transversus abdominis, since this is the abdominal muscle least accessible to surface recordings.

Oxygenation. Nocturnal oxygenation was reduced compared with normal subjects, with the most severe desaturation occurring during REM sleep (table 2). Desaturation was seen in both groups of subjects and was not confined to those with generalized respiratory muscle weakness. On the contrary, figure 1 suggests that the degree of diaphragmatic weakness is an important determinant of desaturation both in generalized muscle weakness and isolated BDP. This conclusion is not incompatible with the results of LAROCHE *et al.* [6]; although their subjects showed only mild nocturnal desaturation they had less awake hypoxaemia than those in the present study. The postural change in VC, however, is dependent not only on diaphragmatic strength but also on other factors, such as obesity, which is common in patients with muscle weakness [20] and was present in some of the subjects in this study. A large ΔVC is likely to be associated with a large reduction in FRC which might contribute to more severe desaturation; no direct measurements of absolute lung volume during sleep are, however, available in patients with respiratory muscle weakness. BYE *et al.* [2] reported a similar relationship between ΔVC and nocturnal oxygenation in neuromuscular disease. The importance of lung volume for the severity of oxygen desaturation during sleep was demonstrated by the correlation between expiratory reserve volume (ERV) and severity of desaturation in patients with obstructive apnoea [21]. It is likely that lung volume and, thus, "oxygen reserve" is an important determinant of the severity of desaturation, and that the more severe the diaphragmatic weakness the smaller that reserve will be. Hence, the degree of functional diaphragmatic impairment is an important determinant of the severity of overnight hypoxaemia.

Mechanisms of desaturation. In all but two subjects (Nos. 5 and 6) events were characterized by hypopnoea rather than complete apnoea. Oxygen desaturation during these events was sometimes less than 4%; equally, some episodes of hypoventilation lasted less than 10 s and, therefore, were not scored as hypopnoea and yet resulted in desaturation of $\geq 4\%$. Consequently, small discrepancies were seen between the numbers of respiratory events and desaturations as defined for the purposes of this study. We classified as "central" those events where an overall reduction in inspiratory EMG activity was observed; "obstructive" events were those where muscle activity was maintained or increased during hypopnoea/apnoea with evidence of arousal and a large increase in EMG_{ge} at event termination in the presence of snoring. The predominant type of event (*i.e.* whether "central" or "obstructive") was generally consistent within an individual, but varied between subjects. Occasional events were more complex, as shown by the example in figure 4. The commonest mechanism of desaturation during pREM sleep was "central" hypopnoea associated with suppression of activity of the intercostal muscles, supporting the conclusions of other studies in patients with muscle weakness where "central" hypopnoea due to reduced intercostal muscle activity during REM sleep has been inferred as the mechanism of hypoventilation and desaturation [1, 16]. Obstructive hypopnoeas and/or apnoeas were seen in two subjects, but in one these were confined to NREM sleep.

The degree to which the activity of any particular muscle group was altered during pREM sleep varied between individuals (fig. 3). Genioglossus activity was more variably affected than that of the intercostal muscles. Clearly, differential suppression of inspiratory muscle groups has implications for the mechanism of the event. In general, an important determinant of whether an apnoea or hypopnoea is "central" or "obstructive" is the balance of activity between the upper airway dilator muscles and the inspiratory "pump" muscles. Clearly, other factors, such as upper airway anatomy and compliance, also play an important part in determining the extent to which the upper airway narrows or occludes (and thus whether an event appears to be "obstructive").

REM sleep is not an homogeneous state but consists of phasic REM (pREM) sleep, characterized by rapid eye movements and myoclonic twitches, and tonic REM (tREM) sleep, in which there is muscle atonia and desynchronized EEG [22]. In healthy subjects, reductions in ventilation during REM sleep are of variable extent and duration and occur particularly in relation to periods of rapid eye movement, *i.e.* pREM [23–25]. Figures 1–4 illustrate the important associations between phasic eye movements during REM sleep and reduced activity of the inspiratory muscles in these patients, as has also been shown in normal subjects [5] and patients with COPD [26, 27].

Abdominal muscles. We observed phasic expiratory activity of the external oblique muscle in seven of the eight subjects when semirecumbent during both wakefulness and NREM sleep, though this was not continuous in all

subjects. These results provide direct support for the conclusions of NEWSOM DAVIS *et al.* [14], who inferred such activity from measurements of abdominal motion. Expiratory activity of the abdominal muscles produces diaphragmatic motion in the cranial direction; their relaxation at the start of inspiration together with the effect of gravity produces passive descent of the diaphragm, which facilitates inspiration. This "inspiratory accessory" activity of the abdominal muscles will only occur if the subjects are at least partially upright, as was the case in this study. Two subjects (Nos. 6 (fig. 2) and 8), intermittently showed pronounced EMG_{exob} activity accompanied by a change in abdominal motion. In the presence of such activity, the PA abdominal dimension, which previously declined during inspiration (abdominal paradox), showed an increase in early inspiration with a reduction only towards the end of inspiration. The initial increase is compatible with passive diaphragmatic descent at the start of inspiration, consequent on relaxation of the abdominal wall muscles. It was also noteworthy that expiratory activity of EMG_{exob} was reduced or absent during "central" hypopnoeas (fig. 5), suggesting that suppression of this activity and the consequent loss of passive caudal motion of the diaphragm may also contribute significantly to the hypopnoea and consequent hypoxaemia.

In conclusion, our results show that in patients with respiratory muscle weakness the severity of nocturnal hypoxaemia is related to the postural fall in vital capacity, suggesting that the degree of impairment of diaphragmatic function is an important determinant of nocturnal oxygenation, irrespective of involvement of other respiratory muscles. Secondly, hypopnoea or apnoea during sleep in weak patients may be either "obstructive" or "central" depending on the pattern of suppression of the different groups of respiratory muscles. In REM sleep, events occur particularly during periods of phasic eye movements. Finally, expiratory activity of the external oblique muscles persists during NREM sleep in semi-recumbent subjects; this probably aids early inspiratory descent of the weak or paralysed diaphragm and suppression of this activity during phasic REM sleep may contribute to "central" hypopnoea in some individuals.

Acknowledgements: The authors gratefully acknowledge the support of the Chest, Heart and Stroke Association and the Breathe North branch of the British Lung Foundation.

References

1. Skatrud J, Iber C, McHugh W, Rasmussen H, Nichols D. Determinants of hypoventilation during wakefulness and sleep in diaphragmatic paralysis. *Am Rev Respir Dis* 1980; 121: 587–593.
2. Bye PT, Ellis RE, Issa FG, Donnelly PM, Sullivan CE. Respiratory failure and sleep in neuromuscular disease. *Thorax* 1990; 45: 241–247.
3. Tusiewicz K, Moldofsky H, Bryan AC, Bryan MH. Mechanics of the ribcage and diaphragm during sleep. *J Appl Physiol: Respirat Environ Exercise Physiol* 1977; 43: 600–602.

4. Tabachnik E, Muller NL, Bryan AC, Levison H. Changes in ventilation and chest wall mechanics during sleep in normal adolescents. *J Appl Physiol: Respirat Environ Exercise Physiol* 1981; 51: 557–564.
5. Muller NL, Francis PW, Gurwitz D, Levison, Bryan CA. Mechanism of haemoglobin desaturation during rapid eye movement sleep in normal subjects and in patients with cystic fibrosis. *Am Rev Respir Dis* 1980; 121: 463–469.
6. Laroche CM, Carroll N, Moxham J, Green M. Clinical significance of severe isolated diaphragm weakness. *Am Rev Respir Dis* 1988; 138: 862–866.
7. Khan Y, Heckmatt JZ. Obstructive apnoeas in Duchenne muscular dystrophy. *Thorax* 1994; 49: 157–161.
8. Smith PEM, Calverley PMA, Edwards RHT. Hypoxaemia during sleep in Duchenne muscular dystrophy. *Am Rev Respir Dis* 1988; 137: 884–888.
9. Loh L, Goldman M, Newsom Davies J. The assessment of diaphragm function. *Medicine* 1977; 56: 165.
10. Griffiths CJ, Gilmartin JJ, Gibson GJ, Murray A. Measurement of chest wall movement; design, performance and clinical use of a four channel magnetometer instrument. *Clin Phys Physiol Meas* 1983; 4: 363–371.
11. Wells DT, Allen RP, Wagman AMI. A single channel system for recording eye movements. *Psychophysiology* 1977; 14: 73–74.
12. Griffiths CJ, Cooper BG, Gibson GJ. A video system for investigating breathing disorders during sleep. *Thorax* 1991; 46: 136–140.
13. Rechtschaffen A, Kales A (eds). A manual of standardised terminology, techniques and scoring system for sleep stages of human subjects. Bethesda, MD, National Institute of Health. 1968; (Publication No. 204).
14. Newsom Davis J, Goldman M, Loh L, Casson M. Diaphragm function and alveolar hypoventilation. *Q J Med* 1976; Vol. 45: 87–100.
15. Gilmartin JJ, Cooper BG, Griffiths CJ, et al. Breathing during sleep in patients with myotonic dystrophy and nonmyotonic respiratory muscle weakness. *Q J Med* 1991; Vol. 78: 21–31.
16. Stradling JR, Warley ARH. Bilateral diaphragm paralysis and sleep apnoea without diurnal respiratory failure. *Thorax* 1988; 43: 75–77.
17. Kreitzer SM, Feldman NT, Saunders NA, Ingram RH. Bilateral diaphragmatic paralysis with hypercapnic respiratory failure, a physiologic assessment. *Am J Med* 1978; 65: 89–95.
18. Sauerland EK, Sauerland BAT, Orr WC, Hairston LE. Noninvasive electromyography of human genioglossal (tongue) activity. *Electromyogr Clin Neurophysiol* 1981; 21: 279–286.
19. De Troyer A, Estenne M, Ninane V, van Gansbeke D, Gorini M. Transversus abdominis muscle function in humans. *J Appl Physiol* 1990; 68: 1010–1016.
20. Smith PEM, Edwards RHT, Calverley PMA. Mechanisms of sleep-disordered breathing in chronic neuromuscular disease: implications for management. *Q J Med* 1991; 81: 961–973.
21. Sériès F, Cormier Y, La Forge J. Role of lung volumes in sleep apnoea-related oxygen desaturation. *Eur Respir J* 1989; 2: 26–30.
22. Sullivan CE, Murphy E, Kozar LF, Phillipson EA. Ventilatory responses to CO₂ and lung inflation in tonic versus phasic REM sleep. *J Appl Physiol: Respirat Environ Exercise Physiol* 1979; 47: 1304–1310.
23. Gould GA, Gugger M, Molloy J, Tsara V, Shapiro CM, Douglas NJ. Breathing pattern and eye movement density during REM sleep in humans. *Am Rev Respir Dis* 1988; 138: 874–877.
24. Wiegand L, Zwillich CW, White DP. Sleep and the ventilatory response to resistive loading in normal men. *J Appl Physiol* 1988; 64: 1186–1195.
25. Millman RP, Knight H, Kline LR, Shore ET, Chung D-CC, Pack AI. Changes in compartmental ventilation in association with eye movements during REM sleep. *J Appl Physiol* 1988; 65: 1196–1202.
26. Johnson MW, Remmers JE. Accessory muscle activity during sleep in chronic obstructive pulmonary disease. *J Appl Physiol: Respirat Environ Exercise Physiol* 1984; 57: 1011–1017.
27. White JES, Drinnan MJ, Smithson AJ, Griffiths CJ, Gibson GJ. Respiratory muscle activity during REM sleep in chronic airflow obstruction. *Thorax* (In Press).