

CASE REPORT

Severe upper airway obstruction in essential tremor presenting as asthma

J.L. Izquierdo-Alonso*, P. Martínez-Martín**,
M.A. Juretschke-Moragues*, J.A. Serrano-Iglesias*

Severe upper airway obstruction in essential tremor presenting as asthma. J.L. Izquierdo-Alonso, P. Martínez-Martín, M.A. Juretschke-Moragues, J.A. Serrano-Iglesias. ©ERS Journals Ltd 1994.

ABSTRACT: A 57 year old man with essential tremor (ET) presented with a 2 year history of paroxysmal attacks of dyspnoea and wheezing. He had been diagnosed as having bronchial asthma, and propranolol was excluded from his treatment.

Flow-volume loops showed abrupt changes in maximum flows, with poor reproducibility. A diagnosis of functional upper airway obstruction was confirmed by fiberoptic bronchoscopy.

The importance of establishing the precise diagnosis, in order to provide appropriate treatment, is emphasized.

Eur Respir J., 1994, 7, 1182-1184.

*Pneumology and **Neurology Departments, Hospital Universitario de Getafe, Getafe, Madrid, Spain.

Correspondence: J.L. Izquierdo-Alonso
Servicio de Neumología
Hospital Universitario de Getafe
Ctra de Toledo Km 12.5
Getafe 28905 Madrid
Spain

Keywords: Essential tremor, obstruction, upper airway

Received: October 27 1993

Accepted after revision January 4 1994

We present the case of a patient with essential tremor (ET), who had been diagnosed as having bronchial asthma. After complete work-up, flow-volume loop and fiberoptic bronchoscopy revealed involuntary movements of glottic structures and typical features of upper airway obstruction. Recognition of this entity as distinct from true asthma may provide substantial changes in the management of the ET, by avoiding unnecessary medication and leading to more appropriate therapy.

Case report

A 57 year old nonsmoking man with a 5 yr history of ET was referred to the emergency room for acute severe dyspnoea after coughing. Two years previously he had, for the first time, experienced an attack of dyspnoea with wheezing and cough, that disappeared in a few hours after administration of intravenous steroids and bronchodilators. A diagnosis of asthma was made and primidone, instead of propranolol, was introduced for his ET. However, despite the use of several drugs, including theophylline and albuterol, he developed at least 15 new "asthma attacks" that required numerous emergency room visits. In some cases, the attack was relieved only by anxiolytic therapy, and an alternative diagnosis of hysterical reaction was suggested.

Physical examination revealed hand tremor, without associated voice tremor or spasmodic dysphonia. Between the attacks, no adventitious sounds were present, but inspiratory and expiratory wheezing, with a maximal intensity over the larynx, had been reported previously.

Laboratory studies (including determinations of thyroid-stimulating hormone (TSH), tri-iodothyronine (T₃),

thyroxine (T₄), and eosinophils), chest radiography and electrocardiography, all produced normal results.

The flow-volume loop performed with a hot-wire anemometer (SensorMedics Corp., CA, USA) showed a remarkable decrease in maximum airflows, with abrupt changes in flow suggesting intermittent airway closure (fig. 1). On repeated studies, wide variations in

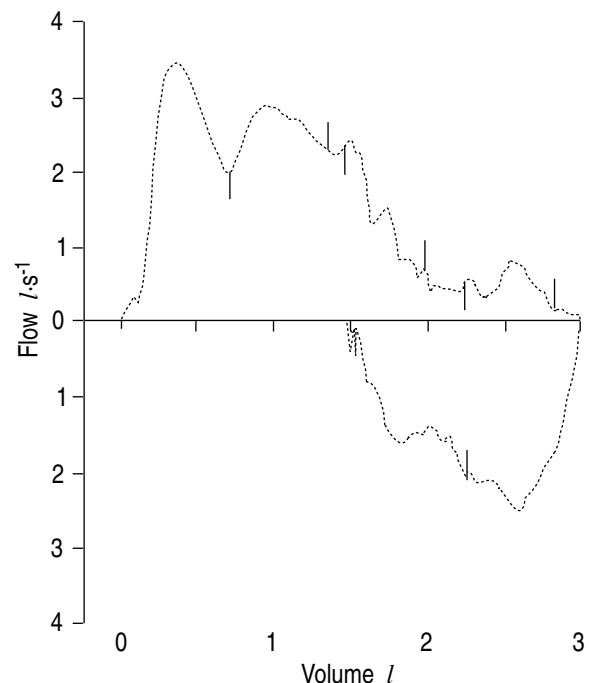


Fig. 1. - Flow-volume curve shows changes in maximum flows suggesting intermittent airway closure. Forced expiratory volume in one second (FEV₁) 1.98 l (67% predicted).

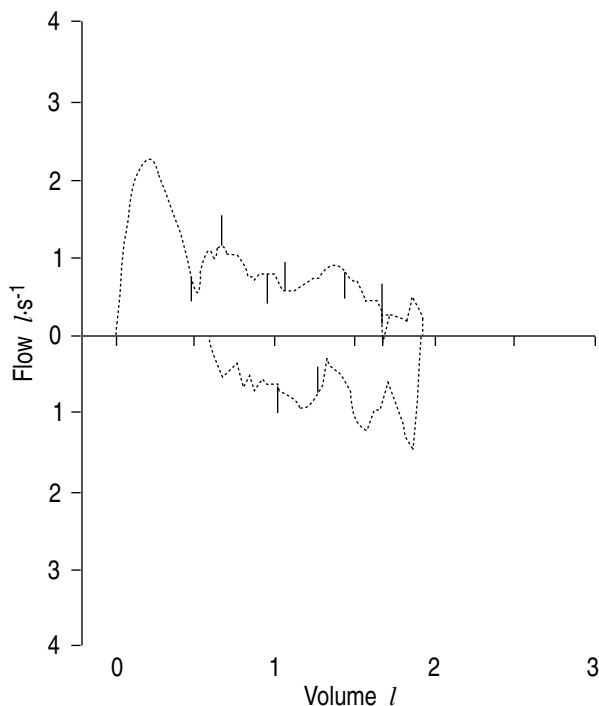


Fig. 2. — Flow-volume curve. Emotional stress prior to bronchoscopy induced deterioration of hand tremor, wheezing and symptomatic upper airway obstruction. Forced expiratory volume in one second (FEV₁) 1.05 l (37% predicted).

flow-volume curve morphology and airflow obstruction were induced by voluntary cough and emotional stress (fig. 2). Airway resistance (R_{aw}) measured with a body plethysmograph and expressed as its reciprocal divided by thoracic gas volume (specific airway conductance (sGaw)) was within normal limits. Measurements of sGaw after inhalation challenge test with methacholine did not show airway hyperresponsiveness. Video-recording by fiberoptic bronchoscopy showed rhythmic changes in the glottic area due to abduction and adduction of the vocal cords, with intermittent partial airway closure secondary to jerky movements of the glottic structures. An anatomical abnormality was excluded. Electromyography performed in supinator and pronator teres muscles revealed an alternating pattern, with a frequency of 7–8 Hz.

A diagnosis of upper airway obstruction (UAO) secondary to ET was made, and the patient was weaned off theophyllines and sympathomimetic aerosols. Since then, he has been under neurological and psychiatric control. After discontinuation of asthma treatment and reinforcement of ET treatment, with higher doses of primidone (250 mg *b.i.d.*), he has experienced a substantial improvement in tremor and has had no further respiratory complaints after six months of follow-up.

Discussion

Our patient was thought to have bronchial asthma for 2 years, even though atypical features suggesting fac-

tious illness were reported in at least two emergency room visits. The withdrawal of propranolol and the deleterious effects on tremor related to use of high doses of sympathomimetic aerosols and theophylline led to suboptimal control of the ET, favouring the maintenance both of neurological and respiratory symptoms.

Although ET is the most common movement disorder [1], and voice tremor suggesting changes in laryngeal function have been described in 18% of a large series of 350 patients with ET, references to airflow obstruction secondary to upper airway dysfunction are scarce in ET [2]. VINCKEN *et al.* [3], analysing involvement of upper airway muscles in extrapyramidal disorders, reported physiological evidence of upper airway obstruction in 3 out of 6 patients with ET. However, this study included 21 more patients with Parkinson's disease, so that data on clinical symptoms are not available from this group of patients. Other isolated reports on UAO in patients with ET seem to be derived from the same population [4]. UAO has to be defined.

Our patient had an extensive psychiatric evaluation, with a final diagnosis of dysthymic disorder. Despite some clinical features mimicking vocal cord dysfunction due to psychological factors [5–9], the presence of flow oscillations on the flow-volume curve suggests active contractions of the laryngeal musculature related to ET. Although flow-time recordings were not obtained, video-recording, as well as simultaneous plotting of relaxed flow-volume loop and volume-time curve, showed fine regular oscillations that were within the frequency of tremor estimated by clinical observation and electromyography. However, mostly during forced manoeuvres, as in figures 1 and 2, superimposed large irregular variations in flow tended to mask this observation.

Interestingly, there was a remarkable discrepancy between the decrease of both inspiratory and expiratory flows, and the normal sGaw measured by plethysmography. Similar results have been reported in other functional causes of UAO [8–10]. Oesophageal pressure was not measured to rule out the possibility that there may have been large changes in pleural pressure due to changes in muscle effort that could be largely responsible for the variations in flow, because it is well-documented that in ET the mechanism underlying intermittently changing flows is airway increase in resistance due to abnormal phasic activity of the upper airway muscles rather than phasic activity of the respiratory pump muscles [3–11].

Discrepancies between maximal flows and airway conductance could be explained because airway narrowing may be more accentuated during forced manoeuvres than during panting. On this account, the patient had difficulty in obtaining an adequate forced inspiratory vital capacity, with inspiratory flow rapidly peaking and then abruptly decreasing (figs 1 and 2). Indeed, to obtain maximal expiratory flow-volume curves, a relaxed inspiratory vital capacity had to be performed previously, suggesting that malfunction of the upper airway muscles may be more conspicuous when strong respiratory efforts are performed. Furthermore,

panting in itself tends to increase glottic opening and to decrease Raw [12]. These findings were substantiated by bronchoscopy.

We therefore suggest that abnormal flow-volume loop in ET should be taken into consideration as a warning marker of symptomatic upper airway obstruction. Because the symptomatology may resemble bronchial asthma, the recognition of this entity may save unnecessary pulmonary treatment that can cause deterioration of the tremor.

References

1. Hubble JP, Busenbark KL, Koller WC. Essential tremor. *Clin Neuropharmacol* 1989; 12: 453-482.
2. Lou JS, Jankovic J. Essential tremor. Clinical correlates in 350 patients. *Neurology* 1991; 41: 234-238.
3. Vincken WG, Gauthier SG, Dollfus SG, Hanson RE, Darauay CM, Cosio MG. Involvement of upper-airway muscles in extrapyramidal disorders. *N Engl J Med* 1984; 311: 438-442.
4. Vincken W, Cosio MG. Flow oscillations on the flow-volume loop: a nonspecific indicator of upper airway dysfunction. *Bull Eur Physiopathol Respir* 1985; 21: 559-567.
5. Christopher KL, Wood RP, Eckert RC, Blager FB, Raney RA, Souhrada JF. Vocal cord dysfunction presenting as asthma. *N Engl J Med* 1983; 308: 1566-1570.
6. Downing ET, Braman SS, Fox MJ, Corrao WM. Factitious asthma. Physiological approach to diagnosis. *J Am Med Assoc* 1982; 248: 2878-2881.
7. Niven RM, Roberts T, Pickering CAC, Webb AK. Functional upper airways obstruction presenting as asthma. *Respir Med* 1992; 86: 513-516.
8. Rodenstein DO, Francis CH, Stanescu DC. Emotional laryngeal wheezing: a new syndrome. *Am Rev Respir Dis* 1983; 127: 354-356.
9. Brown TM, Merritt WD, Evans DL. Psychogenic vocal cord dysfunction masquerading as asthma. *J Nerv Men Dis* 1988; 176: 308-310.
10. Cormier YF, Camus Ph, Desmeules MJ. Nonorganic acute upper airway obstruction. Description and a diagnostic approach. *Am Rev Respir Dis* 1980; 121: 147-150.
11. Vincken WG, Cosio MG. Flow oscillations on the flow-volume loop: clinical and physiological implications. *Eur Respir J* 1989; 2: 543-549.
12. Brown LK. Respiratory Mechanics. In: Miller A, ed. *Pulmonary Function Tests in Clinical and Occupational Lung Disease*. Grune & Stratton Inc. 1986; pp. 93-114.