

## CASE REPORT

# Acute interstitial pneumonitis induced by carbamazepine

N. Takahashi, H. Aizawa, S. Takata, K. Matsumoto,  
H. Koto, H. Inoue, N. Hara

*Acute interstitial pneumonitis induced by carbamazepine. N. Takahashi, H. Aizawa, S. Takata, K. Matsumoto, H. Koto, H. Inoue, N. Hara. ©ERS Journals Ltd 1993.*

**ABSTRACT:** A 62 year old man treated with carbamazepine for 3 months developed eczema and acute interstitial pneumonitis. A lymphocyte-stimulation test was reactive to carbamazepine. Withdrawal of the drug resulted in prompt improvement. Only 10 cases of this type of drug-induced lung disease have previously been reported.

*Eur Respir J., 1993, 6, 1409-1411.*

Research Institute for Diseases of the Chest,  
Faculty of Medicine, Kyushu University,  
Fukuoka, Japan.

Correspondence: H. Aizawa  
Research Institute for Diseases of the Chest  
Faculty of Medicine, Kyushu University,  
3-1-1 Maidashi, Higashiku, Fukuoka 812,  
Japan.

Keywords: Carbamazepine; eczema; interstitial pneumonitis; lymphocyte-stimulation.

Received: December 2 1992

Accepted after revision April 29 1993

Carbamazepine is widely used to treat trigeminal neuralgia and temporal lobe epilepsy. A large number of side-effects have been reported, including disorders of skin [1], blood [2-5], and heart [6, 7]. Pulmonary complications have rarely been recognised with carbamazepine. We describe a case of interstitial pneumonitis induced by carbamazepine.

### Case report

A 62 year old man was referred to our hospital because of dyspnoea of 10 days duration. Carbamazepine (200 mg) had been administered twice daily for 3 months, for the treatment of an arteriovenous malformation. A skin eruption, spreading from his legs to his hands 3 weeks after beginning treatment, caused a discontinuation of all drugs except carbamazepine. Despite this, the skin rash became generalized, and fever and cough developed.

Physical examination disclosed a febrile tachypnoeic man, with a temperature of 37.4°C. A generalized, maculopapular, erythematous skin eruption, sparing the palms and soles, was apparent. Auscultation of the chest revealed crackling rales throughout both lungs. Further physical examination was normal.

White blood cell (WBC) count was 5,720·mm<sup>-3</sup>, with 7.9% eosinophils. Erythrocyte sedimentation ratio was 32 mm·h<sup>-1</sup> and C-reactive protein was 0.6 mg·dl<sup>-1</sup>. Lactate dehydrogenase was elevated at 552 IU·l<sup>-1</sup> (normal: 260-480 IU·l<sup>-1</sup>). Other serum chemistries and serological tests were all within normal limits. A chest radiograph showed a diffuse reticulonodular infiltrate throughout both lungs (fig. 1).

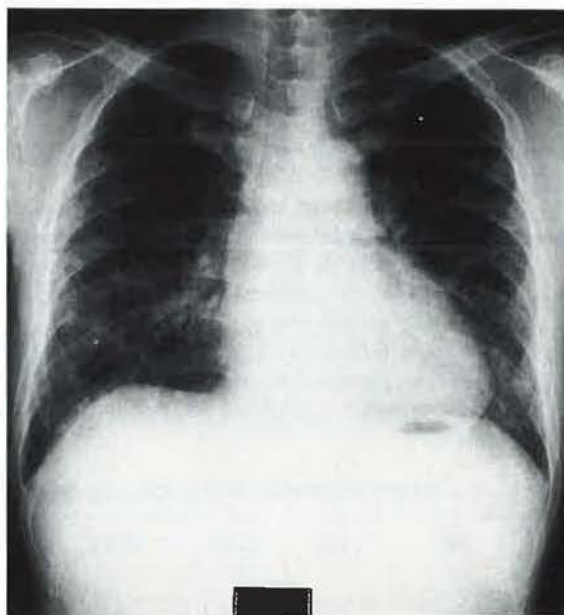


Fig. 1. - Chest radiograph on admission showing a diffuse reticulonodular infiltrate in both lungs.

Pulmonary function tests revealed moderate restrictive impairment and a decrease in carbon monoxide diffusion capacity. Blood gas analyses showed an oxygen tension (P<sub>O<sub>2</sub></sub>) of 8.0 kPa and a carbon dioxide tension (P<sub>CO<sub>2</sub></sub>) of 5.5 kPa, while breathing room air.

Pathological examination of a skin biopsy produced findings compatible with toxic dermatitis. Transbronchial lung biopsy revealed thickened alveolar walls, with mild chronic inflammatory infiltration and swelling of the alveolar walls.



A lymphocyte-stimulation test was performed on admission by evaluating incorporation of  $H^3$ -thymidine. Stimulation using  $25 \text{ mg}\cdot\text{ml}^{-1}$  of carbamazepine produced a value 2.1 times that of control.

Carbamazepine was discontinued, with the presumptive diagnosis of acute interstitial pneumonitis due to carbamazepine. The patient became afebrile and his dyspnoea markedly improved 5 days after admission. Auscultation of the chest became normal, and only a discrete skin eruption remained on both legs, 4 weeks after admission. A repeat chest radiograph showed a striking decrease in the reticulonodular infiltrate and pulmonary function tests revealed improvement. The skin eruption had almost disappeared 9 weeks after admission. The patient continued to improve and was discharged in another 2 weeks, at which time, WBC was  $5,800\cdot\text{mm}^{-3}$  with 1% eosinophils.

A chest radiograph taken 3 months after discharge showed no abnormality. Two years after discharge, the patient is well, without any medication.

### Discussion

We believe this case represents acute interstitial pneumonitis induced by carbamazepine, based upon the following observations. Firstly, acute and moderately debilitating systemic illness with prominent pulmonary alterations, skin rash, and eosinophilia occurred after the administration of carbamazepine. Secondly, a lymphocyte stimulation test revealed a significant clonal expansion response to carbamazepine. Furthermore, the withdrawal of carbamazepine was followed by rapid improvement.

To our knowledge, there have been only 10 cases of pulmonary complications previously reported in association with carbamazepine [8–17] (table 1). The mechanism of lung injury by carbamazepine was recognised as an immune-mediated hypersensitivity. The diagnosis of drug hypersensitivity to carbamazepine can be established by *in vitro* lymphocyte-stimulation tests [18]. It has been reported that significant lymphocyte stimula-

tion *in vitro* by carbamazepine could be demonstrated in all patients with carbamazepine hypersensitivity [18]. Among the cases of pulmonary complications with carbamazepine, positive reactions were reported in all five cases tested for lymphocyte-stimulation (table 1).

As drug-induced lung disease occasionally represents a critical life-threatening condition [19–23], we must recognise the adverse effects of drugs. Drug-induced pneumonitis can be diagnosed by the absence of other causes, mainly infectious and environmental, by the favourable outcome after withdrawal of the incriminated drug, and by bronchoalveolar lavage findings [16, 24]. Carbamazepine should be added to the list of agents which can induce acute interstitial pneumonitis.

### References

1. Roberts DL, Marks R. – Skin reactions to carbamazepine. *Arch Dermatol* 1981; 117: 273–275.
2. Donaldson GWK, Graham JG. – Aplastic anemia following administration of Tegretol. *Br J Clin Pract* 1965; 19: 699–702.
3. Zucker P, Daum F, Cohen MI. – Fatal carbamazepine hepatitis. *J Pediatr* 1977; 91: 667–668.
4. Shoefield Y, Ben Baruch N, Livni E, Santo M, Pinkhas J. – Carbamazepine (Tegretol)-induced thrombocytopenia. *Acta Haematol* 1982; 68: 74.
5. Virolainen M. – Blast transformation *in vivo* and *in vitro* in carbamazepine hypersensitivity. *Clin Exp Immunol* 1971; 9: 429–435.
6. Leslie PJ, Heyworth R, Prescott LF. – Cardiac complications of carbamazepine intoxication; treatment by haemoperfusion. *Br Med J* 1983; 286: 1018.
7. Terrence CF, Fromm G. – Congestive heart failure during carbamazepine therapy. *Ann Neurology* 1980; 8: 200–201.
8. Stephan WC, Parks RD, Tempest B. – Acute hypersensitivity pneumonitis associated with carbamazepine. *Chest* 1978; 74: 463–464.
9. Cullinan SA, Bower GC. – Acute pulmonary hypersensitivity to carbamazepine. *Chest* 1975; 68: 580–581.
10. De Swert LF, Ceuppens JL, Teuwen D, Wijndaele L, Casaer P, Daele MC. – Acute interstitial pneumonitis and carbamazepine therapy. *Acta Paediatr Scand* 1984; 73: 285–288.
11. Kitson GE, Wauchob TD. – Pulmonary edema following carbamazepine overdose. *Anaesthesia* 1988; 43: 967–969.
12. Osada M, Yoshinaga J, Sasaki T, *et al.* – Two cases of drug-induced pneumonitis during psychotropic medication. *Jap J Clin Psychiatry* 1990; 19: 1885–1891.
13. Tolmie J, Steer CR, Edmunds AT. – Pulmonary eosinophilia associated with carbamazepine. *Arch Dis Child* 1983; 58: 833–834.
14. Lee T, Cochrane GM, Amlot Br. – Pulmonary eosinophilia and asthma associated with carbamazepine. *Br Med J* 1981; 282: 440.
15. Lewis IJ, Rosenbloom L. – Granular fever-like syndrome, pulmonary eosinophilia and asthma associated with carbamazepine. *Postgrad Med J* 1982; 58: 100–101.
16. Vergnon JM, Tavaud B, Courtfortune I, Cottier M, Emonot A. – Pneumopathie interstitielle la carbamazepine (Tegretol R). *Rev Mal Respir* 1988; (suppl. I): R138.
17. Schmidt M, Brugger F. – Ein Fall von Carbamazepine-induzierter interstitieller Pneumoniae. *Med Klin* 1980; 75: 29–31.
18. Houwerzijl J, Gast GC, Nater JP, Esselink MT, Nieweg HO. – Lymphocyte-stimulation tests and patch tests in

Table 1. – Carbamazepine-induced pulmonary disease

Sex	Age yrs	Type	Eosin %	DLST	[Ref]
M	16	AIP	11	NS	[8]
F	55	PIE	58	+ve	[9]
F	14	AIP	NS	+ve	[10]
M	23	PO	NS	NS	[11]
F	66	AIP	NS	+ve	[12]
F	8	PIE	54	NS	[13]
M	52	PIE, BA	20	+ve	[14]
M	8	PIE, BA	29	NS	[15]
F	66	AIP	NS	+ve	[16]
F	52	AIP	4	NS	[17]

Eosin: blood eosinophil; AIP: acute interstitial pneumonitis; PIE: pulmonary infiltrate with eosinophilia; PO: pulmonary oedema; BA: bronchial asthma; DLST: drug-induced lymphocyte stimulation test; NS: not stated; +Ve: positive.

carbamazepine hypersensitivity. *Clin Exp Immunol* 1977; 29: 272-277.

19. Taylor MW, Smith CC, Hern JEC. - An unexpected reaction to carbamazepine. *Practitioner* 1981; 225: 219-Δ1 220.

20. Denning DW, Matheson L, Bryson SM, Streete J, Berry DJ, Herry JA. - Death due to carbamazepine self-poisoning. *Hum Toxicol* 1985; 4: 255-260.

21. May DC. - Acute carbamazepine intoxication; clinical

spectrum and management. *South Med J* 1984; 77: 24-26.

22. Kossoy AF, Weir MR. - Therapeutic indications in carbamazepine overdose. *South Med J* 1985; 78: 999-1000.

23. De Zeeuw R, Van Der Klejn E, Cimbriere J. - An unusual case of carbamazepine poisoning with a near-fatal relapse after two days. *Clin Toxicol* 1979; 14: 263-269.

24. Akoun GM, Cadranet JL, Milleron BJ, Flammang D'Ortho MP, Mayaud CM. - Bronchoalveolar lavage cell data in pneumonitis (except amiodarone). *Chest* 1991; 99: 98-104.