

CASE REPORT

Lesions of the arytenoid region in a patient with exertional dyspnoea

A. Nagai, H. Matsumiya, M. Hayashi, T. Kanemura, S. Yasui, K. Konno

Lesions of the arytenoid region in a patient with exertional dyspnoea. A. Nagai, H. Matsumiya, M. Hayashi, T. Kanemura, S. Yasui, K. Konno. ©ERS Journals Ltd 1993.

ABSTRACT: A 63 year old woman presented with a 3 year history of exertional dyspnoea. Spirometry suggested extrathoracic airway obstruction (decreased inspiratory flow and saw-tooth pattern of flow-volume curves), and bronchoscopy revealed structural lesions and a trembling motion in the arytenoid region, causing upper airway obstruction on forced respiratory efforts. As there were no abnormal findings other than the lesions, the exertional dyspnoea was probably caused by impaired movement of the arytenoid region.

Eur Respir J., 1993, 6, 1065-1066

First Department of Medicine, Tokyo Women's Medical College, Tokyo, Japan.

Correspondence: A. Nagai
First Department of Medicine
Tokyo Women's Medical College
8-1 Kawadacho
Shinjuku
Tokyo 162
Japan

Keywords: Arytenoid region, bronchoscopy, dyspnoea, flow-volume curve

Received: June 3 1992

Accepted after revision November 6 1992

Some patients who complain of dyspnoea have no obvious abnormalities on routine laboratory examination. We have previously reported two cases with dyspnoea caused by functional upper airway obstruction, and have suggested the benefit of direct bronchofibrescopic observation of forced respiratory efforts, together with flow-volume curves [1, 2]. The present case of long-term dyspnoea on exertion had abnormal motion, associated with structural lesions in the arytenoid region.

Case history

A 63 year old woman presented with dyspnoea on exertion of 3 yrs duration. She had previously been examined for this complaint, and a psychogenic disorder had been suspected in several hospitals. She was a non-smoker. On physical examination in our hospital, there were no abnormalities. Pulmonary function tests, including vital capacity (VC) 107% predicted, forced expiratory volume in one second (FEV₁) 79% predicted and diffusion capacity of the lungs for carbon monoxide (DLCO) 102% predicted, were normal in a percentage of predicted values [3], but spirometry, at both pre- and post-bronchodilator inhalation, revealed flow oscillation described as the "saw-tooth sign", and a moderate decrease in forced inspiratory-flow with a plateau configuration, suggesting extrathoracic airway obstruction (fig. 1). Immediately after spirometry, fiberoptic bronchoscopic examination demonstrated a thickened and deformed right-sided arytenoid region, associated with abnormal movement on forced inspiratory effort, leading to narrowing of the laryngeal orifice (fig. 2), and its trembling motion during expiration (fig. 3). Other portions of the airway, including the pharynx, glottis,

vocal cords and trachea, were normal. Arterial blood gas analyses before or after exercise were within normal range. Chest roentgenogram, computerized tomograph, magnetic resonance imaging, electrocardiograph (ECG), echocardiograph, perfusion scintigram, and haematological and biochemical laboratory values were normal. Both neurological examination and electroencephalogram (EEG) were normal. A psychiatric evaluation demonstrated no remarkable abnormalities. Based on the bronchoscopic findings, further examinations including local biopsy were scheduled, but were subsequently cancelled.

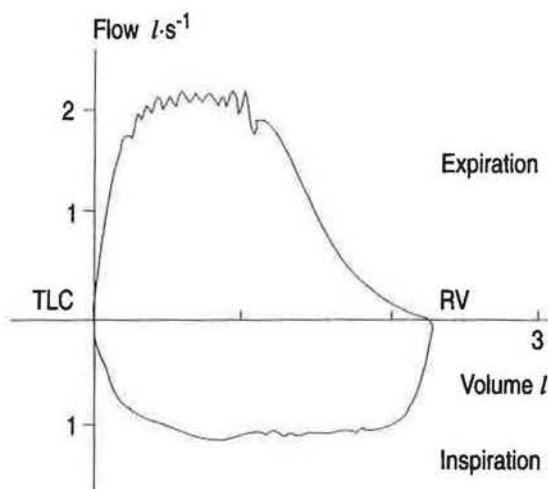


Fig. 1. - Flow-volume loops, showing saw-tooth pattern in expiratory flows and decreases in inspiratory flows with a plateau configuration. TLC: total lung capacity; RV: residual volume.

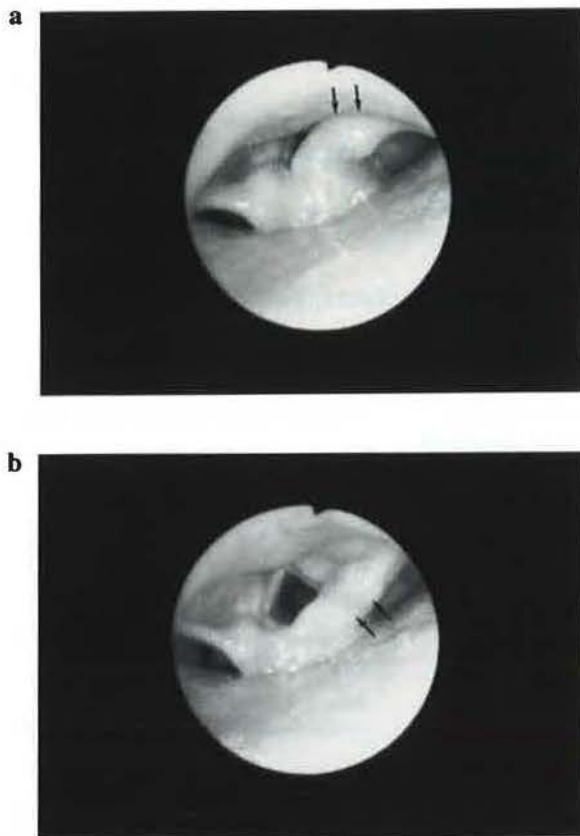


Fig. 2. - a) Bronchoscopic findings, on forced inspiratory effort, revealed narrowing of the laryngeal orifice due to asymmetrical movement of the right side of the arytenoid region (arrows). b) In contrast, on quiet breathing, the orifice is open and the structural lesions on the right side of the arytenoid region are clearly demonstrated.

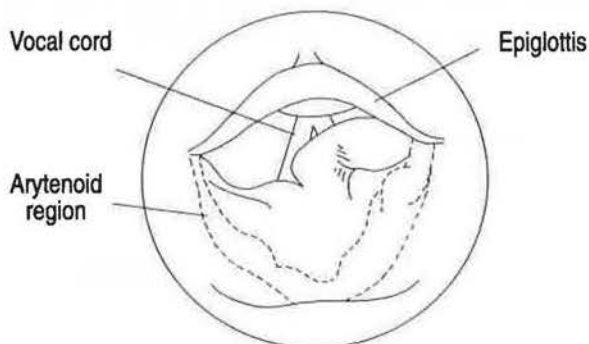


Fig. 3. - A schema of abnormal movement of arytenoid region. Dotted line corresponding to Fig. 2b indicates the configuration of the arytenoid region at quiet breathing. Straight line corresponding to Fig. 2a shows narrowing of the laryngeal orifice due to abnormal configuration of the arytenoid region on forced inspiratory effort

Discussion

Exertional dyspnoea occurs in various clinical situations, such as hyperventilatory state, heart disease, and

obstructive or restrictive pulmonary disease [4]. The presenting case showed no abnormal findings in the pulmonary or cardiovascular system, or in any neuromuscular or metabolic system, with the exception of abnormalities in the arytenoid region. Thus, although there is no direct evidence, the exertional dyspnoea probably seemed to be caused by upper airway obstruction, associated with abnormal motion of the structural lesions in the arytenoid region as shown in the schema of fig. 3. It is well-known that upper airway obstruction is seen in organic abnormalities [5]. At the first interview for the present illness, the patient had no history suggestive of upper airway organic disease. However, a further interview revealed that 6 months prior to start of the present complaint she had had a small amount of purulent expectoration for several months, and had been diagnosed as having laryngitis. Therefore, the structural lesions of the arytenoid region might have been associated with this inflammatory episode.

The oscillation of flow-volume loops was thought to be due to underlying upper airway instability, and has been recognized as an indicator of upper airway obstruction [6, 7], although, in a very recent study, NEUKIRCH *et al.* [8] reported that the oscillation of flow-volume loops does not correlate with upper airway obstruction. Our present case showed a typical saw-tooth pattern of forced flow-volume loops at both pre- and post-bronchodilator inhalation, and we were able to ascertain structural abnormalities and a trembling motion of the arytenoid region. Thus, the oscillation of forced flow-volume loops is probably brought about by lesions of the arytenoid region. The sensation of dyspnoea on exertion may be derived from such a mild degree of upper airway obstruction, and direct bronchoscopic observation during forced respiratory efforts is suggested, in order to detect the functional abnormalities associated with certain lesions, when an abnormal flow-volume loop configuration is found.

References

1. Nagai A, Sakamoto K, Yamaguchi E, Takahashi E. - Functional upper airway obstruction; psychogenic pharyngeal constriction. *Chest* 1992; 101: 1460-1461.
2. Nagai A, Kanemura T, Konno K. - Abnormal movement of the arytenoid region as a cause of upper airway obstruction. *Thorax* (in press).
3. Bates DV, Macklem PT, Christie RV. - *In: Respiratory Function in Disease*. Philadelphia, W.B. Saunders, 1971; p. 94.
4. Crofton J, Douglas A. - *Respiratory Diseases*. London, Blackwell Scientific Publications Ltd, 1975; pp. 52-55.
5. Proctor DF. - The upper airways. II. The larynx and trachea. *Am Rev Respir Dis* 1977; 115: 315-342.
6. Sanders M, Stiller RA. - Still going around on the flow-volume loop. *Chest* 1992; 101: 301-302.
7. Vincken WG, Cosio MG. - Flow oscillation on the flow-volume loop: clinical and physiological implications. *Eur Respir J* 1989; 2: 543-549.
8. Neukirch F, Weitzenblum E, Liard R, *et al.* - Frequency and correlates of the saw-tooth pattern of flow-volume curves in an epidemiological survey. *Chest* 1992; 101: 425-431.