



# Diffuse alveolar haemorrhage secondary to e-cigarette “vaping” associated lung injury (EVALI) in a young European consumer

To the Editor:

We report the case of a 28-year-old woman admitted with acute respiratory failure. The patient had no personal or familial medical history involving respiratory disease such as asthma, thrombotic events or bleeding. She was a heavy smoker (15 cigarettes per day for the past 5 years) and “vaped” electronic cigarettes (e-cigarettes) for 1 month prior to the incident. She consumed 10 mL of e-liquid bottled with nicotine salt ( $12 \text{ mg}\cdot\text{mL}^{-1}$ ) in 2 days. No cannabidiol (CBD) or tetrahydrocannabinol (THC) was detected. No other home-made components were added. The patient did not take any regular medicines or contraceptives. No consumption of cannabis, cocaine or any other drugs was reported (confirmed with negative urinary drug test). She had not travelled outside of France. She was referred to the emergency department (ED) for tachypnoea (respiratory rate 22–25 per min), desaturation at 80% in the context of dyspnoea evolving for 15 days. No cough, haemoptysis or extra-thoracic manifestations were reported. Her temperature was  $36.8^\circ\text{C}$ , pulse 98 beats per minute, blood pressure 123/79 mmHg. Heart sounds were regular but crackles were audible on thoracic auscultation. An alveolar and interstitial syndrome was observed on chest radiography (data not shown). Ceftriaxone and spiramycin was initiated in ED and oxygen therapy was started at  $12 \text{ L}\cdot\text{min}^{-1}$ . Serum creatinine was  $52 \mu\text{mol}\cdot\text{L}^{-1}$  and complete blood cell count highlighted an anaemia of  $5.4 \text{ g}\cdot\text{dL}^{-1}$ . Leukocyte count was  $10.6 \times 10^9$  per L, C-reactive protein levels  $60.3 \text{ mg}\cdot\text{dL}^{-1}$  and procalcitonin was normal ( $<0.1 \text{ ng}\cdot\text{mL}^{-1}$ ). Platelet count, liver enzymes and haemostasis parameters were inconspicuous. No proteinuria or haematuria was detected. Antinuclear (ANAs), anti-neutrophil cytoplasmic (ANCAs) and anti-glomerular basement membrane (GBM) antibodies were all negative. Complement levels were normal. Dot-myositis and antiphospholipid antibodies were negative. Pneumococcal and Legionella antigenurias were negative. Blood cultures did not identify any bacteria. Serological results for HIV, *Chlamydiae pneumoniae*, *psitacci* and *Mycoplasma pneumoniae* were negative. Computed tomography (CT) scan showed no proximal pulmonary embolism but identified a diffuse alveolar condensation with ground glass opacities (GGO) (figure 1a). No pleuropericardial effusion was observed. Echocardiography found normal left and right ventricular function. A rapid respiratory deterioration occurred. The patient was finally intubated and ventilated with lung protective ventilation strategy at day 1. A bronchoalveolar lavage (BAL) was performed at day 2. An alveolitis with 850 000 red cells per  $\text{mm}^3$  and 4000 per  $\text{mm}^3$  white blood cells, consisting of 48% neutrophils, 2% eosinophils, 3% lymphocytes and 47% macrophages and mono-histiocytic cells was observed. BAL fluid revealed an alveolar haemorrhage with 95% of siderophages and a Golde score of 196. No cytological image of cytomegalovirus-like virus was noted and *Pneumocystis jirovecii* staining was negative. Cultures of aspirated secretions were negative. Treatments administered are summarised in figure 1d. Because of an arterial oxygen tension to inspiratory oxygen fraction ratio of 70, a reduced pulmonary compliance of  $8 \text{ mL}\cdot\text{cmH}_2\text{O}^{-1}$  and a failure of the prone position, a veno-venous extracorporeal membrane oxygenation (VV-ECMO) was implanted. Several prone position sessions under VV-ECMO were necessary to improve compliance. A surgical lung biopsy (SLB) was performed at day 3. The architecture of the lung parenchyma was preserved and pneumocyte vacuolisation was seen. Red blood cells, siderophages (identified with Perls staining) and neutrophils were observed in alveoli (figure 1b). No oedema, hyaline membranes or granuloma was described. No interstitial deposits and no deposits in elastic limiting vessels were identified. Immunofluorescence (IgA, IgG, IgM, C3, C1q, kappa, lambda) was negative. We

 @ERSpublications

A notable case of EVALI not involving cannabis derivatives in a 28-year-old woman who developed an intra-alveolar haemorrhage without differential diagnosis after surgical lung biopsy and requiring extracorporeal membrane oxygenation <http://bit.ly/2TXx79K>

Cite this article as: Villeneuve T, Prevot G, Le Borgne A, *et al.* Diffuse alveolar haemorrhage secondary to e-cigarette “vaping” associated lung injury (EVALI) in a young European consumer. *Eur Respir J* 2020; 56: 2000143 [<https://doi.org/10.1183/13993003.00143-2020>].

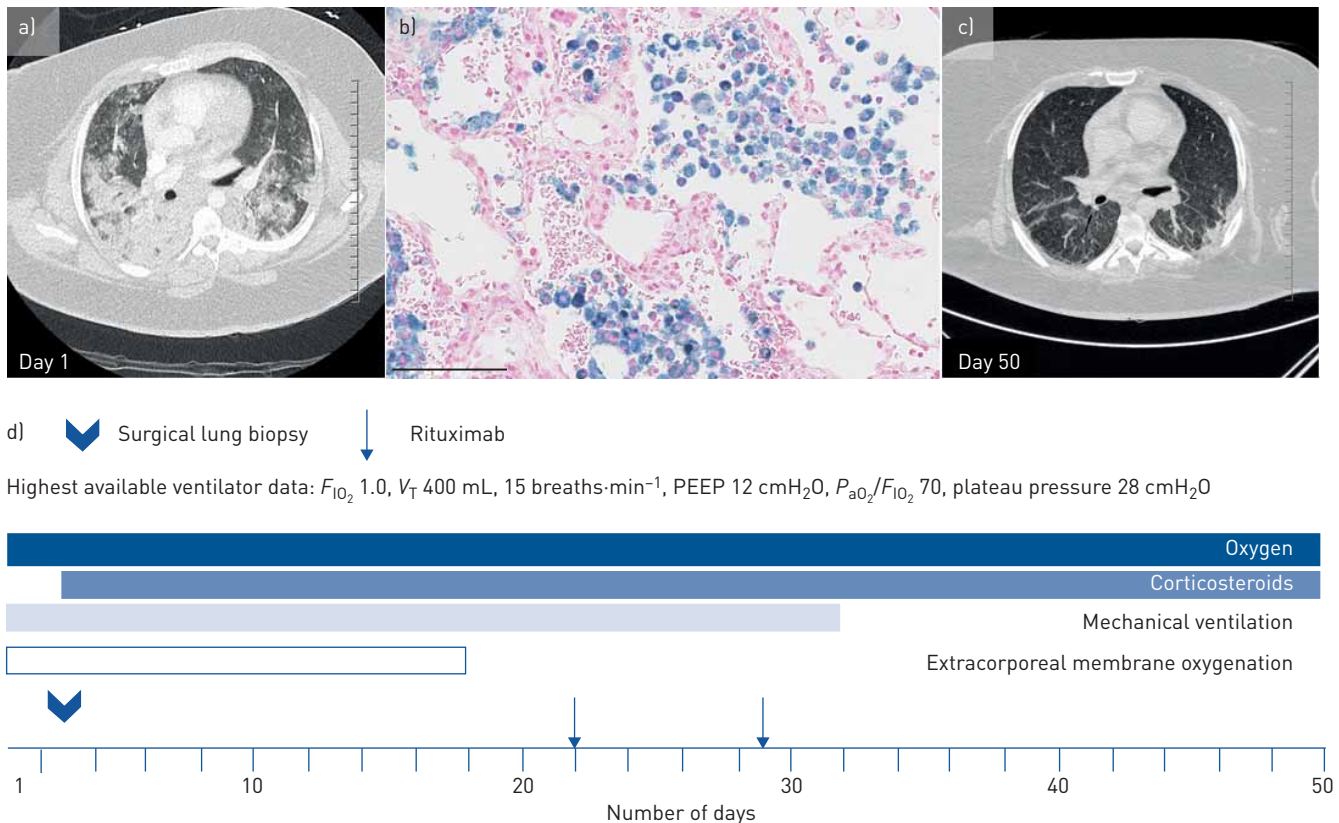


FIGURE 1 a) Initial axial computed tomography (CT) scan showed no proximal pulmonary embolism but bilateral ground-glass opacities (GGO) and consolidation with peri-bronchovascular and lobar distribution. b) Surgical lung biopsy: Perl's staining detected siderophages, compatible with a pattern of diffuse alveolar haemorrhage. c) Axial CT scan at day 50 revealed less GGO and consolidation. d) Treatments administered in the intensive care unit.

confirmed a diagnosis of diffuse alveolar haemorrhage (DAH). After SLB, bolus of corticosteroids ( $10 \text{ mg}\cdot\text{kg}^{-1}$ ) was performed over 3 days. Lung exchange improved gradually under corticosteroids ( $1 \text{ mg}\cdot\text{kg}^{-1}$ ). At day 10, a ventilator-associated pneumonia occurred. Tracheal aspiration identified *Pseudomonas aeruginosa* and piperacillin–tazobactam was started (during 14 days). VV-ECMO was explanted at day 18. Despite ECMO withdrawal, the situation remained severe and an immunosuppressant drug was discussed due to 1) a life-threatening disease requiring ventilation, 2) the recurrence of DAH (visualised at day 21 by bronchial fibroscopy with a Golde score of 222), and 3) no aetiological feature found on SLB. The patient was treated with rituximab ( $375 \text{ mg}\cdot\text{m}^{-2}$ ) at day 22 and 29. Sedation was stopped at day 31, ventilation was weaned at day 37 and oxygen at day 50. Opacities and GGO subsequently became less marked on CT imaging (figure 1c). The aetiology was investigated in more detail. An intensive exposure to e-cigarette purchased from specialised store and initiated 1 month prior was reported. The reference product used was sent to the local poison control centre for investigation. The e-liquid sample were analysed by gas chromatography coupled to mass spectrometry (GC–MS) and detected glycerol, nicotine, propane-1,2-diol, ethyl maltol and ethyl lactate, which was consistent with the manufacturer's disclosed composition data (which we obtained by contacting the particular e-liquid brand). A progressive weaning of corticosteroids was performed over a period of 4 months. At the 1-year follow-up and after complete cessation of tobacco and vaping, the patient showed no pulmonary symptoms and no recurrence of DAH. Diagnostic criteria proposed by the US Centre for Disease Control and Prevention (CDC) for e-cigarette or vaping product use-associated lung injury (EVALI) include: use of an e-cigarette (vaping) in the 90 days before symptom onset, pulmonary infiltrate or GGO on chest CT and absence of pulmonary infection or alternative diagnoses. The majority (80%) of e-liquids purchased via the internet contain CBD or THC [1]. In Europe, e-liquids containing CBD or THC are prohibited for sale but can still be sourced from the internet. Very few cases of EVALI have been reported in Europe and no biopsy was performed [2]. To date, case reports indicate a variety of presentations, including lipid pneumonia [3], hypersensitivity pneumonitis [4], acute eosinophilic pneumonia [5, 6], organising pneumonia [7], DAH [8] and giant cell interstitial pneumonia [9]. A clinical practice algorithm for the evaluation and management of EVALI has been proposed [10]. BAL is essential to eliminate any potential

pulmonary infection on initial workup. In the series presented by LAYDEN *et al.* [1], 14 BAL specimens were reported. BAL most commonly detected neutrophilia (median value 65%) and often identified the presence of lipid laden macrophages by Oil Red O staining or Sudan staining, but the latter is not an essential criterion for the diagnosis of EVALI [11]. No histological findings were specific [12]. BUTT *et al.* [12] describe patterns of diffuse alveolar damage, acute fibrinous pneumonitis and organising pneumonia. Our particular case satisfies the clinical and radiological criteria of confirmed EVALI, according to CDC guidelines. BAL fluid and histopathological findings showed DAH without any specific signs of secondary involvement. Recent reports suggest that vitamin E acetate may be implicated in EVALI [13]. In our case, no cannabis derivatives were identified and the implications of other toxic substances may be discussed, underscoring the importance of knowing whether patients have been exposed to e-cigarettes. Currently, approximately two-thirds of EVALI patients require management in the intensive care unit [10]. A clinical improvement documented with use of systemic glucocorticoids is often described [1]. In our case, rituximab injections were administered but benefit is uncertain and not recommended in EVALI guidelines. Previously, only AGUSTIN *et al.* [8] published a case with a pattern of DAH induced by vaping. We report the first case of a European DAH-EVALI not involving cannabis derivatives as confirmed by SLB and requiring intensive care treatment with mechanical ventilation and VV-ECMO. The toxicity of e-cigarettes requires further investigation.

Thomas Villeneuve <sup>1</sup>, Grégoire Prevot<sup>1</sup>, Aurélie Le Borgne<sup>1</sup>, Magali Colombat<sup>2</sup>, Samia Collot<sup>3</sup>, Stephanie Ruiz <sup>4</sup>, Thomas Lanot<sup>5</sup>, Laurent Brouchet<sup>6</sup>, Audrey Rabeau<sup>1</sup>, Elise Noel-Savina<sup>1</sup> and Alain Didier<sup>1</sup>

<sup>1</sup>Service de Pneumologie, Hôpital Larrey, Université Paul Sabatier, CHU Toulouse, Toulouse, France. <sup>2</sup>Service d'Anatomo-Pathologie, Institut Universitaire du Cancer, CHU Toulouse, Toulouse, France. <sup>3</sup>Service de Radiologie, Hôpital Rangueil et Larrey, Université Paul Sabatier, CHU Toulouse, Toulouse, France. <sup>4</sup>Service de Réanimation polyvalente adultes, Hôpital Rangueil, Université Paul Sabatier, CHU Toulouse, Toulouse, France. <sup>5</sup>Laboratoire de Pharmacocinétique et toxicologie, Institut Fédératif de Biologie, Université Paul Sabatier, CHU Toulouse, Toulouse, France. <sup>6</sup>Service de Chirurgie thoracique, Hôpital Larrey, Université Paul Sabatier, CHU Toulouse, Toulouse, France.

Correspondence: Thomas Villeneuve, Hôpital Larrey, CHU Toulouse. Chemin de Pouvoirville, 31059 Toulouse Cedex, France. E-mail: villeneuve.t@chu-toulouse.fr

Received: 23 Jan 2020 | Accepted after revision: 4 March 2020

Conflict of interest: T. Villeneuve has nothing to disclose. G. Prevot has nothing to disclose. A. Le Borgne has nothing to disclose. M. Colombat has nothing to disclose. S. Collot has nothing to disclose. S. Ruiz has nothing to disclose. T. Lanot has nothing to disclose. L. Brouchet has nothing to disclose. A. Rabeau has nothing to disclose. E. Noel-Savina has nothing to disclose. A. Didier reports personal fees for advisory board work from AstraZeneca, GSK, ALK, Novartis and Boehringer Ingelheim, outside the submitted work.

## References

- Layden JE, Ghinai I, Pray I, *et al.* Pulmonary illness related to e-cigarette use in Illinois and Wisconsin—preliminary report. *N Engl J Med* 2020; 382: 903–916.
- Casanova GS, Amaro R, Soler N, *et al.* An imported case of e-cigarette or vaping associated lung injury (EVALI) in Barcelona. *Eur Respir J* 2020; 55: 1902076.
- Dicpinigaitis PV, Trachuk P, Fakier F, *et al.* Vaping-associated acute respiratory failure due to acute lipid pneumonia. *Lung* 2020; 198: 31–33.
- Sommerfeld CG, Weiner DJ, Nowalk A, *et al.* Hypersensitivity pneumonitis and acute respiratory distress syndrome from e-cigarette use. *Pediatrics* 2018; 141: e20163927.
- Thota D, Latham E. Case report of electronic cigarettes possibly associated with eosinophilic pneumonitis in a previously healthy active-duty sailor. *J Emerg Med* 2014; 47: 15–17.
- Arter ZL, Wiggins A, Hudspath C, *et al.* Acute eosinophilic pneumonia following electronic cigarette use. *Respir Med Case Rep* 2019; 27: 100825.
- Khan MS, Khateeb F, Akhtar J, *et al.* Organizing pneumonia related to electronic cigarette use: a case report and review of literature. *Clin Respir J* 2018; 12: 1295–1299.
- Agustin M, Yamamoto M, Cabrera F, *et al.* Diffuse alveolar hemorrhage induced by vaping. *Case Rep Pulmonol* 2018; 2018: 1–3.
- Carlos WG, Crotty Alexander LE, Gross JE, *et al.* Vaping-associated pulmonary illness (VAPI). *Am J Respir Crit Care Med* 2019; 200: P13–P14.
- Kalininskiy A, Bach CT, Nacca NE, *et al.* E-cigarette, or vaping, product use associated lung injury (EVALI): case series and diagnostic approach. *Lancet Respir Med* 2019; 7: 1017–1026.
- Maddock SD, Cirulis MM, Callahan SJ, *et al.* Pulmonary lipid-laden macrophages and vaping. *N Engl J Med* 2019; 381: 1488–1489.
- Butt YM, Smith ML, Tazelaar HD, *et al.* Pathology of vaping-associated lung injury. *N Engl J Med* 2019; 381: 1780–1781.
- Blount BC, Karwowski MP, Shields PG, *et al.* Vitamin E acetate in bronchoalveolar-lavage fluid associated with EVALI. *N Engl J Med* 2020; 382: 697–705.