

Fire-eater's lung

P.E. Brander*, E. Taskinen**, B. Stenius-Aarniala*

Fire-eater's lung. P.E. Brander, E. Taskinen, B. Stenius-Aarniala.

ABSTRACT: Acute pneumonitis following aspiration of petroleum products is usually related to accidental poisonings in children. We describe here two cases of hydrocarbon pneumonitis in fire-eaters, caused by accidental aspiration of petroleum during the performance of fire-eating.

Both patients had cough, dyspnoea, chest pain and fever. Chest X-rays showed basal lung infiltrates and, 2 weeks later, pneumatocele formations. Reversible bronchial hyperresponsiveness and restrictive ventilatory limitation were demonstrated in one of the patients. The bronchoalveolar lavage specimen showed cytoplasmic vacuolation of the macrophages and neutrophilia.

After treatment with antibiotics and corticosteroids the symptoms disappeared and the lung function values returned to normal within 2-3 weeks. Radiological resolution of the pneumatoceles occurred within 2-12 months.

Eur Respir J, 1992, 5, 112-114.

* Dept of Pulmonary Medicine and
** Transplantation Laboratory
Helsinki University, Helsinki, Finland.

Correspondence: P.E. Brander
Puolimatkatkatu 15 D 2
SF-05830 Hyvinkää, Finland.

Keywords:
Chemical pneumonitis
fire-eating
hydrocarbons
pneumatocele
toxic lung reaction.

Received: March 12, 1991

Accepted after revision July 15, 1991.

Fire-eaters use liquid hydrocarbons such as petroleum as ignition fluid for the performance of the flame-blowing part of the show. For flame swallowing, the fire-eater puts a burning stick into the mouth while holding his breath until the flames are extinguished. For flame blowing, the performer blows out a mouthful of liquid hydrocarbon against a burning stick, thus creating an aerosol which catches fire around the stick. This gives an impression of flames coming out from the performer's mouth. We present two cases of chemical pneumonitis in fire-eaters following accidental aspiration of petroleum during the flame-blowing act.

Case reports

Patient 1

The patient was a 32 yr old, previously healthy, female smoker. She had been acting as a fire-eater since 1983 with no previous occupational accidents. During a performance in May 1989, she accidentally aspirated a small amount of petroleum. Immediately after the show she visited a hospital, complaining of cough and retrosternal pain. The physical findings and the chest X-ray were normal. In the course of a few hours, fever, dyspnoea and left-sided chest pain developed. On auscultation, bilateral basal coarse inspiratory crackles were heard. A second chest X-ray taken 8 h after the accident showed patchy infiltrates in the right middle and left lower lobes (fig. 1). A slight fall in arterial oxygen tension ($P_{aO_2}=10.1$ kPa) was noted. The C-reactive protein value (CRP) rose to 274 $mg \cdot l^{-1}$. The patient was treated with prednisolone and oral co-trimoxazole; after five days co-trimoxazole was changed to parenteral cefotaxime and tobramycin

because of recurrent fever. Inhaled budesonide (1600 $\mu g \cdot day^{-1}$) and oxitropium bromide (600 $\mu g \cdot day^{-1}$) were given. Lung function tests 3-14 days after the accident showed slight restrictive impairment of ventilatory function, a decrease in diffusing capacity corresponding to the degree of restriction, and a mild bronchial hyperresponsiveness (fig. 2). Six days after the accident bronchofibrescopy with bronchoalveolar lavage (BAL) was performed. Histological examination of the bronchial mucosa showed lymphocytic and plasma cell infiltration beneath a normal respiratory epithelium. The total cell count in the BAL specimen was slightly increased, to $293 \times 10^6 \cdot l^{-1}$ (normal range $50-260 \times 10^6 \cdot l^{-1}$). The percentage of neutrophils in the Millipore-filter differential cell count was 26% (normal range 1-5%).

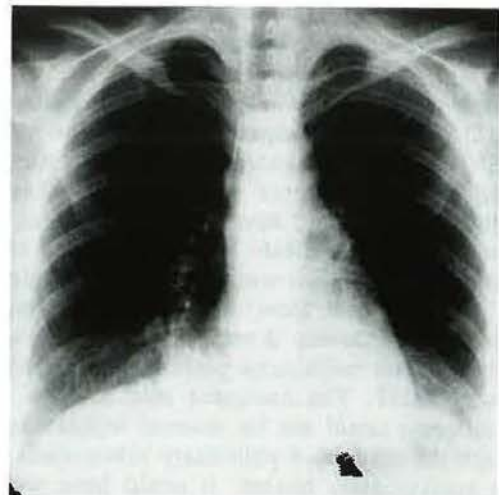


Fig. 1. - Chest X-ray taken 8 h after the accident shows infiltration in right middle and left lower lobes (patient 1).

Seventy percent of the macrophages displayed finely distributed cytoplasmic vacuolation. The columnar respiratory epithelial cells showed benign atypia. The albumin concentration of the BAL fluid was increased to $228 \text{ mg}\cdot\text{l}^{-1}$ (reference value $<40 \text{ mg}\cdot\text{l}^{-1}$).

After 4 days, a cavity with a fluid level was seen in the chest X-ray in the area of the dense right-sided infiltration. The symptoms disappeared in a few days. One month later, spirometry and diffusing capacity were normal. A small cavity in the right lung was

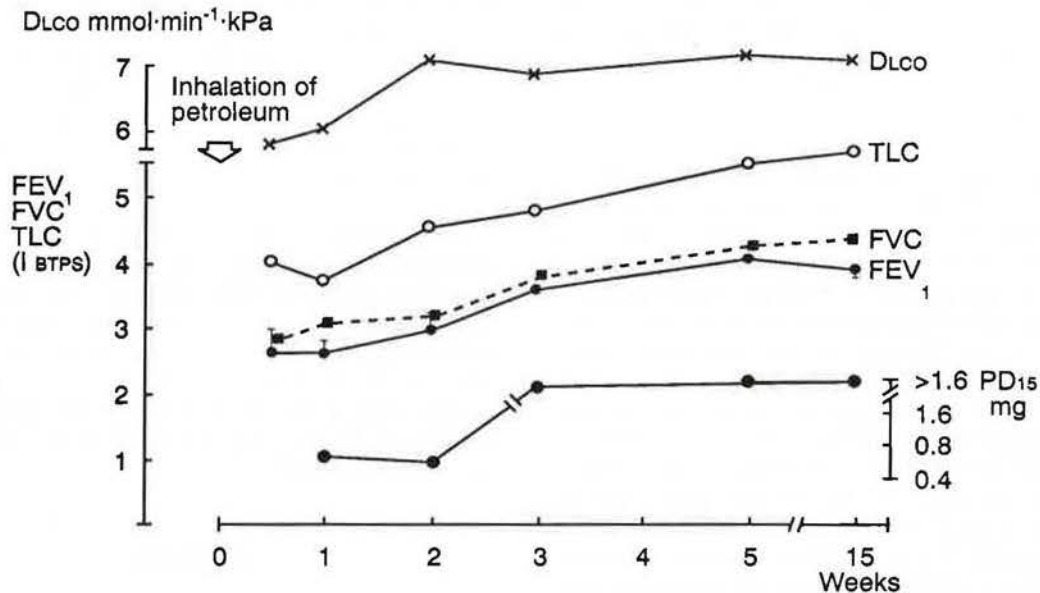


Fig. 2. - Lung volumes, diffusing capacity and bronchial responsiveness to histamine during a follow-up time of 3 months in patient 1. The first lung function examinations were performed 3 days after the accident. Slightly impaired values were observed during the first 2-3 weeks. DLco: diffusing capacity for carbon monoxide; TLC: total lung capacity; FVC: forced vital capacity; FEV₁: forced expiratory volume in one second. Bars denote response of FEV₁ to two puffs (=0.4 mg) of rimiterol. PD₁₅: provocative dose of histamine causing a 15% fall in the baseline FEV₁. PD₁₅-scale is logarithmic. The highest histamine dose used in the challenge was 1.6 mg. BTPS: body temperature pressure saturated.

After 2 weeks, the chest X-ray and the computer tomography (CT) scan showed several small cavities (<1.5 cm in diameter) in the bilateral dense lung infiltrates.

In the course of a few weeks the patient's symptoms disappeared, and lung volumes, diffusing capacity and bronchial responsiveness to histamine returned to normal (fig. 2). A thick-walled cavity 4 cm in diameter was still seen on both the CT scan (fig. 3) and on the chest X-ray 1.5-3 months after the accident. One year later only a tiny scar was noted at the site of the former cavity.

Patient 2

The patient was a 29 yr old smoking fire-eater working in a circus. In 1987 she was admitted to hospital after accidental aspiration of petroleum. On admission, the chest X-ray was normal. Some hours later fever, dyspnoea and right-sided chest pain developed, and a chest X-ray showed an infiltrate in the right middle and lower lobes. The CRP-value rose to $195 \text{ mg}\cdot\text{l}^{-1}$, the erythrocyte sedimentation rate to $61 \text{ mm}\cdot\text{h}^{-1}$, and the peripheral leucocyte count to $24.5 \times 10^9\cdot\text{l}^{-1}$, respectively. The patient was given parenteral cefuroxime and oral methylprednisolone.

still seen in the chest X-ray. After 2 months, the chest X-ray and the bronchofibroscopy findings were normal. BAL was not performed.

On examination 2 yrs after the accident the patient was symptom-free. Lung volumes, diffusing capacity, bronchial responsiveness to histamine and chest X-ray were normal. A CT scan revealed a small non-cavitary residual infiltrate in the basal right lung field.

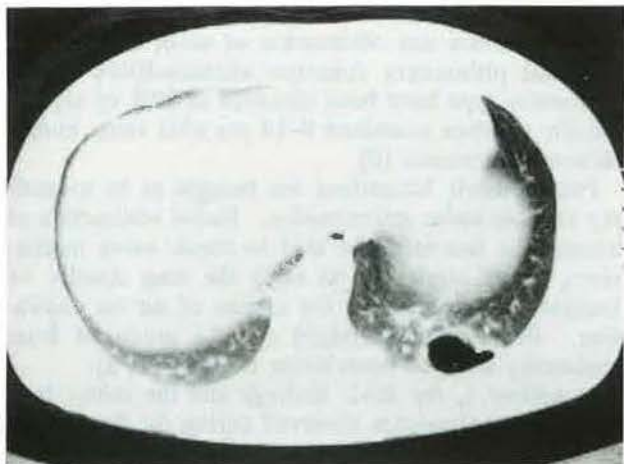


Fig. 3. - Computer tomography (CT) scan taken 1.5 months after the accident shows a cavity in the left lower lobe (patient 1).

Discussion

Seven analogous occupational accidents in fire-eaters have previously been reported [1-4]. The clinical picture has been similar to that seen in our cases. All the previously reported patients were treated with antibiotics and some of them also with systemic corticosteroids. All patients recovered clinically and the radiological infiltrates disappeared during a follow-up period of 1 week to 3 months. Lung function tests or bronchofibrescopy were not performed in any of these cases.

Liquid hydrocarbons are widely used both industrially and in households. In the USA, petroleum products accounted for 4-5% of accidental ingestions among small children [5]. Chemical pneumonitis resulting from the aspiration of hydrocarbon has been the most serious complication in these accidents. Symptomatic involvement of the respiratory tract occurs in 25-40% of patients after hydrocarbon ingestion. Symptoms and signs of lung involvement usually progress during the first 24 h after aspiration and subside during the following week. Acute mortality is less than 1% [6]. Radiological signs of pneumonitis develop within 12 h. Chest X-ray shows mottled or patchy, local or diffuse perihilar and basal uni- or bilateral infiltrates, areas of atelectasis and occasionally pleural effusions. Pneumatoceles often form in the areas of the densest infiltrations [7]. These cavities usually disappear in the course of a few weeks or months.

Pneumatocele formation was also observed in both our patients. Radiological resolution of the pneumatoceles occurred in the course of 2 months (patient 2) and 3-12 months (patient 1).

Histopathological examination of hydrocarbon pneumonitis has revealed an acute (within 24 h) exudative phase with intra-alveolar, intra- and peribronchiolar and interstitial exudation of inflammatory cells and oedema; and a later (within 1-2 weeks) phase with proliferative bronchiolitis and fibrosis. The proliferative phase of inflammation subsides in the course of a few weeks [5, 8]. It has been suggested that involvement of the small airways may progress to permanent fibrosis and obliteration of small airways [8]. Residual pulmonary function abnormalities of the obstructive type have been observed in 82% of asymptomatic children examined 8-14 yrs after acute hydrocarbon pneumonitis [9].

Pneumatocele formations are thought to be secondary to bronchiolar inflammation. Partial obstruction of bronchiolar lumen might lead to check valve mechanism, which allows air to enter the lung distally on inspiration and prevents the escape of air on expiration. Pneumatoceles might also be produced from coalescing areas of bronchiolar necrosis [7, 8].

In patient 1, the BAL findings and the minor lung function abnormalities observed during the first weeks

of illness were compatible with acute inflammatory lung and respiratory tract involvement. Vacuolated macrophages may be seen in toxic lung injuries.

Systemic corticosteroid and broad-spectrum antibiotic therapy is commonly used in the treatment of acute hydrocarbon pneumonitis, although there is no definite evidence of a beneficial effect [10, 11]. Corticosteroid treatment may even increase the risk of secondary bacterial infection [11]. There are no reports concerning the use of inhaled steroids in hydrocarbon pneumonitis. Anecdotally, however, a good response to treatment with inhaled steroids in acute lung injury caused by inhalation of toxic gases has been reported [12].

Occupational accidents with petroleum may not be uncommon in fire-eaters. The patients seem to recover well from the acute lung reaction. Recurrent inhalations of paraffin or mineral oil-based nasal drops may lead to lung fibrosis. It may be reasonable to assume, that recurrent petroleum aspirations might cause chronic lung injury by a similar mechanism. So far, the risk of chronic lung injury related to fire-eating has not been evaluated.

References

1. Beerman PG, Christensen T, Möller P, Stillström A. - Lipoid pneumonia: an occupational hazard of fire-eaters. *Br Med J*, 1984, 289, 1728-1729.
2. Iversen E, Christensen BE. - Lungekomplikationer hos "ildslugere". *Ugeskr Laeg*, 1984, 146, 26-27.
3. Pedersen B, Brons M, Jepsen JR. - Petroleum-pneumonitis som komplikation til ildpustning. *Ugeskr Laeg*, 1984, 146, 27-28.
4. Agrawal PG, Srivastava DK. - Hydrocarbon pneumonitis - a hazard in fire-eaters. *J Assoc Physicians India*, 1986, 34, 752.
5. Eade NR, Taussig LM, Marks MI. - Hydrocarbon pneumonitis. *Pediatrics*, 1974, 54, 351-359.
6. Machado B, Cross K, Snodgrass WR. - Accidental hydrocarbon ingestion cases telephoned to a regional poison center. *Ann Emerg Med*, 1988, 17, 804-807.
7. Bergeson PS, Hales SW, Lustgarten MD, Lipow HW. - Pneumatoceles following hydrocarbon ingestion. *Am J Dis Child*, 1975, 129, 49-54.
8. Scharf M, Prinsloo I. - Pulmonary mechanics in dogs given different doses of kerosene intratracheally. *Am Rev Respir Dis*, 1982, 126, 695-700.
9. Brown J, Burke B, Dajani AS. - Experimental kerosene pneumonia: evaluation of some therapeutic regimens. *J Pediatr*, 1974, 84, 396-401.
10. Steele RW, Conklin RH, Mark HM. - Corticosteroids and antibiotics for the treatment of fulminant hydrocarbon aspiration. *J Am Med Assoc*, 1972, 219, 1434-1437.
11. Gurwitz D, Kattan M, Levison H, Culham JAG. - Pulmonary function abnormalities in asymptomatic children after hydrocarbon pneumonitis. *Pediatrics*, 1978, 62, 789-794.
12. Müller-Esch G, Brunk E, Djonlagic H, Hoffman J, Wiessman KJ. - Inhalationstoxikation durch Lederimprägnationsmittel. *Dtsch Med Wochenschr*, 1982, 107, 692-695.