To verify this hypothesis, one could sequence the *TINF2* gene of the patient with DNA from other tissue, a buccal swab and/or a lung sample, where the mutation would probably appear as ''really'' heterozygous. In addition, high throughput sequencing (with next-generation sequencing) of *TINF2* in DNA from the patient's blood should provide precise data on the mutation frequency. However, one cannot definitely exclude the fact that *TINF2* mutations could lead to far more heterogeneous clinical phenotypes than previously described.

@ERSpublications
A TINF2 mutation with somatic reversion may be revealed in adults with pulmonary fibrosis
http://ow.ly/vcOaW

Caroline Kannengiesser[1], Raphael Borie[2,3] and Patrick Revy[4,5]
[1]Assistance Publique des Hôpitaux de Paris, Hôpital Bichat, Service de Génétique, Université Paris Diderot, Paris, France. [2]Assistance Publique Hôpitaux de Paris, Hôpital Bichat, Service de Pneumologie A, Centre de Compétence Maladies Rares Pulmonaires, DHU FIRE, Paris, France. [3]INSERM, Unité 1152, Faculté Bichat, Université Paris 7, Paris, France. [4]INSERM UMR 1163, Laboratory of Genome Dynamics in the Immune System, Université Paris Descartes, Paris, France. [5]Sorbonne Paris Cité University, Imagine Institute, Paris, France.

Correspondence: Raphael Borie, Hopital Bichat, Service de Pneumologie A, 46 rue Henri Huchard, Paris 75877 Cedex 18, France. E-mail: raphael.borie@bch.aphp.fr

Received: Feb 26 2014 | Accepted: Feb 27 2014

Conflict of interest: None declared.

References

1 Fukuhara A, Tanino Y, Ishii T, *et al.* Pulmonary fibrosis in dyskeratosis congenita with *TINF*2 gene mutation. *Eur Respir J* 2013; 42: 1757–1759.
2 Armanios MY, Chen JJ, Cogan JD, *et al.* Telomerase mutations in families with idiopathic pulmonary fibrosis. *N Engl J Med* 2007; 356: 1317–1326.
3 van Moorsel CH, van Oosterhout MF, Barlo NP, *et al.* Surfactant protein C mutations are the basis of a significant portion of adult familial pulmonary fibrosis in a Dutch cohort. *Am J Respir Crit Care Med* 2010; 182: 1419–1425.
4 Walne AJ, Vulliamy T, Beswick R, *et al.* TINF2 mutations result in very short telomeres: analysis of a large cohort of patients with dyskeratosis congenita and related bone marrow failure syndromes. *Blood* 2008; 112: 3594–3600.
5 Yamaguchi H, Inokuchi K, Takeuchi J, *et al.* Identification of TINF2 gene mutations in adult Japanese patients with acquired bone marrow failure syndromes. *Br J Haematol* 2010; 150: 725–727.
6 Jongmans MC, Verwiel ET, Heijdra Y, *et al.* Revertant somatic mosaicism by mitotic recombination in dyskeratosis congenita. *Am J Hum Genet* 2012; 90: 426–433.

Eur Respir J 2014; 44: 269–270 | DOI: 10.1183/09031936.00038714 | Copyright ©ERS 2014

From the authors:

We would like to thank C. Kannengiesser and co-workers for their interest in our article [1] and for their patient's information and comments. They showed that their patient with the *TINF2* (telomerase repeat binding factor 1-interacting nuclear factor 2) mutation had the heterozygous mutation, which is usually seen in young patients with dyskeratosis congenita. In addition, they suggested that a somatic reversion might have occurred in our case because figure 1b showed that the deletion was not heterozygous despite the late disease onset [1].

Somatic reversion is a possible mechanism, which may explain late disease onset of dyskeratosis congenita with the *TINF2* mutation. In fact, Jongmans *et al.* [2] described dyskeratosis congenita in a patient with somatic reversion. In this patient, the wild-type allele was observed more than the mutated allele in DNA from his peripheral blood cells despite DNA from his lung tissues revealing heterozygous mutation.

In our case, figure 1b showed n871–874 tetranucleotide AGGA deletion in *TINF2* gene [1]. However, because the mutation was a deletion mutation, TA cloning was performed for this analysis as described previously [3]. The result of gene mutation analysis by direct sequencing before TA cloning showed that the mutation was heterozygous (fig. 1). Although it may be possible that somatic reversion of the cells in the lungs led to pulmonary fibrosis in our patient, unfortunately we could not analyse DNA from lung tissues because the patient had passed away and no lung tissue had been retained.

More cases are needed to determine the exact mechanism(s) of dyskeratosis congenita by analysing each affected organ/system in detail.

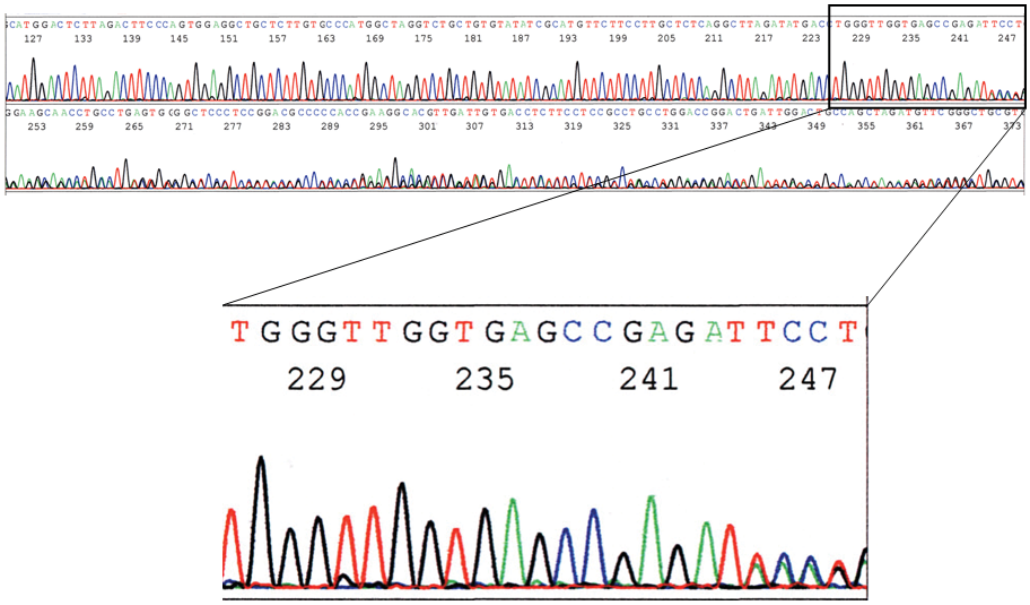

FIGURE 1 Gene mutation analysis of DNA from the peripheral blood cells by direct sequencing before TA cloning showed heterozygous gene mutation.

@ERSpublications
Sequencing analysis of blood cells didn't show somatic reversion; a possible mechanism explaining late disease onset http://ow.ly/vhFLu

Yoshinori Tanino[1], Hiroki Yamaguchi[2], Atsuro Fukuhara[1] and Mitsuru Munakata[1]
[1]Dept of Pulmonary Medicine, School of Medicine, Fukushima Medical University, Fukushima, Japan. [2]Division of Hematology, Dept of Internal Medicine, Nippon Medical School, Tokyo, Japan.

Correspondence: Yoshinori Tanino, Dept of Pulmonary Medicine, School of Medicine, Fukushima Medical University, 1 Hikarigaoka, Fukushima-City 960-1295, Japan. E-mail: ytanino@fmu.ac.jp

Received: March 18 2014 | Accepted: March 18 2014

Conflict of interest: None declared.

References

1 Fukuhara A, Tanino Y, Ishii T, *et al.* Pulmonary fibrosis in dyskeratosis congenita with *TINF2* gene mutation. *Eur Respir J* 2013; 42: 1757–1759.
2 Jongmans MC, Verwiel ET, Heijdra Y, *et al.* Revertant somatic mosaicism by mitotic recombination in dyskeratosis congenita. *Am J Hum Genet* 2012; 90: 426–433.
3 Yamaguchi H, Inokuchi K, Takeuchi J, *et al.* Identification of *TINF2* gene mutations in adult Japanese patients with acquired bone marrow failure syndromes. *Br J Haematol* 2010; 150: 725–727.