

## Dyspnoea after pneumonectomy

F.W.J.M. Smeenk\*, S.P.M. Twisk\*\*, E. Berreklouw†,  
H.Ch. Gooszen††, P.E. Postmus\*

### Case presentation

In August 1988 a 61 yr old male was referred because of severe dyspnoea. The dyspnoea of the patient appeared to be less severe in the right lateral recumbent position, but worsened in the upright position and during exercise.

Two months before referral the patient underwent a left-sided intra-pericardial pneumonectomy because of a squamous cell carcinoma of the left upper lobe. During the operation the inferior and superior pulmonary veins were ligated as close to the left atrium as possible.

At physical examination, while the patient was in the supine position, we saw a cyanotic man with a blood pressure of 105/70 mmHg and a regular pulse rate of 92 beats·min<sup>-1</sup>. The central venous pressure was not elevated. Examination of the thorax revealed dullness over the left hemithorax and normal breath sounds over the right lung. The heart sounds were normal.

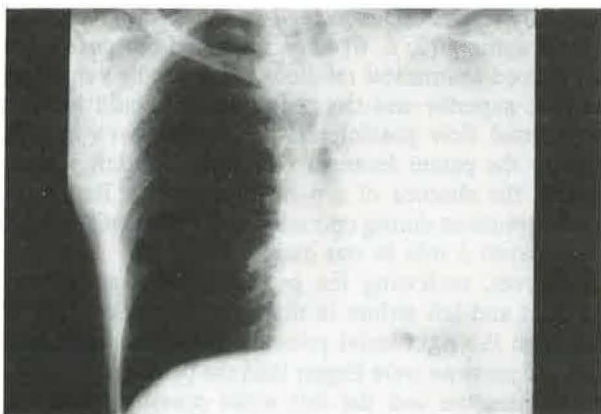


Fig. 1. - PA chest X-ray of the patient two months after a left pneumonectomy. PA: posteroanterior.

Table 1. - Cardiac catheterization data

Position	Oxygen sat. %	Pressure mmHg
Vena cava inferior	30	
Vena cava superior	32	
Right atrium	32	m=4
Right ventricle	30.5	18/4
Pulmonary artery	34	18/4; m=10
Pulmonary artery wedge	80.5	m=2
Vena pulmonalis	88	
Left atrium	65.5	m=3
Aorta	68.5	

m: mean; sat: saturation.

Arterial blood gas analysis, taken from the patient while he was sitting, showed a severe hypoxaemia (pH 7.34, carbon dioxide tension (Pco<sub>2</sub>) 4.4 kPa, oxygen tension (Po<sub>2</sub>) 5.3 kPa, base excess -2.1 mmol·l<sup>-1</sup>). After inhalation of 100% oxygen during 30 min, the arterial Po<sub>2</sub> rose 2 kPa.

The posteroanterior (PA) chest X-ray (fig. 1) showed the situation after a left-sided pneumonectomy with a shift of the mediastinal structures to the left. No abnormalities were seen on the right side. To exclude pulmonary emboli as a possible cause of this severe hypoxaemia, a ventilation-perfusion scintigram was performed. No perfusion defects in the right lung were seen; however, the uptake of the isotope in the brain and kidneys was early.

A heart catheterization was performed (with the patient in the supine position). Pressures and oxygen saturations found with this procedure are shown in table 1. Normal right-sided heart pressures were found.

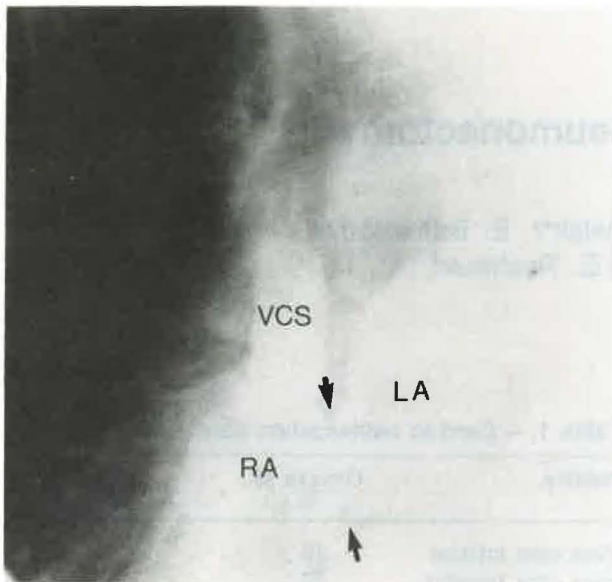


Fig. 2. – Cine-angiogram with injection of contrast in the vena cava superior. RA: right atrium; LA: left atrium; VCS: vena cava superior. The arrow indicates the orifice of the patent foramen ovale.

#### Further diagnostic tests

Because of the finding during the ventilation-perfusion scintigraphy that the uptake in the brain and kidneys was very early, a right-to-left shunt was suspected. The presence of right-to-left shunt was confirmed by means of the 100% oxygen breathing test.

An echocardiogram was technically impossible in this patient and, therefore, heart catheterization was performed. With the catheter it was possible to enter the left atrium. Because of the oxygen saturations found in the right atrium (32%), the left atrium (65.5%) and the vena pulmonales (88%), the right-to-left shunt must be located at the atrial level. A cine-angiogram with injection of contrast in the vena cava superior confirmed this (fig. 2).

#### Diagnosis

Severe right-to-left shunt through a patent foramen ovale which developed after pneumonectomy was diagnosed. Because of these findings our patient was operated on, and a patent foramen ovale was found. It seemed that the valve of the foramen ovale was too small to cover the whole opening of the foramen ovale, probably due to traction of the atrial septum upon the valve by the "sagging" of the wall of the left atrium into the pneumonectomy space. After closure, the postoperative course was uneventful. At discharge the patient's arterial oxygen tension was 10 kPa

and after breathing of 100% oxygen during 30 min 68 kPa, so that a significant right-to-left shunt was excluded.

#### Discussion

SCHNABEL *et al.* [1] were first to report, in 1956, on the development of an interatrial right-to-left shunt in the absence of elevated right-sided heart pressures in a patient after a right-sided pneumonectomy. Since then, several case reports concerning the same complication developing after a pneumonectomy have been published. Three case reports describe this complication developing after a right-sided pneumonectomy [2–4], three after a left-sided pneumonectomy [5–7], and only one after a lobectomy of the right middle and lower lobe [8]. The most striking characteristics of this complication are: Firstly, the symptom free period between the operation and the occurrence of the first complaints (between 1 and 5 mths [1, 5]). In two patients it was seen within one week after the operation [3, 8]. Secondly, the dyspnoea and the right-to-left shunt depended on the position of the patient. It appeared that the dyspnoea and the shunt became more severe in the upright position than in the recumbent position [1–7]. This phenomenon is known as "platypnoea". A third reported characteristic of this complication is "the volume-dependancy" of the shunt: it becomes greater with volume depletion [2, 3, 5, 7].

The underlying pathogenetic mechanism causing this complication is not yet fully understood. Referring to the observation [9] that a right-to-left shunt can also appear in patients with an atrial septum defect (ASD) in the absence of elevated right-sided heart pressures, especially if the ASD is located low in the atrial septum, several authors [2, 6, 8] have indicated the possibility that altered anatomical relations between the vena cava inferior, superior and the atrial septum could make a preferential flow possible from the vena cava inferior through the patent foramen ovale into the left atrium, even in the absence of a pressure gradient. Regarding the observations during operation, this mechanism could have played a role in our patient.

However, reviewing the pressure relations between the right and left atrium in this case more closely, it is clear that the right atrial pressure and right ventricular diastolic pressure were higher than the pulmonary artery wedge pressure and the left atrial pressure, which is unusual [10]. This can be encountered, for example, in situations where the right ventricular afterload is increased as was shown in an animal model by BERGLUND [10]. Furthermore, the right-to-left shunt in our patient appeared to be approximately 25%, indicating that the right ventricular output was 25% lower than the left ventricular output. Because of the low oxygen saturation in the right atrium (32%), the left ventricular output was probably low too. This means that the right ventricular output had to be very low in our patient and, taking this low right ventricular output into account, the right atrial pressure and right ventricular filling



pressure of 4 mmHg (although quantitatively within normal physiological limits) in our patient are probably pathologically high.

These observations indicate that in our patient the right ventricular afterload was probably sufficiently increased by the pneumonectomy to elevate the right ventricular filling pressure above the left ventricular filling pressure, thereby making a shunt possible between the right and left atrium in the presence of a patent foramen ovale.

This mechanism of a right-to-left shunt through a patent foramen ovale in situations of increased right ventricular afterload has already been reported by others [11]. It can be elicited not only by a pneumonectomy but also by other conditions known to elevate right ventricular afterload [12, 13].

In view of the high incidence (20%) of a patent foramen ovale found in the general population, it could be possible that this complication occurs more frequently, but in a less serious form, than is expected regarding the number of reports. An important clinical clue for the diagnosis of this complication is the "platypnoea". Right-to-left shunt detection can easily be performed by a 100% oxygen inhalation test. Usually the simplest way to establish the diagnosis is a contrast or Doppler echocardiography [14].

#### References

1. Schnabel TG, Ratto O, Kirby CK *et al.* – Postural cyanosis and angina pectoris following pneumonectomy: relief by closure of an interatrial septum defect. *J Thorac Surg*, 1956, 32, 246–250.
2. Franco DP, Kinasevitz GT, Markham RV *et al.* – Postural hypoxemia in the postpneumonectomy patient. *Am Rev Respir Dis*, 1984, 129, 1021–1022.
3. O'Connor JM, Eshleman JD. – Platypnea-Orthodeoxia after pneumonectomy: a case report. *Respir Care*, 1986, 31, 1211–1213.
4. Rossum van P, Plokker HWM, Ascoop CAPL. – Breathlessness and hypoxemia in the upright position after right pneumonectomy. *Eur Heart J*, 1988, 9, 1230–1233.
5. LaBresh KA, Pietro DA, Coates EO *et al.* – Platypnea syndrome after left pneumonectomy. *Chest*, 1981, 79, 605–607.
6. Roos CM, Romijn KH, Braat MCP, Leeuwen van AM. – Posture-dependent dyspnea and cyanosis after pneumonectomy. *Eur J Respir Dis*, 1981, 62, 377–382.
7. Wranne B, Tolagen K. – Platypnea after pneumonectomy caused by a combination of intracardiac right-to-left shunt and hypovolaemia. *Cardiovasc Surg*, 1978, 12, 129–131.
8. Vacek JL, Foster J, Quinton RR *et al.* – Right-to-left shunting after lobectomy through a patent foramen ovale. *Ann Thorac Surg*, 1985, 39, 576–578.
9. Danilowicz D. – Determinants of atrial right-to-left shunting. *Cardiovasc Med*, 1979, 4, 925–931.
10. Berglund E. – VI. Balance of left and right ventricular output: relation between left and right atrial pressures. *Am J Physiol*, 1954, 178, 381–386.
11. Berglund E. – Right-to-left intracardiac shunt in obstructive lung disease. *Eur J Respir Dis*, 1981, 62, 371–372.
12. Begin R, Gervais A, Guerin L, Bureau MA. – Patent foramen ovale and hypoxemia in chronic obstructive lung disease. *Eur J Respir Dis*, 1981, 62, 373–376.
13. Seward JB, Hayes DL, Smith HC *et al.* – Platypnea-orthodeoxia: clinical profile, diagnostic work-up, management, and report of seven cases. *Mayo Clin Proc*, 1984, 59, 221–231.
14. Chakko SC, Springer RM, Gheorghiadu M. – The role of contrast echocardiography in the differential diagnosis of platypnea. *J Cardiovasc Ultrasonography*, 1985, 4, 139–142.

Keywords: Hypoxaemia; platypnoea; pneumonectomy; shunt.

*Dyspnoea after pneumonectomy.* F.W.J.M. Smeenk, S.P.M. Twisk, E. Berreklouw, H.Ch. Gooszen, P.E. Postmus.

**ABSTRACT:** We report the case of a 61 yr old male, who developed a severe right-to-left shunt through a patent foramen ovale, in the absence of elevated right-sided heart pressures, two months after a left-sided pneumonectomy. This is considered to be a rare complication after pneumonectomy. However, taking into account the approximately 20% incidence of patent foramen ovale in the general population, we suggest that right-to-left shunting through an unsuspected foramen ovale or atrial septum defect should always be considered as a possible cause of otherwise unexplained hypoxaemia.

*Eur Respir J.*, 1991, 4, 243–245.

*Cas pour diagnostic: dyspnée après pneumonectomie.* F.W.J.M. Smeenk, S.P.M. Twisk, E. Berreklouw, H.Ch. Gooszen, P.E. Postmus.

**RÉSUMÉ:** Exposé du cas d'un homme de 61 ans, qui a développé un shunt droit-gauche au niveau d'un foramen ovale ouvert, en l'absence de pression élevée au niveau du coeur droit, deux mois après une pneumonectomie gauche. Cette complication après pneumonectomie, est considérée comme rare. Toutefois, en prenant en compte l'incidence d'environ 20% des foramen ovales patents dans la population générale, nous suggérons que le shunt droit-gauche au travers d'un foramen ovale non suspecté ou au travers d'une communication par défaut du septum atrial, devrait toujours être pris en considération comme cause possible d'une hypoxie par ailleurs inexpiquée.

*Eur Respir J.*, 1991, 4, 243–245.