

Human pulmonary infection with *Corynebacterium equi*

T. Egawa*, H. Hara*, I. Kawase*, T. Masuno*, S. Asari**, M. Sakurai***, S. Kishimoto*

Human pulmonary infection with Corynebacterium equi. T. Egawa, H. Hara, I. Kawase, T. Masuno, S. Asari, M. Sakurai, S. Kishimoto.

ABSTRACT: A 28 year old man with no underlying disease developed a cavity and multiple nodules in the lung from which *Corynebacterium equi* was isolated. He experimented with organic solvents and microorganisms including *Corynebacterium* species for several years. Computed tomography of his pulmonary lesions revealed that these nodules were related to the bronchial tree. Histologically, the lesions were compatible with nonspecific inflammatory changes. The clinician must suspect the pulmonary infections with *Corynebacterium* species even if the patient has no underlying disease.

Eur Respir J., 1990, 3, 240-242.

* Third Dept of Internal Medicine,
** Central Laboratory for Clinical Investigation,
*** Dept of Pathology, Osaka University Hospital,
Osaka, Japan.

Correspondence: T. Egawa, The Third Department of Internal Medicine, Osaka University Hospital, Fukushima, Osaka, 553, Japan

Keywords: Bronchoalveolar lavage; *corynebacterium equi*; pneumonitis.

Received: December 1, 1988; accepted after revision September 8, 1989.

The bacteria belonging to the *Corynebacterium* (*C.*) species (other than *C. diphtheriae*) are common inhabitants of human skin, oropharynx and in soil. Some of *C.* species are animal pathogens well known to veterinarians, which cause abscess and proliferative granulomatous responses with caseations [1, 2]. As for human beings, immunosuppressive state accompanied by malignant tumours, AIDS, ageing or drug usages such as prednisolone may be responsible for the respiratory infections of these organisms considered to have no pathogenicity. The outcome of this infection is fatal in many cases.

We have recently observed multiple nodules and a cavity caused by the bacteria belonging to the *C.* species in the lung of a patient with no underlying disease.

Case Report

A 28 year old man with no history of atopy was referred to Osaka University Hospital in October 1987 for diagnosis and treatment of lung abnormal shadows. He was a smoker and a student at a graduate school of agriculture. He experimented with microorganisms and organic solvents, such as ethyl acetate, chloroform and acetone, for extracting polysaccharides of microbial cell walls. His laboratory was heavily contaminated with these materials.

He presented to another hospital six months previously with a several-week history of productive cough, purulent sputa, malaise and exertional dyspnoea. He was treated with Minocycline and Piperacillin for a month.

Three months later, he relapsed the same symptoms with right chest pain. On admission to our hospital, he had rales at right middle lung field, leukocytosis and increased serum IgE level ($4,220 \text{ U}\cdot\text{ml}^{-1}$). His pulmonary functions, including single-breath diffusing capacity, forced expiratory flows and lung volume, indicated normal values. His chest roentgenogram showed multiple nodular shadows especially in the bilateral upper and middle lung fields (fig. 1a). Pulmonary computed tomography (CT) showed a cavity in S^{1+3} of the left lung and multiple nodules related with bronchi in the whole lung field (fig. 2a, 2b).

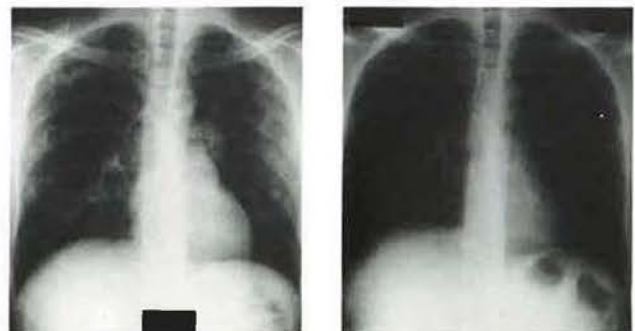


Fig. 1. - Chest roentgenogram (a) on admission. Multiple nodular infiltrates were noted in bilateral upper and middle lung fields without pleural effusion. (b) Gradual clearing was noted after treatments.

Mantoux test was positive and skin tests for fungi were negative. Radio-allergo-sorbent tests against a variety of antigens were negative. Neither precipitating antiviral nor autoantibodies were detected. Aerobic and anaerobic blood cultures remained sterile. Neither β -glucan nor endotoxin in serum were detected.

An open lung biopsy revealed multiple small hard nodules in the whole lobe. Histologically, there were multiple fibrous nodules in the lung parenchyma constituted with proliferation of fibroblasts, capillary endothelial cells, haemosiderin laden macrophages and lymphocytes compatible with nonspecific inflammatory changes (fig. 3). Although cultures from sputa and bronchoalveolar lavage (BAL) grew *Pseudomonas aeruginosa*, *Klebsiella*, α -streptococcus, *Candida albicans* and *C. species*, only *C. equi* were found and grew from the specimen of the thoracotomy.

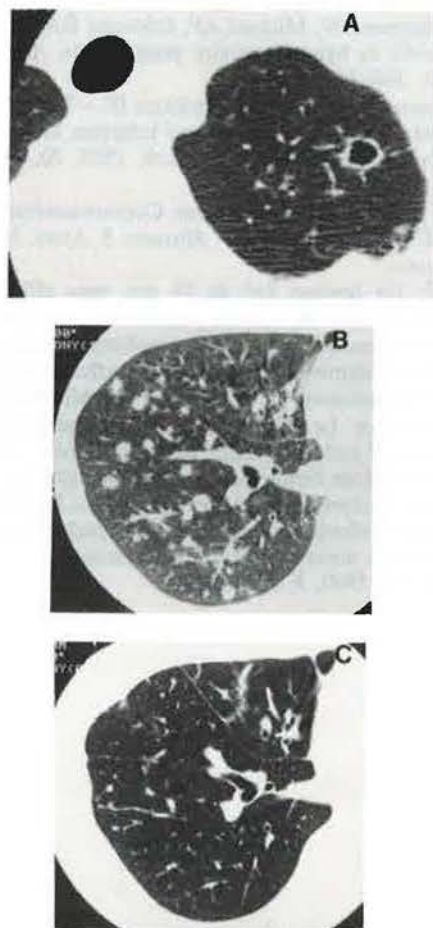


Fig. 2. - Computed tomographies of the lung revealed a) a cavity in the left upper lobe S¹⁺³ and b) multiple nodules which related to the bronchial tree. c) After treatment, these lesions disappeared.

The patient was treated with Ofloxacin, Cefsulodin and Latamoxef for 10 days. His chest roentgenogram became gradually clear after these treatments (fig. 1b). Drugs used were changed to Ofloxacin and Ticarcillin and continued for a month. Progressive improvement of his symptoms and disappearance of the cavity were noted by comparing the pulmonary CT taken before the treatment with that after the treatment (fig. 2b, 2c).

Bronchoalveolar lavage

Bronchoalveolar lavage (BAL) was performed in the left lingula with 300 ml of 0.9% sodium chloride, and 200 ml were aspirated by gentle suction (67% return). The cells recovered were separated by centrifugation, washed and resuspended in Hank's balanced solution at a concentration of 10×10^6 cells·ml⁻¹. A small portion was taken for determination of cell numbers, viability and differential counting. The percentage of T-cells was defined as those forming erythrocyte (E) rosettes with sheep red blood cells (SRBC). The percentage of B-cells was defined as those forming rosettes with SRBC (E)-rabbit IgM-anti SRBC antibody (A)-mouse serum complement (C) complexes (EAC rosettes). The T-cells from BAL of our patient were tested for their reactivity to murine monoclonal antibodies (OKT3, OKT4, OKT8 and Leu11) by indirect immunofluorescence staining.

BAL analysis of our case is presented in Table 1. Total cell recovery was 13.6×10^6 cells. Differential cell count showed 97% macrophages and 3% other cells with 84% T-cells, 2% B-cells. The predominant T-cell subset was T-suppressor/cytotoxic. The T4/T8 ratio was 0.54.

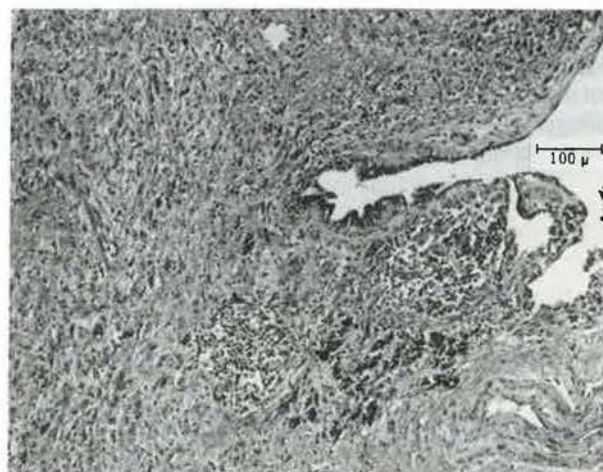

Fig. 3. - Histologic section of the lung showed fibrous nodule with moderate lymphocytic infiltration and capillary endothelial proliferation compatible with nonspecific inflammatory changes.

Table 1. - Lymphocyte subpopulations in bronchoalveolar lavage fluid (BAL) and blood of a patient with *Corynebacterium equi* pneumonia

	Lymphocytes		Analyses of T-cell			Subpopulations	
	T-cell	B-cell	OKT3	OKT4	OKT8	OKT4/OKT8	Leu11
BAL	2%	84%	86%	31%	58%	0.54	5.1%
Blood	10%	78%	70%	36%	31%	1.16	13.4%

Discussion

Forty seven cases of pneumonia or pneumonitis caused by *Corynebacterium* (C.) species are reported in the literature. *C. equi*, *C. pseudotuberculosis*, *C. Pseudodiphthericum* (*C. hofmanii*), *C. pyogenes*, C. group JK and *C. cervicis* are reported pathogens of human pulmonary infections.

In the present case, the mucosa of the respiratory tract was injured by organic solvents which he used and the normal defence mechanisms of the tracts such as mucocilliary escalator were damaged [3]. Therefore, the tract might be easily infected and sensitized by microorganisms which had no virulence to man and nonspecific inflammatory changes were caused in the lung.

The T4/T8 ratio in BAL is 0.54 which is lower than the ratio of 1.16 in his blood and the reported normal ratio of approximately 1.5–1.8 in BAL [4]. The percentage of T- or B-cells and the T4/T8 ratio in his blood are similar to the reported normal values. The clinical significance of this data is unknown but they may only reflect the phase of disease or the effect of the treatments.

Corynebacterium species as presently constituted are a heterogeneous group of microorganisms, some of which are only distantly related [1]. Although the pathogenesis of these bacteria in general populations has not clearly delineated, lysosomal enzymes in the bacteria may play a crucial role in tissue destructions and granuloma formations [7].

As demonstrated by our case, a pulmonary infection due to *Corynebacterium* species occurs in a man with no underlying disease when the environments are vigorously contaminated. We would like to reinforce the potential pathogenicity of the Coryneform bacteria, and particular notice should be taken of their presence when the

clinician observes multiple nodular shadows on a chest roentgenogram.

References

1. Lipsky BA, Goldberger AC, Tompkins LS, Plorde JJ. – Infections caused by nondiphtheria *Corynebacteria*. *Rev Infect Dis*, 1982, 4, 1220–1235.
2. Smith BP, Robinson RC. – Studies of an outbreak of *Corynebacterium equi* pneumonia in foals. *Equine Vet J*, 1981, 13, 223–228.
3. Green GM, Jakab GJ, Low RB, Davis GS. – Defence mechanisms of the respiratory membrane. *Am Rev Respir Dis*, 1977, 115, 479–514.
4. Reynolds HY. – Bronchoalveolar lavage. *Am Rev Respir Dis*, 1987, 135, 250–263.
5. Hunninghake GW, Crystal RG. – Pulmonary sarcoidosis: a disorder mediated by excess helper T-lymphocyte activity at sites of disease activity. *N Engl J Med*, 1981, 429–434.
6. Leatherman JW, Michael AF, Schwartz BA, Hoidal JR. – Lung T cells in hypersensitivity pneumonitis. *Ann Int Med*, 1984, 100, 390–392.
7. Johnson JA, Prescott JF, Markham JF. – The pathology of experimental *Corynebacterium equi* infection in foals following intrabronchial challenge. *Vet Path*, 1983, 20, 440–449.

Infection pulmonaire humaine par Corynebacterium equi. T. Egawa, H. Hara, I. Kawase, T. Masuno, S. Asari, M. Sakurai, S. Kishimoto.

RÉSUMÉ: Un homme âgé de 28 ans, sans affection sous-jacente, développe, au niveau pulmonaire, une cavité et de multiples nodules, dans lesquels *Corynebacterium equi* est isolé. Il travaillait expérimentalement avec des solvants organiques et des micro-organismes, y compris des corynébactéries, depuis plusieurs années. Le CT scan de ses lésions pulmonaires a montré que les nodules étaient en relation avec l'arbre bronchique. Les lésions histologiques étaient compatibles avec des modifications inflammatoires non spécifiques. Le clinicien doit suspecter une infection pulmonaire à *Corynebacterium*, même si le patient n'a aucune affection sous-jacente. *Eur Respir J.*, 1990, 3, 240–242.