

## Lethal extrapulmonary mycobacteriosis

S. Kos\*, J. Důra\*\*, J. Jirásek\*\*\*

*Lethal extrapulmonary mycobacteriosis. S. Kos, J. Důra, J. Jirásek.*

**ABSTRACT:** A 60 yr old previously healthy man was treated for gradually elevating fever and rash followed by leucopenia and mycosis of the gastrointestinal tract; he died within 6 weeks of the first symptoms appearing. Histologic examination revealed disseminated tuberculosis of paratracheal lymph nodes, liver, spleen and bone marrow with the presence of acid fast bacilli by smear examination. Multiple colonies of the same strain of *Mycobacterium kansasii* were isolated by bacteriological examination of lymph node and spleen tissue. Neither macroscopical nor histological examination showed any evidence of lung tuberculosis. The final diagnosis of the described acute disease and rapid death was stated as generalized extrapulmonary mycobacteriosis, which is a rare observation.

*Eur Respir J.*, 1989, 2, 96-97.

\*Department of Tuberculosis and Respiratory Diseases, Faculty Hospital, Plzen, Czechoslovakia.

\*\*Department of Pathological Anatomy, Faculty Hospital, Plzen, Czechoslovakia.

\*\*\*Mycobacteriological Laboratory, District Hygienic Station, Plzen-Janov, Czechoslovakia.

Correspondence: Dr. S. Kos, Department of TB and Respiratory Diseases, Faculty Hospital, 305 99 Plzen, Czechoslovakia.

Keywords: Extrapulmonary mycobacteriosis; *Mycobacterium kansasii*.

For several decades increased attention has been paid to both pulmonary and extrapulmonary diseases caused by mycobacteria other than *Mycobacterium tuberculosis*. These mycobacteria can colonize, infect, or cause disease [1]. Colonization usually means that a microorganism is isolated without any apparent change in the host. Infection implies that the host reacts by producing antibodies or a skin reaction but presents no overt manifestation of disease. The disease indicates that some form of tissue destruction has occurred, such as radiographic change, or abscess formation [2].

### Case report

A 60 yr old male, nonsmoker, with a personal, professional and family history of no relevance, had felt ill since the end of February, 1985 (weakness, arthralgia, pyrexia of 38°C and perspiration). He was treated for influenza with aspirin, but after one week the fever increased and maculopapulous exanthema developed in his face, extending to the rest of his body within a few days. He was admitted to the Department of Dermatology. Physical examination showed no substantial abnormalities except rash, fever, perspiration and loss of weight. Laboratory examination showed a raised ESR (34/80 mm), slight leucopenia ( $2.5 \times 10^9 l^{-1}$ ) and moderate lymphocytosis (0.48-0.62). An HIV-test was not performed because of the age of the patient and with respect of the very low incidence of AIDS in Czechoslovakia. A Chest radiograph revealed no infiltrative or other pathological changes. The preliminary diagnosis was

erythema exsudativum multiforme (Hebrae). In addition to local therapy he received antibiotics, corticosteroids (Triamcinolone 40 mg per day), antihistamines and vitamins.

The clinical status of the patient gradually deteriorated, the skin eruptions fused, and the fever became septic. After three weeks of dermatological examination and treatment he was assumed to suffer from a toxic-allergic reaction. As haematological findings further deteriorated the patient was transferred to the Haematological Department. The haematological findings made us suspect bone marrow suppression (idiopathic or secondary) or an acute aleukaemic haemoblastosis. Repeated bone marrow aspirations revealed that the marrow was severely hypocellular with residual elements of normal haemopoiesis, atypical lymphoid elements and naked nuclei. The patient developed serious difficulty in swallowing owing to generalized mycosis of the gastrointestinal tract. The fever persisted at 40°C in spite of high doses of corticosteroids and other symptomatic treatment; the patient finally died on April 15th, 1985, one and a half months after the first symptoms had appeared.

At autopsy the main diagnosis was: disseminated caseous productive tuberculosis of the paratracheal lymph nodes including the presence of numerous acid-fast bacilli stained by the Ziehl-Neelsen method (fig. 1a and 1b), and miliary caseous dissemination in the spleen (fig. 2), liver (fig. 3) and bone marrow (fig. 4). In the bone marrow only erythropoiesis was found; due to serious depression of leucopoiesis the patient developed candidiasis of his tongue and stomach with ulcerative phlegmatous gastritis followed by sepsis. The immediate cause of death

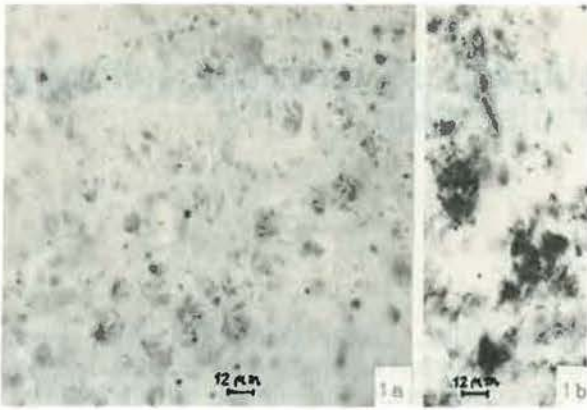


Fig. 1. - (a) Solitary Mycobacteria in caseous necrosis of lymphatic node. (b) Groups of Mycobacteria. Ziehl-Neelsen.

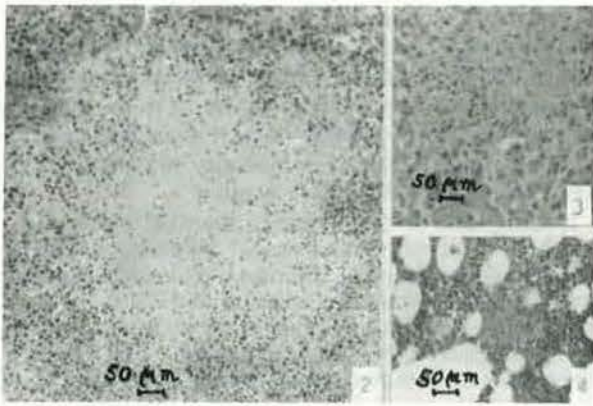


Fig. 2. - Confluent miliary caseous necrosis in the spleen. Haematoxylin-eosin.

Fig. 3. - Miliary caseous necrosis in the liver (in the upper part of the figure). Haematoxylin-eosin.

Fig. 4. - Miliary caseous necrosis in bone marrow. Haematoxylin-eosin.

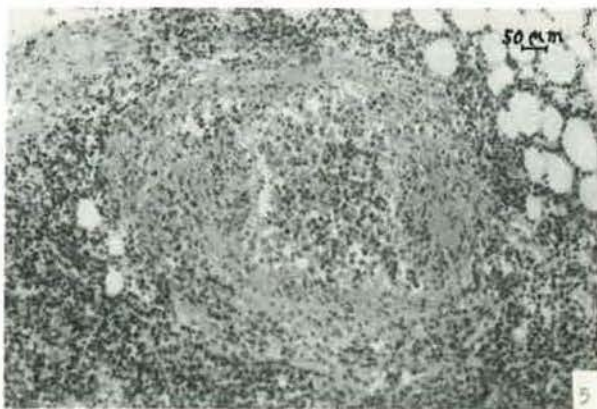


Fig. 5. - Caseous phlebitis. Haematoxylin-eosin

was cardiac dilatation with severe pulmonary oedema. The haematogenic spread was attributed to a specific phlebitis found in the neighbourhood of the paratracheal lymph nodes (fig. 5). At the site of the toxic-allergic skin eruptions there was a capillary thrombosis and pericapillaritis. Neither macroscopically nor microscopically was any trace of tuberculosis found in the lungs.

Bacteriological examination of the spleen and lymph node tissue showed acid fast bacilli in smear preparations. After culture on Löwnstein-Jensen medium, the same strain of *Mycobacterium kansasii* in the absence of other pathogens was successfully isolated. Thus after mycobacteriological examination the final diagnosis of generalized extrapulmonary mycobacteriosis caused by *Mycobacterium kansasii* was settled as the main disease of this patient.

In 1980 the American Thoracic Society (ATS) adopted a set of diagnostic criteria for mycobacterial diseases [3]. In order to more accurately differentiate colonization from active tissue invasion by opportunist mycobacteria, namely *M. kansasii* and *M. avium-intracellulare*, AHN [4] has proposed new diagnostic criteria based on the presence or absence of cavitation and on the duration of positive sputum results after the start of therapy. Both AHN and ATS state the necessity for isolating the mycobacteria from the tissue and for showing histopathological changes compatible with the disease. Our reported case meets these demands.

#### References

1. Schraufnagel DE, Leech JA, Pollak B. - *Mycobacterium kansasii*: Colonization and disease. *Br J Dis Chest*, 1986, 80, 131-137.
2. Wolinski E. - When is an infection disease? *Rev Infect Dis*, 1981, 3, 1025-1027.
3. American Thoracic Society. - Diagnostic standards and classification of tuberculosis and other mycobacterial diseases (14th edition). *Am Rev Respir Dis*, 1981, 123, 343-358.
4. Ahn CH, McLarty JW, Ahn SS, Ahn SI, Hurst GA. - Diagnostic criteria for pulmonary disease caused by *Mycobacterium kansasii* and *Mycobacterium intracellulare*. *Am Rev Respir Dis*, 1982, 125, 388-391.

#### *Une mycobactériose extrapulmonaire fatale. S. Kos.*

RÉSUMÉ: Un homme de 60 ans, jusqu'ici en bonne santé, a été soigné pour symptômes grandissants de fièvre et d'exanthème suivis de leucopénie et de mycose du tractus gastro-intestinal; il est décédé six semaines après l'apparition des premiers symptômes. Un examen histologique a révélé une tuberculose disséminée des ganglions lymphatiques paratrachéaux, du foie, de la rate et de la moëlle épinière avec présence de bacilles résistants aux acides et décelés par examen de frottis. Des colonies multiples de la même souche de *Mycobacterium kansasii* ont été isolées par examen bactériologique du tissu des ganglions lymphatiques et de la rate. Les examens macroscopiques et histologiques n'ont montré aucune évidence de tuberculose pulmonaire. La maladie aiguë décrite et la mort rapide ont été diagnostiquées comme une mycobactériose extrapulmonaire généralisée, ce qui est rarement observé. *Eur Respir J.*, 1989, 2, 96-97.