

## CASE STUDY

# DNase treatment for atelectasis in infants with severe respiratory syncytial virus bronchiolitis

P.J.F.M. Merkus\*, M. de Hoog<sup>#</sup>, R. van Gent<sup>†</sup>, J.C. de Jongste\*

*DNase treatment for atelectasis in infants with severe respiratory syncytial virus bronchiolitis. P.J.F.M. Merkus, M. de Hoog, R. van Gent, J.C. de Jongste. ©ERS Journals Ltd 2001.*

**ABSTRACT:** Respiratory insufficiency due to respiratory syncytial virus (RSV) bronchiolitis is partly due to the abundance of thickened mucus and the inability to clear it from the airways. Mucus in RSV bronchiolitis contains necrotic inflammatory and epithelial cells. The viscoelastic properties of purulent airway secretions are largely due to the presence of highly polymerized deoxyribonucleic acid (DNA). Recombinant human deoxyribonuclease (rhDNase) is known to liquefy such mucus in patients with cystic fibrosis, whereas case reports described a beneficial effect in other respiratory disorders. The authors hypothesized that rhDNase would diminish atelectasis and mucus plugging in infants with severe RSV bronchiolitis.

Two infants with RSV bronchiolitis with massive unilateral atelectasis in whom mechanical ventilation was imminent due to exhaustion, and three mechanically ventilated infants (two neonates, one with bronchopulmonary dysplasia) with RSV bronchiolitis with pneumonia received treatment with 2.5 mg nebulized rhDNase twice daily.

Following administration of nebulized recombinant human deoxyribonuclease, clinical and radiological parameters improved quickly. Mechanical ventilation could be avoided in two infants while in three infants on artificial ventilation, clinical recovery started following the first dose of the drug. A therapeutic trial of recombinant human deoxyribonuclease may be an option in the treatment for atelectasis in severe or complicated respiratory syncytial virus bronchiolitis in infancy.  
*Eur Respir J 2001; 18: 734–737.*

\*Dept of Paediatrics, subdivision of Respiratory Medicine, and <sup>#</sup>Paediatric Intensive Care, Sophia Children's Hospital, Erasmus Medical Centre Rotterdam, and <sup>†</sup>Dept of Paediatrics, Sint Joseph Hospital, Veldhoven, the Netherlands.

Correspondence: P.J.F.M. Merkus, Sophia Children's Hospital/Erasmus Medical Centre Rotterdam, PO Box 2060, 3000 CB Rotterdam, the Netherlands.  
Fax: 31 104636801

Keywords: Atelectasis  
bronchiolitis  
infants  
recombinant human deoxyribonuclease  
respiratory failure  
respiratory syncytial virus

Received: March 28 2000  
Accepted after revision May 24 2001

Respiratory syncytial virus (RSV) bronchiolitis is one of the main causes of hospital admissions in neonates and infants and is responsible for substantial morbidity and mortality [1]. Treatment basically consists of supportive measures, as current therapeutic options in otherwise healthy infants are ineffective or controversial [2–4]. Complications include atelectasis, ventilation/perfusion mismatch, and respiratory insufficiency requiring mechanical ventilation (MV). In children with an increased risk of severe RSV bronchiolitis (neonates born prematurely and with chronic cardiopulmonary or neuromuscular diseases) MV may be difficult to avoid.

Respiratory failure due to RSV bronchiolitis is mainly due to the abundance and retention of thickened mucus. The viscoelastic properties of purulent airway secretions depend primarily on the presence of highly polymerized, polyanionic deoxyribonucleic acid (DNA), often as extracellular fibrils [5], mostly from degenerating leukocytes [6]. Recombinant human deoxyribonuclease (rhDNase) liquefies mucus *in vitro* within minutes, transforming it from a viscous gel to a flowing liquid [5–8]. Its efficacy has been well documented in cystic fibrosis [5–8], whereas case reports have described beneficial effects of rhDNase on the resolution of atelectasis in asthma, spinal cord

injury, and primary ciliary dyskinesia [9–15]. Because mucus in RSV bronchiolitis contains necrotic inflammatory and epithelial cells [2], rhDNase may also be expected to be effective in RSV bronchiolitis.

The authors report their experience with nebulized rhDNase in the treatment of atelectasis in five infants with severe or complicated RSV bronchiolitis.

## Case report

### Patient 1

A term female baby developed RSV bronchiolitis at 5 weeks of age. The patient was transferred to the paediatric intensive care unit because of a deteriorating clinical condition. At admission, the chest radiograph showed partial atelectasis of the right lung with the carbon dioxide tension in arterial blood ( $P_{a,CO_2}$ ) up to 12 kPa (90 mmHg). Additional oxygen ( $2\text{ L}\cdot\text{min}^{-1}$ ) was required through nasal prongs. Nebulized bronchodilator drugs and physiotherapy had no effect. The atelectasis of the right lung progressed 1 day later, with mediastinal herniation of the left lung and a shift of the trachea and mediastinum to the right side (fig. 1a). This suggested

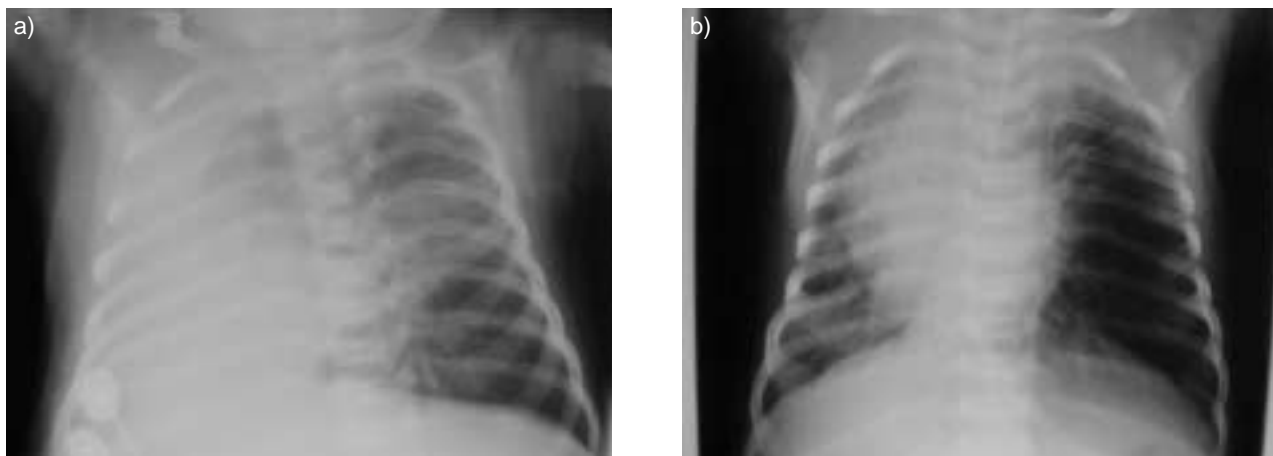


Fig. 1. – a) Complete atelectasis of the right lung, with rightward mediastinal shift and herniation of the left lung due to severe respiratory syncytial virus bronchiolitis before recombinant human deoxyribonuclease treatment in patient 1. b) Improved aeration of both lungs, less bronchitic markings and residual atelectasis of the right upper lobe, after 36 h (3 doses of recombinant human deoxyribonuclease) in patient 1.

blockage of the right main stem bronchus, probably due to mucus plugging. Because signs of fatigue were shown, artificial ventilation seemed imminent. Therapeutic bronchoscopy was considered, but this would have increased the risk of subsequent MV. Therefore, attempts were made to liquefy any viscous mucus and improve mucus clearance by administration of 2.5 mg rhDNase (Pulmozyme®, Roche, Basel, Switzerland), using a jet nebulizer.

Within 3 h of this treatment, ventilation improved, breathing sounds returned to the right lung, hypercapnia decreased to 6.9 kPa (52 mmHg) and the chest radiograph showed aeration of the right upper and lower lobes again, with less mediastinal shift or herniation of the left lung. Following continued treatment of rhDNase 2.5 mg twice daily for 2 days, the child recovered and the chest radiograph showed further improvement (fig. 1b). Artificial ventilation or bronchoscopy were not needed. No side-effects were observed. Because of a weak coughing reflex and feeding difficulties the patient was hospitalized for 2 weeks. At the age of 10 weeks a diagnosis of spinal muscular atrophy was made, partly explaining the dramatic course of RSV bronchiolitis.

#### Patient 2

A term female baby had no illnesses until 7 weeks of age, when the patient became progressively dyspnoeic due to RSV bronchiolitis. Additional oxygen was required and the patient was hospitalized. Nebulized bronchodilator drugs and physiotherapy did not improve the airways obstruction. The clinical condition deteriorated and 1 day later, a chest radiograph showed a complete atelectasis of the right lung, with volume loss and a mediastinal shift. Because MV was imminent, the patient was transferred to the neonatal intensive care unit and a therapeutic trial with 2.5 mg nebulized rhDNase was administered twice daily in an attempt to avoid artificial ventilation. Within 6 h of the first dose, the breathing frequency decreased from

95 to 39  $\text{min}^{-1}$  with less dyspnoea, and the cardiac frequency decreased from 182 to 164  $\text{beats}\cdot\text{min}^{-1}$ . Breathing sounds on the right lower lobe improved and the supply of oxygen could be tapered off. Twenty hours later, the chest radiograph showed marked improvement. MV was not needed and further clinical treatment was only indicated because of feeding difficulties due to RSV rhinitis. The patient was discharged on day 9. At 6 months of age the patient's condition is fine and no underlying illness has been found.

Because of these observations in two infants with severe RSV bronchiolitis in whom artificial ventilation was avoided, rhDNase was administered in three other infants who were on MV due to complicated RSV bronchiolitis (table 1). Patients 3 and 5 developed bronchiolitis neonatally, and patient 4 had chronic lung disease following prematurity. They all had complicating pneumoniae with positive cultures for *Streptococcus pneumoniae*. A therapeutic trial of rhDNase was given because ventilator settings were high and the clinical condition did not improve. No side-effects were observed. Within 24 h of the treatment, chest radiographs, cardiac frequency and  $P_a\text{CO}_2$  improved. Peak inspiratory pressures and the inspiratory oxygen fraction ( $F_{I\text{O}_2}$ ) did not change significantly (table 1).

#### Discussion

This report is the first to suggest that rhDNase is effective and safe in the mobilization of mucus in infant RSV bronchiolitis. The efficacy of rhDNase in cystic fibrosis has been proven [5–8], and case reports strongly suggest its efficacy on the resolution of atelectasis in various other respiratory disorders [9–15]. The present observation of resolution of atelectasis and clinical improvement immediately following nebulized rhDNase is consistent with these reports. The regular dose of nebulized rhDNase of 2.5 mg was administered in all patients. Assuming a

Table 1. – Relevant parameters in three ventilated infants with respiratory syncytial virus bronchiolitis before and 24 h after first dose of recombinant human deoxyribonuclease (rhDNase)

	Patient 3	Patient 4	Patient 5
Sex	M	M	M
Gestational age weeks	33	25	37
Postconceptional age weeks	37	54	39
Radiograph before DNase	Atelectasis RUL, RML, LUL	Atelectasis RUL, LUL	Atelectasis RUL
Radiograph after DNase	General improvement of aeration	Resolution of atelectasis of RUL	Improved aeration of RUL
Maximum peak inspiratory pressure cmH <sub>2</sub> O before/after DNase	23/21	30/25	25/24
<i>F</i> <sub>I,O<sub>2</sub></sub> % before/after DNase	60/35	80/70	40/37
Cardiac frequency beats·min <sup>-1</sup> before/after DNase	168/151	150/135	155/139
<i>P</i> <sub>a,CO<sub>2</sub></sub> kPa before/after DNase	8.5/6.9	8.1/6.2	7.9/7.5
Days on ventilator before DNase treatment	1	1	5
Complicating or predisposing factors	Prematurity, pneumonia	Chronic lung disease, prematurity, pneumonia	Pneumonia

RUL: right upper lobe; LUL: left upper lobe; RML: right middle lobe; *F*<sub>I,O<sub>2</sub></sub>: inspiratory oxygen fraction; *P*<sub>a,CO<sub>2</sub></sub>: carbon dioxide tension in arterial blood.

lung dose of 5–10% in the absence of airway obstruction, this dose is probably low compared to the studies by DURWARD *et al.* [15] and by BOEUF *et al.* [16] in which doses of instilled rhDNase were 0.5 mg·kg body weight<sup>-1</sup>, and 4 mg·m<sup>-2</sup>. None of the papers mentioned earlier reported any side-effects. The main arguments for trying rhDNase in the unventilated children were the reported presence of necrotic epithelial cells and leukocytes in RSV-induced airway secretions [2], and the progressive respiratory failure, while conventional treatment was ineffective and therapeutic bronchoscopy not attractive.

In the three ventilated patients clinical improvement was also seen following rhDNase treatment, although it was less pronounced than in the unventilated infants. This may be partly explained by the complicating pneumonia in the ventilated infants. Parenchymal consolidation due to infection is unlikely to improve using rhDNase, whereas airway collapse may improve rather quickly following liquefaction of thickened mucus. Marked improvement was seen in the chest radiograph, cardiac frequency and *P*<sub>a,CO<sub>2</sub></sub>. Peak inspiratory pressure did not change much, which may be attributed to a loss of compliance due to the course of the RSV bronchiolitis and the complicating pneumonia. *F*<sub>I,O<sub>2</sub></sub> did not decrease markedly, which is consistent with persisting ventilation/perfusion mismatch due to pneumonia. Duration of ventilation was longer (5 days compared to 1 day) and effect of rhDNase treatment was less clear in patient 5 compared to patients 3 and 4. Possibly, ventilation period and/or the timing of rhDNase administration are factors that codetermine the treatment result.

Obviously, controlled studies are needed to assess the efficacy and safety of the drug for treatment of atelectasis and mucus plugging in severe respiratory syncytial virus bronchiolitis. Respiratory syncytial virus epidemics still constitute a significant burden on patients, families and paediatric healthcare resources. This case report highlights a possible novel

therapeutic option in the treatment of one of the most notorious respiratory infections of infancy. Until randomized trials have been performed, the authors suggest considering a therapeutic trial of recombinant human deoxyribonuclease in those infants who develop massive atelectasis due to severe or complicated respiratory syncytial virus bronchiolitis.

#### References

1. Wohl MEB. Bronchiolitis. In: Chernick V, Boat TF, eds. *Kendig's Disorders of the Respiratory Tract in Children*. 6th edition. Philadelphia, Saunders, 1998; pp. 473–485.
2. Black-Payne C. Bronchiolitis. In: Hilman BC, ed. *Pediatric Respiratory Disease: diagnosis and treatment*. 1st edition. Philadelphia, Saunders, 1993; pp. 205–218.
3. De Boeck K, Van de Aa N, Van Lierde S, Corbeel L, Eeckels R. Respiratory syncytial virus bronchiolitis: a double-blind dexamethasone efficacy study. *J Pediatr* 1997; 131: 919–921.
4. Moler FW, Steinhart CM, Ohmit SE, Stidham GL. Effectiveness of ribavirin in otherwise well infants with respiratory virus-associated respiratory failure. *J Pediatr* 1996; 128: 422–428.
5. Armstrong JAB, White JC. Liquefaction of viscous purulent exudate by deoxyribonuclease. *Lancet* 1950; ii: 739–742.
6. Potter JL, Spector S, Matthew LW, Lemm J. Studies on pulmonary secretions: III. The nucleic acids in whole pulmonary secretions from patients with cystic fibrosis, bronchiectasis, and laryngectomy. *Am Rev Respir Dis* 1969; 9: 909–916.
7. Shak S, Capon DJ, Helmiss R, Marsters SA, Baker CL. Recombinant human DNase reduces the viscosity of cystic fibrosis sputum. *Proc Natl Acad Sci* 1990; 87: 9188–9192.
8. Hubbard RC, McElvany NG, Birrer P, *et al.* A preliminary study of aerosolized human

- Deoxyribonuclease I in the treatment of cystic fibrosis. *N Engl J Med* 1992; 326: 812-815.
9. Gershan WM, Rusakow LS, Chetty A. Resolution of chronic atelectasis in a child with asthma after aerosolized recombinant human DNase. *Pediatr Pulmonol* 1994; 18: 268-269.
  10. Grealley P. Human recombinant DNase for mucus plugging in status asthmaticus. *Lancet* 1995; 346: 1423-1424.
  11. Touleimat BA, Conoscenti CS, Fine JM. Recombinant human DNase in management of lobar atelectasis due to retained secretions. *Thorax* 1995; 50: 1319-1321.
  12. Voelker KG, Chetty KG, Mahutte CK. Resolution of recurrent atelectasis in spinal cord injury patients with administration of recombinant human DNase. *Intensive Care Med* 1996; 22: 582-584.
  13. Desai M, Weller PH, Spencer DA. Clinical benefit from nebulized human recombinant DNase in Kartagener's syndrome. *Pediatr Pulmonol* 1995; 20: 307-308.
  14. Ten Berge M, Brinkhorst G, Kroon A, De Jongste JC. DNase treatment in primary ciliary dyskinesia - assessment by nocturnal pulse oximetry. *Pediatr Pulmonol* 1999; 27: 59-61.
  15. Durward A, Forte V, Shemie SD. Resolution of mucus plugging and atelectasis after intratracheal RhDNase therapy in a mechanically ventilated child with refractory status asthmaticus. *Crit Care Med* 2000; 28: 560-562.
  16. Boeuf B, Prouix F, Morneau S, Marton D, Lacroix J. Safety of endotracheal RhDNase for treatment of pulmonary atelectasis in mechanically ventilated children. *Pediatr Pulmonol* 1998; 26: 147.