

CASE STUDY

Primary lymphoepithelioma-like carcinoma within an intralobular pulmonary sequestration

N. Hekelaar*[‡], R. van Uffelen*, A.C.M. van Vliet⁺, O.C.M. Varin[#], P.J. Westenend**

Primary lymphoepithelioma-like carcinoma within an intralobular pulmonary sequestration. N. Hekelaar, R. van Uffelen, A.C.M. van Vliet, O.C.M. Varin, P.J. Westenend. ©ERS Journals Ltd 2000.

ABSTRACT: A 31-yr-old Chinese female, a nonsmoker, presented with digital clubbing and coughing. Diagnostic evaluation revealed a pulmonary sequestration in the left lower lobe. During surgery a tumour was discovered, which turned out to be a lymphoepithelioma-like carcinoma. These tumours are mainly found in Asians, and are associated with the Epstein Barr virus and not with smoking. They are thought to have a better prognosis and to be more chemosensitive. The need for surgical treatment of pulmonary sequestration and the recognition of lymphoepithelioma-like carcinoma as a distinct clinicopathological entity is emphasized.

Eur Respir J 2000; 16: 1025–1027.

*Dept of Pulmonology, ⁺Dept of Internal Medicine, and [#]Dept of Surgery, Albert Schweitzer Ziekenhuis, Dordrecht, the Netherlands. **Laboratory of Pathology, Dordrecht, the Netherlands, [‡]Dept of Pulmonology, Ziekenhuis Leyenburg, Den Haag, the Netherlands.

Correspondence: N. Hekelaar, Dept of Pulmonology, Ziekenhuis Leyenburg, P.O. Box 40551, 2504 LN Den Haag, the Netherlands. Fax: 31 703592150

Keywords: Intralobular sequestration
lymphoepithelioma-like carcinoma
pulmonary sequestration

Received: May 22 2000
Accepted after revision June 8 2000

Pulmonary sequestration is a rare anomaly in which nonfunctioning lung tissue is separated from the normal tracheobronchial tree and is supplied by an aberrant systemic artery.

Nonspecific infections and tuberculosis in sequestered lobes have been frequently described; however, malignancy has been rarely reported [1–3]. To the best of the authors knowledge this is the first report describing a lymphoepithelioma-like carcinoma in an intralobular pulmonary sequestration.

Case report

In August 1993 a 31-yr-old, Chinese female born in Hong Kong was referred to the Department of Pulmonology for evaluation of digital clubbing. For four months she had been complaining of pain in the joints of her fingers and ankles, and coughing with expectoration of white sputum. She had no pulmonary history and was a nonsmoker. On physical examination there was clubbing of the fingers and toes, there were no signs of dyspnoea or cyanosis.

Except for an elevated erythrocyte sedimentation rate (ESR) (36 mm in the first hour), all laboratory values were within normal limits. Pulmonary function tests were also normal. A chest radiograph revealed a rounded shadow behind the heart. Computed tomography (CT) scanning of the chest revealed some calcifications of the mediastinal lymph nodes and infiltration of the left anterobasal segment. Sputum examination was negative for pathogens including *Mycobacterium tuberculosis*. Bronchoscopic

examination was normal, and brushing showed some atypical cells, probably benign.

On a presumptive diagnosis of pulmonary sequestration aortography was performed, which demonstrated one aberrant artery originating from the abdominal aorta and feeding the sequestration compatible with the intralobular type.

The patient was referred for thoracotomy. Surgery revealed an intralobular sequestration (ILS) in the basal segments of the left lower lobe. Furthermore, there was a mass palpable within the ILS extending to the left hilus. The basal segments of the left lower lobe were removed together with lymph nodes surrounding the inferior pulmonary vein. Pathological examination of the lymph nodes during operation showed no signs of malignancy. The apex of the left lower lobe was spared.

Pathological examination of the resected lung tissue showed a tumour of 4 cm in size which was close to the pleural surface and within 0.5 cm of the bronchial resection margin. On microscopic examination (figs. 1 and 2) an undifferentiated large cell carcinoma was found, growing in sheets with abundant lymphocytic infiltration consistent with a diagnosis of lymphoepithelioma-like carcinoma (LELC). *In situ* hybridization study of the tumour (Epstein Barr Virus encoded-RNA (EBER); DAKO, Copenhagen, Denmark) was positive for the Epstein Barr virus (EBV) confirming the diagnosis of LELC (fig. 3). In addition several subpleural large arteries were found consistent with the diagnosis of pulmonary sequestration. Because of the tumour presence a relation between the sequestration and the bronchial tree could not be assessed. The pleural surface and bronchial resection margin were not involved, and a lymph node was negative for

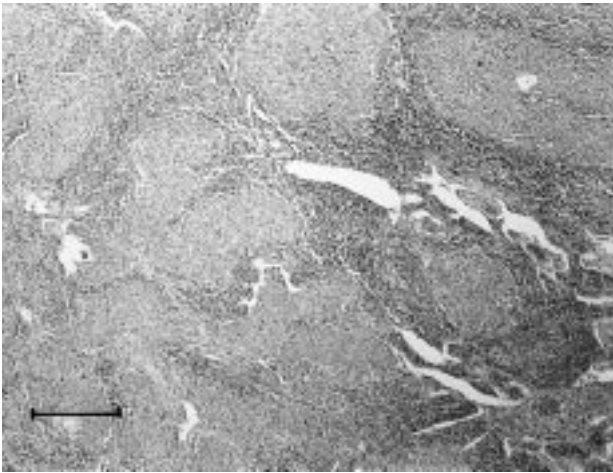


Fig. 1. – Overview of the tumour demonstrating nests of large cells in a lymphoid-rich stroma (haematoxylin & eosin staining, bar 400 µm).

metastasis. The tumour was staged as a stage I (pT₂N₀M₀) so the patient did not receive additional radiotherapy.

During follow-up the patient complained of coughing with expectoration of white sputum. Bronchoscopy and CT scanning of the chest were normal in September 1994. In August 1995 CT scanning showed an enlargement of the left hilus. At that time repeated bronchoscopic examination revealed a tumour near the stump of the left lower lobe bronchus. Pathological examination of a biopsy specimen again showed a LELC. In September 1995 an extra-pleural and intra-pericardial residual pneumectomy was performed and the same tumour as previously diagnosed was found in the left hilus without extension to the pericardium or fissura. There were no lymph node metastasis. Four years after the pneumectomy the patient is doing well.

Discussion

Two types of pulmonary sequestration exist; extra-lobular sequestration (ELS), which has its own pleural covering, and ILS, which shares a common pleura with the normal lung tissue. ILS is the most common form of

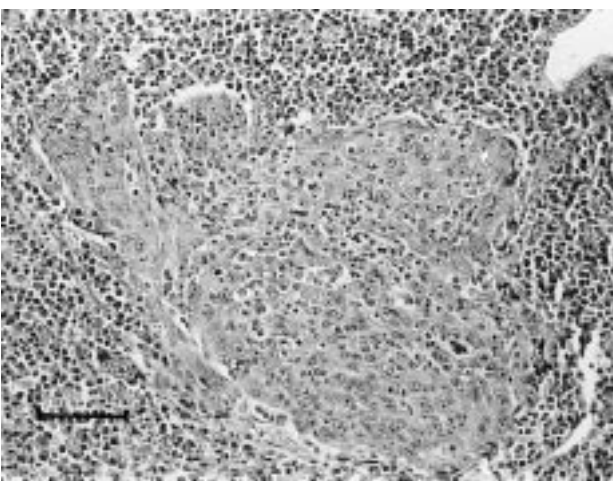


Fig. 2. – Detail with one tumour nest surrounded by lymphoid-rich stroma (haematoxylin & eosin staining, bar 100 µm).

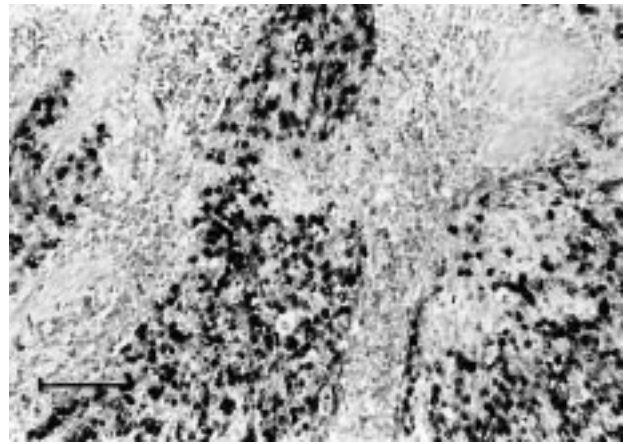


Fig. 3. – Positive nuclear *in situ* hybridisation for Epstein Barr virus in the tumour cells (black dots) and no staining in the surrounding lymphoid cells (EBER *in situ* hybridisation, bar 100 µm).

pulmonary sequestration and is most often localized in the lower lobes as in the present patient.

There are a few theories concerning the pathogenesis of pulmonary sequestration. At first both types of sequestration were considered to be a congenital malformation developing from an accessory lung bud arising from the primitive foregut. However, ILS has never been reported in newborn infants and therefore, some authors believe that this anomaly is acquired [4]. Whether infections and possibly malignancy are the primary impulse for the formation of an ILS or if these are complications of an ILS is still a question to be solved.

Although tuberculosis and Nocardial infections have been described in both ELS and ILS, the presence of malignancy in a sequestration is less well known. In the literature only one case of squamous cell carcinoma (SCC) in ILS and two cases of SCC in ELS could be detected [1–3]. Another rare finding of fibrous mesothelioma in ILS was recently reported [5]. There have been no earlier publications of LELC in ILS or ELS.

Primary LELC of the lung is a very rare tumour which was first described in 1987 and is considered to be a subset of undifferentiated large cell carcinoma with prominent lymphoid infiltration [6]. The tumour has only recently been included in the World Health Organization (WHO) classification of lung and pleural tumours [7]. Primary LELC of the lung has a higher incidence in Asians and is strongly associated with EBV in this population, as was the case in this patient. The appearance of LELC of the lung is not as frequently associated with smoking as in other types of lung malignancy [8]. The present patient in this case study was also a non-smoker without known previous contacts with industrial agents.

There is little information about the treatment of these tumours. When possible, the first choice seems to be surgery for the lower stages as in other non-small cell lung carcinoma (NSCLC). A better prognosis compared to other NSCLC has been suggested [9]. Little is known regarding treatment with radiotherapy and/or chemotherapy for inoperable higher stages; however, it has been stated that LELC is highly chemosensitive [10]. The discovery of a LELC in the patient in this study was an

unexpected, rare finding and was not recognized as such at the time of diagnosis. Instead a diagnosis of squamous cell carcinoma was made.

This case, as well as previously reported cases of malignancy in either intralobular sequestration or extralobular sequestration, therefore, illustrate the necessity to operate on every patient with a pulmonary sequestration as soon as it is diagnosed [1–3, 5]. The goals are not only to diminish complications like recurrent infection and haemoptysis, but also to find out what is inside the sequestration. Since lymphoepithelioma-like carcinoma has a strong Epstein Barr virus associated pathogenesis and possibly a better prognosis and is more chemosensitive, it is important to recognize this tumour as a distinct clinicopathological entity.

References

1. Savic B, Birtel FJ, Tholen W, Funke HD, Knoche R. Lung sequestration: report of seven cases and review of 540 published cases. *Thorax* 1979; 34: 96–101.
2. Bell-Thomson J, Missier P, Sommers SC. Lung carcinoma arising in bronchopulmonary sequestration. *Cancer* 1979; 44: 334–339.
3. Hertzog P, Rouleau J, Marcou J. Cancer épidermoïde développé sur une séquestration. *J Franc Med Chir Thor* 1963; 17: 33–38.
4. Stocker JT, Malczak HT. A study of pulmonary ligament arteries: relationship to intralobular sequestration. *Chest* 1984; 86: 611–615.
5. Paksoy N, Demircan A, Altiner M, Artvinli M. Localised fibrous mesothelioma arising in an intralobular pulmonary sequestration. *Thorax* 1992; 47: 837–838.
6. Begin LR, Eskandari J, Joncas J, Panasci L. Epstein-Barr virus related lymphoepithelioma-like carcinoma of the lung. *J Surg Oncol* 1987; 36: 280–283.
7. Travis WD, Colby TV, Corrin B, Shimosato Y, Brambilla E, Sobin LH. Histological Typing of Lung and Pleural Tumours. Third edition. Germany, Springer Verlag, 1999; pp. 41–42.
8. Chan JKC, Hui PK, Tsang WYW, *et al.* Primary lymphoepithelioma-like carcinoma of the lung. A clinicopathologic study of 11 cases. *Cancer* 1995; 76: 413–422.
9. Chen F-F, Yan J-J, Lai W-W, Jin Y-T, Su I-J. Epstein-Barr virus-associated non-small cell lung carcinoma. Undifferentiated "lymphoepithelioma-like" carcinoma as a distinct entity with better prognosis. *Cancer* 1998; 82: 2334–2342.
10. Chan ATC, Teo PML, Lam KC, Chan WY, Chow JHS, Yim APC. Multimodality treatment of primary lymphoepithelioma-like carcinoma of the lung. *Cancer* 1998; 83: 925–929.