

Pre-emptive therapy with azoles in lung transplant patients

J. Hamacher*, A. Spiliopoulos[†], A-M. Kurt[‡], L.P. Nicod*,
and the Geneva Lung Transplantation Group^{*+‡#}

Pre-emptive therapy with azoles in lung transplant patients. J. Hamacher, A. Spiliopoulos, A-M. Kurt, L.P. Nicod, and the Geneva Lung Transplantation Group. ©ERS Journals Ltd 1999.

ABSTRACT: Pulmonary fungal infection is diagnosed in up to 15–25% of lung transplant recipients and frequently bears a fatal outcome. This prospective uncontrolled study addresses the efficacy and safety of pre-emptive azole therapy against fungal infection in these patients.

Fluconazole or itraconazole have been systematically used according to reported fungus sensitivity after the discovery of fungi in lower respiratory tract samples. Patients were treated until the bronchial suture was normal and the cultures of the following bronchoscopy remained negative.

Fungi were found post-transplantation in the lower respiratory tract specimens of 26 out of 31 (84%) patients, predominantly *Candida albicans* (20 patients) and *Aspergillus fumigatus* (16 patients). Mycelia characteristic of *Candida* spp. or *Aspergillus* spp. were found in necrotic tissue at the bronchial suture of nine patients. The mean duration of the 38 treatments was 3.6±2.6 months (range, 0.5–12 months). After a median follow-up of 16 (range, 0–48) months, two cases of extended ulcerative and pseudo membranous *Aspergillus fumigatus* bronchitis were observed and healed under itraconazole treatment.

In conclusion, pre-emptive azole therapy may be effective and well-tolerated in lung transplant patients where fungi are found in the airways or pleura.

Eur Respir J 1999; 13: 180–186.

*Pulmonary Division, [†]Thoracic Surgery Unit, [‡]Dept of Pathology, and [#]Dept of Anaesthesia/Surgical Intensive Care Unit, Paediatric Dept, University Hospital, Geneva, Switzerland.

Correspondence: L.P. Nicod, Pulmonary Division, Hôpital Cantonal Universitaire, CH-1211 Geneva 14, Switzerland. Fax: 41 223729929

Keywords: Fluconazole
fungal infection
itraconazole
lung transplantation
prophylaxis

Received: December 4 1997

Accepted after revision September 3 1998

This work was supported by the Swiss National Research Found, Nos. 32-32367.91 and 32-40844.94 (and by the "Association Vaud-Genève", project No. 19).

Infective complications are significantly more frequent in lung transplant (LTX) patients than when other solid organs are transplanted [1]. A relatively high level of immunosuppression, especially with respect to rejection episodes, and the constant exposure to the external environment among other factors may contribute to the increased susceptibility [2]. Other portals of entry of infectious agents might be the gastrointestinal tract or foreign materials such as intravascular catheters. The donor organs also can be reservoirs for pathogenic fungi [3, 4]. The degree and composition of the immunosuppressive regimen seem to determine the susceptibility for fungal infections, as one study comparing the impact of tacrolimus to cyclosporin treatment showed more fungal infections under tacrolimus treatment [5].

Invasive fungal infections may already occur in the first few postoperative days [6], but also occur years after transplantation, and sometimes in the native lung [7, 8]. Parallel to immunosuppressive intensity, the prevalence is highest in the first 2 months and drops 6 months after transplantation [6, 9, 10]. In some series with heart–lung and lung transplant recipients, the incidence of candida infection is higher than that of aspergillus infection [1, 11, 12], while in others aspergillus infections predominate [10, 13].

Treatments of opportunistic fungal infections rely on the restoration of immunity, e.g. by reduction of immunosuppression, especially in nonvital organ transplant patients, and also on the administration of antifungal agents. Fungal prophylaxis with intravenous amphotericin B [11,

14], or intrahospital postoperative aerosolized amphotericin B has been used and suggested to be efficient in a group of heart, heart–lung, and lung transplant patients [15]. For fungal prophylaxis in bone marrow [16, 17] as well as solid organ transplantation, azole agents have been used [18, 19] including itraconazole in lung transplantation [20, 21]. However, although azoles appear efficient and usually well tolerated [22–24], to our knowledge no randomized studies have been reported so far for solid organ transplant patients. Azoles inhibit fungal ergosterol synthesis, thereby impeding normal fungal cell wall function. Their antimicrobial spectrum, tolerance, specific pharmacokinetic properties, and drug interactions have recently been well described [22].

The aim of this prospective, but uncontrolled study was to test the efficiency and tolerance of aggressive prolonged azole prophylaxis in lung transplant patients colonized by fungi or with a limited infection or invasion, e.g. of the bronchial sutures.

Materials and methods

In this study we evaluated all patients who underwent lung transplantation in Geneva, Switzerland, between April 1993 and June 1997. Azole treatment was initiated each time a patient was colonized or infected with fungi. Treatments were pursued until bronchial sutures were

healed and fungal cultures were negative. Medical histories, with special respect to medication, duration and adverse reaction to azole agents, laboratory and microbiological results, and biopsy results were evaluated.

All patients received postoperatively six times per day an oral suspension with 40 mg polymyxin and 250 mg neomycin until extubation, as well as four times per day 100,000 U of nystatin suspension as oropharyngeal decontaminant until they left the intensive care unit. Intravenous gancyclovir prophylaxis (5 mg·kg⁻¹ perfusion *i.v.* per day via a Port-a-Cath® (SIMS Deltec Inc., St Paul, MN, USA)) was performed for 5–6 months post-transplantation in cases of a cytomegalovirus-positive donor or recipient. *Pneumocystis carinii* prophylaxis was performed with cotrimoxazole, except in two cases where monthly pentamidine inhalations were performed.

Control bronchoscopies generally were performed on days 0, 2, 7, 14, and 28, then after month 3, 6, 9 and 12, and finally every 6 months thereafter. Microbiological samples included bronchoalveolar lavages (BALs), bronchial aspirates, and, if present, sputum. Histological samples consisted either of transbronchial biopsies, performed only after the third postoperative week, or of biopsies, indicated due to bronchial suture abnormalities or bronchial lesions. All histological samples were stained with Grocott's silver stains to search for fungi.

Microscopical analysis with BAL fluid was performed with cytocentrifuge slides using 200 µL of lavage fluid and stained with the Fungi-Fluor® kit (Polysciences Inc., Warrington, PA, USA) [25]. Pellet smears from bronchial aspirates and sputa were stained with calcofluor white stain [26]. One hundred microlitres of pellet from BAL fluids, bronchial aspirates, or sputa were incubated on brain heart infusion agar with and without the addition of antibiotics (gentamicin and chloramphenicol) for 2 weeks at 30°C without CO₂ at a humidity of 40%. Identification of individual organisms was based on characteristics of growth and morphology, as well as biochemical profiles.

The treatment schedule for the two azole agents was as follows. Fluconazole 200 mg·kg⁻¹ (except in one patient who erroneously was given 400 mg·day⁻¹) was prescribed twice daily orally in case of evidence of *Candida* spp. or other presumed sensitive fungi. Itraconazole 400 (200–800; median: 400) mg·day⁻¹ was given twice daily orally in case of *Aspergillus* spp. (or other sensitive fungi not sensitive to fluconazole). From the middle of the study onwards (February 1995), serum trough levels of itraconazole were determined by high-pressure liquid chromatography (HPLC) for dose adaptation in 31 instances for 8 patients. Levels of 250 ng·mL⁻¹ (0.25 mg·mL⁻¹) were considered as minimal. Treatment was continued until the next bronchial aspirate or BAL revealed negative cultures, and bronchial sutures or lesions were healed.

Patients presenting with fungal cultures that showed primary resistance to both azole drugs as suggested by the literature (two patients with *Aspergillus niger* (one patient over 1 month in bronchial aspirate, BAL, and sputum; another patient during 15 months, respectively) and one patient with *Mucor* spp. (immediately postlung transplantation in two consecutive bronchial aspirates) were not treated with azoles, or with other antifungal agents, and were closely followed. Systematic fungus sensitivity testing was not performed.

Data were analysed using the SYSTAT for Windows® software package (SPSS Inc., Chicago, IL, USA), using descriptive statistics and the Chi-squared test for equality of proportions. A p-value ≤ 0.05 was considered as significant. All descriptive statistics were expressed as means with standard deviation (SD) unless otherwise indicated.

Results

Patient characteristics

The diagnoses of the 31 patients having undergone lung transplantation are listed in table 1. The mean age was 42.5±15 yrs, median age 48 yrs (range 10–60 yrs). The mean follow-up was 19.4±15.6 months (median 16, range 0–48 months) and corresponded to 600.1 patient-months. The causes of death of eight patients are shown in table 2. No deaths were related to fungal disease.

Specimen characteristics and numbers

Candida albicans was the most frequent isolate and was found in 20 out of 31 patients. The second most frequent fungus was *A. fumigatus*, isolated in 16 patients.

Preoperative sputum examinations revealed *A. fumigatus* in three patients, two of whom had immediately postoperatively positive respiratory tract specimens and one of whom developed invasive aspergillus bronchitis (case 2), and *C. albicans* in seven patients, one of whom had immediately postoperative repeated respiratory tract and pleural fluid specimens positive for *C. albicans*. Aspergillus serology was positive in 2 (with cystic fibrosis) out of 18 patients tested before transplantation.

Results of fungal examinations post-transplantation are listed in tables 3 and 4. Table 3 and figure 1 show that *C. albicans* was the most common lower respiratory tract organism, followed by *A. fumigatus*. Within the first 100 days after lung transplantation, *C. albicans* was the most frequently found fungus in BAL (p=0.006, Chi-squared test) as well as in bronchial aspirates (p=0.046). No such difference was found in the distribution of positive samples thereafter.

Table 1. – Diagnosis leading to single or double lung transplantation

Diagnosis	Patients n	Single lung transplant	Double lung transplant
COPD	11	9	2
α ₁ -antiprotease deficiency	2	2	-
Cystic fibrosis	6	-	6
Interstitial fibrosis	4	4	-
Primary pulmonary arterial hypertension	4	-	4
Paraquat intoxication	1	1	-
Pulmonary veno-occlusive disease	1	-	1
Lymphangioliomyo- matosis	1	-	1
Bronchiolitis obliterans	1	-	1
Total	31	16	15

COPD: chronic obstructive pulmonary disease.

Table 2. – Causes of death of eight patients after lung transplantation

Patient No.	Sex	Age yrs	Diagnosis	Cause of death	Day post-lung transplantation
1	Female	10	Cystic fibrosis	Acute graft dysfunction	0
2	Female	57	Primary pulmonary arterial hypertension	Acute graft dysfunction	1
3	Female	29	Pulmonary veno-occlusive disease	Haemorrhage	7
4	Male	51	Emphysema	Viral pneumonia	110
5	Female	12	Cystic fibrosis	Klebsiella sepsis	280
6	Male	47	α_1 -antiprotease deficiency	Pseudomonas sepsis	330
7	Male	53	Emphysema	Chronic rejection, Kaposi's sarcoma	342
8	Male	59	Emphysema	Chronic rejection	1007

Torulopsis glabrata was found in three patients: after 11 months and 6 months of treatment with itraconazole, and after 8 months of treatment with fluconazole. In one patient, itraconazole was continued and in another fluconazole prescribed; one patient did not receive any treatment. The fungus was no longer present in the follow-up samples performed 3 months later.

Figure 2 shows the percentage of fungal culture positive BAL and bronchial aspirate in the months following lung transplantation. For BAL, cultures were ~2.5 times more frequently positive than matched microscopic examination. Cultures from bronchial aspirates and from sputum were ~5 times more frequently positive than 'matched microscopic results.

Only on one occasion during follow-up without azole treatment was microscopic examination not associated with a positive culture. Negative cultures despite matched positive microscopic results occurred during azole treatment in six BALs and one bronchial aspirate.

Table 3 shows the various fungi cultured in the sputa, BALs and aspirates. The yield from each procedure is given in table 4. Sputum cultures were positive in 14 of the 28 patients having had positive samples otherwise. The fungal species found corresponded to those found in BAL and bronchial aspirates.

Table 4 shows the number of various specimens and the yield of positive results by microscopic examination or cultures. Approximately 10% of lower respiratory tract

Table 3. – Source and types of fungi in the lower respiratory tract specimens post-transplantation

Fungus	Patients*	BAL	BA	S
<i>Candida albicans</i>	20	15	19	14
<i>C. norvegensis</i>	2	1	2	0
<i>C. lusitanae</i>	1	0	0	1
<i>Torulopsis glabrata</i> (<i>C. glabrata</i>)	3	1	3	1
<i>Aspergillus fumigatus</i>	16	13	14	5
<i>A. niger</i>	2	1	2	2
<i>A. terreus</i>	2	1	1	1
<i>A. nidulans</i>	1	1	2	1
<i>Penicillium</i> spp.	4	4	1	1
<i>Trichosporan</i> spp.	1	0	1	1
<i>Geotrichon</i> spp.	1	0	1	1
<i>Mucor</i> spp.	1	0	1	0
Total	54**	37	47	28

Data are presented as numbers. BAL: bronchoalveolar lavage; BA: bronchial aspirate; S: sputum. *: patients with positive fungal results out of 31 transplant patients; **: 54 different fungal isolates in 26 patients.

specimens were microscopically positive for fungi. In contrast, none of the transbronchial biopsies showed microscopic evidence of fungi, whereas nearly 40% of bronchial biopsies showed evidence of fungi. In nine patients there was microscopic evidence of fungal growth in the bronchial wall, which was found from day 20 to day 170 (day 52±30). In this group, histologically probable candida was found in three patients and probable aspergillus found in four patients, whereas, in two patients, fungi could not be classified on histological examination, but *C. albicans* or *A. fumigatus* grew from the bronchial aspirates. However, as the fungi were exclusively seen in various quantities in necrotic tissue, the biopsies did not prove invasive disease.

Cultures were positive for fungi in roughly a quarter (26%) of all BALs, whereas the bronchial aspirates performed systematically during the same bronchoscopies were positive on 138 occasions, which represent 42% of these procedures. This demonstrates an increased rate of positive aspirates compared with positive BALs ($p < 0.0001$; Chi-squared test). As the number of true positive or negative results cannot be determined, specificity and sensitivity are unknown. However, none of the patients with negative results for fungi were ultimately found to have fungal disease which would have necessitated a specific treatment.

Treatment characteristics

Fluconazole was prescribed in 17 patients. The mean duration of treatment was 3.0 ± 2.1 months; the mean oral fluconazole dose was 2×102 (SD 25) $\text{mg} \cdot \text{day}^{-1}$ (median 2×100 $\text{mg} \cdot \text{day}^{-1}$). Itraconazole was prescribed in 21 patients with a mean duration of 4.2 ± 2.9 months and a mean oral itraconazole dose of 2×172 (SD 67) $\text{mg} \cdot \text{day}^{-1}$ (median, 2×200 $\text{mg} \cdot \text{day}^{-1}$). Taken together, 38 treatments were performed in 26 of 31 (84%) patients with a mean treatment

Table 4. – Type, number, and yield of specimens investigated for fungi post-transplantation

Specimen type	Total number	Positive microscopy	Positive culture
Bronchoalveolar lavage	324	38 (12)	85 (26)
Bronchial aspirate during bronchoscopy	330	26 (8)	138 (42)
Expectoration	161	19 (12)	72 (45)
Transbronchial biopsy*	114	0 (0)	Not done
Bronchial biopsy*	31	12 (39)	Not done

Data are presented as numbers with percentages (positive compared with total number) in parentheses. *: number of bronchoscopies with biopsies.

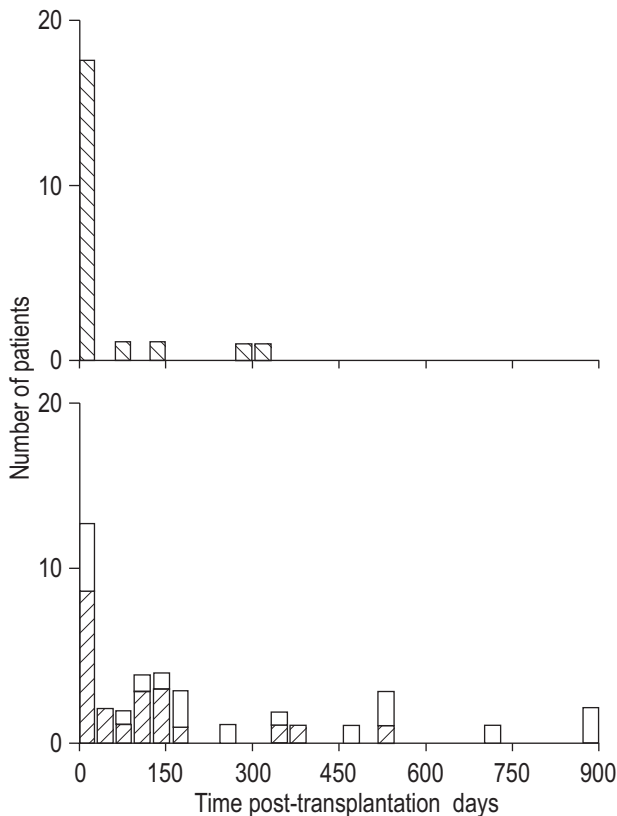


Fig. 1. – Number of patients with positive fungal specimen at any given time following lung transplantation. Isolates were obtained from bronchoalveolar lavage (n=324), bronchoscopic aspirates (n=330), or expectorations (n=161). Within the first 100 days after lung transplantation, *Candida albicans* (▨) were found more frequently in bronchoalveolar lavage (p=0.006; Chi-squared test), as well as in bronchial aspirates (p=0.046) compared with the remaining study period. No significant differences were found in the distribution of positive samples afterwards. ▨: *Aspergillus fumigatus*; □: other fungi.

duration of 3.6 ± 2.6 months (range, 0.5–12 months). Compared with the total survival of 600.1 patient-months postlung transplantation, the total treatment duration of 138.25 months corresponded to 23.1% of the time under azole treatment in the period studied following lung transplantation.

Serum levels of itraconazole and 25-OH itraconazole have been determined in 31 instances using HPLC since February 1995. In 8 of the 21 patients treated with itraconazole (in three of the probable five patients with histological evidence of aspergillus infection), its levels were determined. Itraconazole serum levels of at least 250 ng·mL⁻¹ are usually considered as therapeutic [27]. The mean itraconazole level determined in our patients was 880 (SD 900) ng·mL⁻¹ (median, 418 ng·mL⁻¹; range, 19–2,543 ng·mL⁻¹). The matched mean 25-OH itraconazole level was 716 (SD 810) ng·mL⁻¹ (median, 508 ng·mL⁻¹; range, 57–3,702 ng·mL⁻¹).

The fungal species found in expectorates corresponded to those found in BAL and bronchial aspirates. Therefore, no decision to perform a treatment was based solely on the finding of fungi in expectorations. On two occasions, positive fungal cultures in the follow-up led to the brief prolongation of treatment.

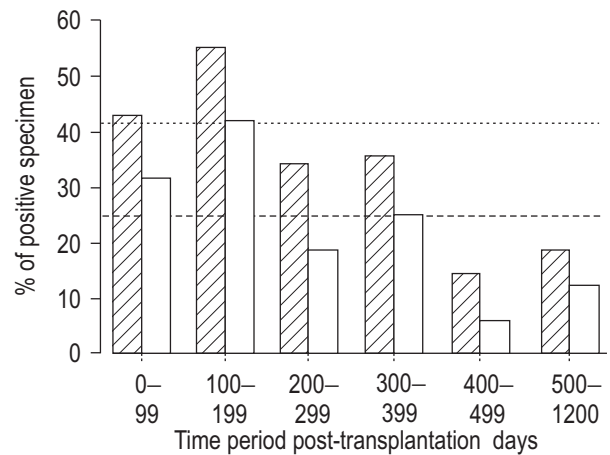


Fig. 2. – Percentage of positive culture results of bronchial aspirate (▨) and of bronchoalveolar lavage (BAL; □) after lung transplantation. A diminution is seen in the incidence of positive results after ~1 yr of follow-up. A mean of 42% (---) of bronchial aspirates were positive during the study period; meanwhile 26% (---) of BAL specimens were positive.

Adverse events. One patient on treatment with itraconazole developed seizures probably due to increased levels of cyclosporin (trough level, 530 ng·mL⁻¹; therapeutic levels within the first months 250–300 ng·mL⁻¹) and under concomitant intravenous gancyclovir prophylaxis. The drug interaction with itraconazole occurred while cyclosporin levels had not yet been well adjusted. One patient suffered from a temporary erectile dysfunction while on treatment with itraconazole, which was considered as possibly related. Otherwise, no other side-effects due to interactions (e.g. renal insufficiency under cyclosporin treatment, midazolam overdose, ventricular arrhythmia with concomitant antihistamines such as terfenadin or astemizole, or gastrointestinal drugs such as cisapride [28]) were observed. No digestive, cutaneous or central nervous signs or symptoms, hypokalaemia, aminotransferase elevation, arterial hypertension, or oedema attributable to azole treatment were noted.

Patient outcomes

None of the patients developed fungal pneumonia or dissemination. One patient with *C. albicans* in respiratory tract specimens had a sutural peribronchial abscess 30 days after the second LTX: no fungi could be shown at autopsy when the patient died from *Pseudomonas aeruginosa* sepsis. Of the nine patients showing microscopic evidence of fungi in bronchial biopsies, two patients had clinical evidence of an extended invasive bronchial aspergillosis.

In one of these, a 48-yr-old patient with bilateral sequential lung transplantation for primary pulmonary arterial hypertension developed an invasive pseudomembranous right-sided bronchial aspergillosis due to *A. fumigatus* ~28 days post-transplantation. This occurred on the medial proximal part of the donor bronchi, where a limited area of ~2.5×3 cm of necrosis had been observed a few days after transplantation. Itraconazole 2×200 mg·day⁻¹ was started on the 15th day after transplantation, based on the positive *A. fumigatus* culture of the bronchial aspirate. Once the diagnosis of locally invasive aspergillosis was made on

day 27, the doses of prednisone were decreased from 0.4 to 0.2 mg·kg⁻¹, and the itraconazole dosage raised to 2×400 mg·day⁻¹ allowing it to reach serum levels above 1,000 µg·mL⁻¹ during the following 15 weeks, until all bronchial lesions had virtually disappeared; the dosage was then reduced to 2×200 mg·day⁻¹, maintaining a therapeutic level (though serum level 364 ng·mL⁻¹). The infection healed within 19 weeks of itraconazole treatment. Cyclosporin blood levels were closely monitored. Twelve months after cessation of treatment, the patient was well and without signs of infection. The bronchus was slightly narrowed due to bronchomalacia on the medial part of the right bronchus with a dark pigmented area in its centre, as shown in figure 3b.

In a second case of invasive bronchial aspergillosis, about 3 weeks after lung transplantation a 54-yr-old patient with bilateral sequential lung transplantation for pulmonary emphysema developed a right-sided pseudomembranous aspergillosis distal to the bronchial suture of the main bronchus obstructing ~80% of the luminal surface area and extending to the intermediate bronchus. Under itraconazole treatment 2×200 mg·day⁻¹ starting on the third postoperative day (because of repeated preoperative *A. fumigatus* growth in sputum) leading to a mean serum level of 1,803 ng·mL⁻¹ (range, 1,126–3,050 ng·mL⁻¹) that was attained since the eight postoperative day the obstruction had regressed slowly. Within 1 month, cultures for *A. fumigatus* became negative; whereas microscopically, the bronchial aspirate was positive until 4.5 months after transplantation. The fungal infection was healed after 6 months of treatment.

Patients with positive biopsies for fungi had no particular predisposing diseases: four had chronic obstructive pulmonary disease, one cystic fibrosis, one primary pulmonary hypertension, one idiopathic pulmonary fibrosis, and one (lung transplantation unrelated) bronchiolitis obliterans. Of the three patients who had had *A. fumigatus* found in their sputum preoperatively, one developed local invasive bronchial aspergillosis (second case described above), although all three had been treated with itraconazole immediately postoperatively. Eight of the nine patients where fungi were found in the biopsies had simultaneously positive respiratory tract cultures for fungi (in all cases at least one positive culture of the bronchial aspirate). For one patient under fluconazole treatment, the culture of the bronchial aspirate of the same bronchoscopy remained

negative, though previous cultures had been positive for *C. albicans*, and microscopy of the bronchial aspirate was consistent with this fungus.

Discussion

Our results show that despite the fact that 84% (26 of 31) of our lung transplant patients had positive respiratory specimens for fungi, no systemic fungal infections were observed using systematic prophylaxis with either fluconazole or itraconazole. No infection developed with fungi resistant to azoles, and amphotericin B has not been required since fungal pneumonia or dissemination did not occur. This favourable result was attained with one side-effect (seizures) probably due to increased cyclosporin levels, but with no other adverse events observed.

Azoles have been shown to be safe and efficient in the prevention of some invasive fungal infections in bone marrow transplantation [16, 17]. However, their preventative role in solid organ transplantation is not certain [18], and their therapeutic effect is clearly limited. Treatment failures have been reported, e.g. an itraconazole treatment failure in one out of six aspergillus tracheobronchitis patients described by KRAMER *et al.* [10]. Because of its property of increasing cyclosporin levels, ketoconazole also has been used in recent heart and kidney transplant studies. A cost-sparing effect was obtained by reducing cyclosporin dosage and because of its efficacy in preventing fungal infections and lower rejection rate [18, 29].

It is not easy to determine the pathogenic role of fungal isolates from the respiratory tract [8, 24], *i.e.* to differentiate between infection, colonization and contamination. Therefore, the specificity and sensitivity of microscopic or culture results of BAL, bronchial aspirate, and sputum are not clear with regard to infection. Several groups are very concerned when fungi are detected in respiratory tract specimens of lung transplant patients. They tend to be aggressive with therapy in cases of fungal contamination or colonization [6, 24, 30], especially with non-candida strains. Others are less concerned [8, 20]. Some groups have observed that preoperative respiratory tract cultures of *Aspergillus* spp. may predispose to dissemination after surgery [9, 15, 31, 32], whereas for other groups this has not been the case [8].

Treatments were performed in 26 of the 31 (84%) patients on 38 occasions in this study. After a mean follow-up of 19.4±15.6 months (±SD) two significant fungal infections were observed among the 23 living patients, in the form of extended ulcerative *A. fumigatus* bronchitis, but with a favourable clinical course. Both infections developed during itraconazole treatment. An adaptation of immunosuppression and high itraconazole serum evidenced by dose monitoring led to the healing of the two invasive aspergilloses. Among eight patients who died after lung transplantation, no deaths were related to fungal infections. In the absence of a randomized study, the efficacy of this reported azoles prophylaxis can only be compared with historical controls, showing an incidence for fungal infection of ~15–25% [1, 4, 6, 9, 10, 13] and a very high mortality rate of 40–70% [1, 2, 12, 33]. The course of disease without fungal bronchopneumonia or systemic fungal infections in these patients suggest that significant protection can be obtained by aggressive azole prophylaxis.

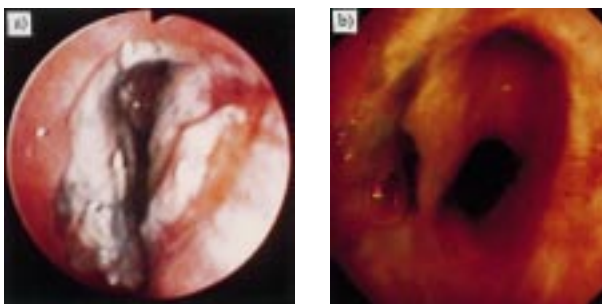


Fig. 3. – *Aspergillus fumigatus* invasion of a bronchial anastomosis. a) 48-yr-old patient with *A. fumigatus* invasion of the right bronchial anastomosis at day 58, suggested by biopsies of the necrotic material narrowing the airway lumen; b) same patient, day 272: residual scar distal to the bronchial suture line. Near normalization of the luminal surface area.

Another positive influencing factor might have been the 5–6 months postoperative intravenous gancyclovir prophylaxis used in the cases of the cytomegalovirus-positive donor or recipient, which have been shown to significantly reduce not only viral infections but also concomitant fungal infections in one study with heart transplant patients [34]. In one study with lung transplant patients, an association of cytomegalovirus pneumonias with invasive aspergillosis was found [9].

Primary or secondary resistance to the antifungal drugs used may develop [23]. This poses several problems. Until now no microbiological susceptibility tests have been standardized and widely used, leaving the choice of antifungal agent normally to be based on the species diagnosis and sensitivity, as reported in the literature. Whereas the short-term use of triazoles does not appear to be problematic, ~5% of patients with advanced acquired immune deficiency syndrome (AIDS) under long course treatment of noninvasive candida infections develop secondary resistance of *C. albicans* and *C. glabrata* to fluconazole. Relative triazole cross-resistances and the first rare reports of *A. fumigatus* strains resistant to itraconazole have been reported [35]. These potential resistances are of concern in lung transplant patients, as severe infections may ensue any time after colonization, and clinical parameters of true infection may be late [6, 7, 12] or insufficient to detect a failure of prophylaxis in time.

Itraconazole exists at present only as an oral formula. Intra- and interindividual itraconazole absorption and metabolism are extremely variable. Whereas concomitant food intake augments the absorption by a factor of 2 or 3 [22], antacids, histamine H₂-blocking agents or cytochrome inducers such as rifampin and phenytoin may lead to undetectable serum levels and treatment failures [21, 28]. Itraconazole drug levels are therefore recommended to be monitored once monthly in solid organ transplant patients [23]. Cyclosporin and tacrolimus doses must be closely controlled and adapted over at least 2–3 weeks during initiation or cessation of azole treatment [22, 28]. Fluconazole shows less important interactions with cyclosporin and tacrolimus than itraconazole or ketoconazole [28], its absorption is not altered by food or gastric acidity, and steady-state concentrations are more rapidly reached. It also exists as an *i.v.* formula [22]. Significant interactions exist with azoles and cytochrome P450-metabolized drugs such as histamine H₁ antagonists, cisapride, or midazolam [28].

The optimal length of treatment, drug serum level [4], the value and mode of a microbiological re-evaluation including sequential drug susceptibility testing [4], as well as the benefit of a perioperative prophylaxis have not yet been clarified.

In this series nine out of 31 patients had positive bronchial biopsies for fungi. Two had an invasive pseudomembranous aspergillus bronchitis as described by KRAMER *et al.* [10], whereas in the other seven patients the fungi invaded necrotic tissue, making the distinction between colonization and infection difficult. Necrotic tissue with cartilage invaded with large quantities of fungi was found in five of the nine patients. Two of them had the appearance of invasive tracheobronchitis, whereas the others may be intermediate forms of the gradual evolution from colonization to microscopical and clinical invasion.

As an alternative to low-dose systemic prophylaxis [11, 14], aerosolized amphotericin B prophylaxis, in heart, lung, and heart–lung transplant patients during the intrahospital postoperative period has been shown to be effective in an uncontrolled study, suggesting this early period to be critical in the development of fungal infections [15]. The high prevalence of positive respiratory tract fungal cultures found as well as of invasive fungal infection early after transplantation would also favour this approach, either with itraconazole, or with newer agents directed against aspergillus or *Candida* spp. Whether topical application offers an advantage in penetrating the necrotic tissue or exudate in which fungi grow at the bronchial anastomosis remains to be elucidated.

In conclusion, positive fungal respiratory tract specimens have been found in a very high proportion of lung transplant patients during their evolution. This data and similar observations from several other groups favour the hypothesis that azole treatment may be of value in the prevention of fatal invasive fungal disease in those patients [6, 24]. This prophylaxis appears well-tolerated. The results may justify controlled multicentre studies with currently available or newer azole or nonazole antifungal agents.

Acknowledgements. The authors thank the Geneva Lung Transplantation Group, in particular their colleagues in the Thoracic Surgery Unit, P.M. Suter and associates in the Surgical Intensive Care Division, M. Licker and colleagues in the Dept of Anaesthesiology, T. Rochat and collaborators in the Pulmonary Division, and S. Suter, C. Barazzone and colleagues in the Paediatric Dept for their invaluable collaboration. They thank P. Rohner, R. Auckenthaler, K. Wafa and collaborators at the Microbiologic Laboratory, Division of Infectious Diseases, Dept of Internal Medicine for their support and the bacteriological and mycological analyses. They greatly acknowledge the comments of B.R. Low, University of Burlington, Vermont, USA.

References

1. Maurer JP, Tullis DE, Grossman RF, Vellend H, Winton TL, Patterson GA. Infectious complications following isolated lung transplantation. *Chest* 1992; 101: 1056–1059.
2. Kramer MR, Marshall SE, Starnes VA, Gamberg P, Amitai Z, Theodore J. Infectious complications in heart–lung transplantation. Analysis of 200 episodes. *Arch Intern Med* 1993; 153: 2010–2016.
3. Hibberd PL, Rubin RH, Rubin RH. Clinical aspects of fungal infection in organ transplant recipients. *Clin Infect Dis* 1994; 19: Suppl. 1, S33–S40.
4. Kanj SS, Welty-Wolf K, Madden J, *et al.* Fungal infections in lung and heart–lung transplant recipients. Report of 9 cases and review of the literature. *Medicine* 1996; 75: 142–156.
5. Keenan RJ, Konishi H, Kawai A, *et al.* Clinical trial of tacrolimus versus cyclosporine in lung transplantation. *Ann Thorac Surg* 1995; 60: 580–584.
6. Paradis IL, Williams P. Infection after lung transplantation. *Semin Respir Infect* 1993; 8: 207–215.

7. Chaparro C, Maurer JR, Chamberlain D, *et al.* Causes of death in lung transplant recipients. *J Heart Lung Transplant* 1994; 13: 758–766.
8. Paradowski LJ. Saprophytic fungal infections and lung transplantation – revisited. *J Heart Lung Transplant* 1997; 16: 524–531.
9. Yeldandi V, Laghi F, McCabe MA, *et al.* Aspergillus and lung transplantation. *J Heart Lung Transplant* 1995; 14: 883–890.
10. Kramer MR, Denning DW, Marshall SE, *et al.* Ulcerative tracheobronchitis after lung transplantation. A new form of invasive aspergillosis. *Am Rev Respir Dis* 1991; 144: 552–556.
11. Dauber JH, Paradis IL, Dummer JS. Infectious complications in pulmonary allograft recipients. *Clin Chest Med* 1990; 11: 291–308.
12. Paya CV. Fungal infections in solid-organ transplantation. *Clin Infect Dis* 1993; 16: 677–688.
13. Laghi F, Yeldandi V, McCabe M, Garrity ERJ. Common infections complicating lung transplantation. *N Engl J Med* 1993; 90: 313–319.
14. Shennib H, Noirclerc M, Ernst P, *et al.* Double-lung transplantation for cystic fibrosis. *Ann Thorac Surg* 1992; 54: 27–32.
15. Reichenspurner H, Gamberg P, Nitschke M, *et al.* Significant reduction in the number of fungal infections after lung, heart–lung, and heart transplantation using aerosolized amphotericin B prophylaxis. *Transpl Proc* 1997; 29: 627–628.
16. Goodman JL, Winston DJ, Greenfield RA, *et al.* A controlled trial of fluconazole to prevent fungal infections in patients undergoing bone marrow transplantation. *N Engl J Med* 1992; 326: 845–851.
17. Slavin MA, Osborne B, Adams R, *et al.* Efficacy and safety of fluconazole prophylaxis for fungal infections after marrow transplantation. A prospective, randomized, double blind study. *J Infect Dis* 1995; 171: 1545–1552.
18. Sobh M, El-Agroudy A, Moustafa F, Harras F, El-Bedewy M, Ghoneim M. Coadministration of ketoconazole to cyclosporin-treated kidney transplant recipients: a prospective randomized study. *Am J Nephrol* 1995; 15: 493–499.
19. Warnock DW. Fungal complications of transplantation: diagnosis, treatment and prevention. *J Antimicrob Chemotherapy* 1995; 36 (Suppl. B): 73–90.
20. Flume PA, Egan TM, Paradowski LJ, Detterbeck FC, Thompson JT, Yankaskas JR. Infectious complications of lung transplantation. Impact of cystic fibrosis. *Am J Respir Crit Care Med* 1994; 149: 1601–1607.
21. Patterson TF, Peters J, Levine SM, *et al.* Systemic availability of itraconazole in lung transplantation. *Antimicrob Agents Chemother* 1996; 40: 2217–2220.
22. Como JA, Dismukes WE. Oral azole drugs as systemic antifungal therapy. *N Engl J Med* 1994; 330: 263–272.
23. Working Party of the British Society for Antimicrobial Chemotherapy. Chemoprophylaxis for candidosis and aspergillosis in neutropenia and transplantation: a review and recommendations. *J Antimicrob Chemotherapy* 1993; 32: 5–21.
24. Trulock EP. Lung transplantation. *Am J Respir Crit Care Med* 1997; 155: 789–818.
25. Baselski VS, Robinson MK, Pifer LW, Woods DR. Rapid detection of *Pneumocystis carinii* in bronchoalveolar lavage samples by using Cefluor staining. *J Clin Microbiol* 1990; 28: 393–394.
26. Larone DH. Medically Important Fungi. A Guide to Identification. Washington DC, American Society for Microbiology, 1995; pp. 227–228.
27. Tricot G, Joosten E, Boogaerts MA, Vande Pitte J, Cauwenbergh G. Ketoconazole vs. itraconazole for antifungal prophylaxis in patients with severe granulocytopenia: preliminary results of two nonrandomized studies. *Rev Infect Dis* 1987; 9 (Suppl. 1): S94–S99.
28. Albengres E, Le Louet H, Tillement JP. Systemic antifungal agents. Drug interactions of clinical significance. *Drug Safety* 1998; 18: 83–97.
29. Keogh A, Spratt P, McCosker C, Macdonald P, Mundy J, Kaan A. Ketoconazole to reduce the need for cyclosporine after cardiac transplantation. *N Engl J Med* 1995; 333: 628–633.
30. Tanoue LT. Lung transplantation. *Lung* 1992; 170: 187–200.
31. Kawai A, Paradis IL, Keenan RJ, *et al.* Lung transplantation at the University of Pittsburgh: 1982–1994. *Clin Transpl* 1994; 111–120.
32. Biggs VJ, Dummer S, Holsinger FC, Loyd JE, Christman BW, Frist WH. Successful treatment of invasive bronchial aspergillosis after single-lung transplantation. *Clin Infect Dis* 1994; 18: 123–124.
33. Chaparro C, Kesten S. Infections in lung transplant recipients. *Clin Chest Med* 1997; 18: 339–351.
34. Wagner JA, Ross H, Hunt S, *et al.* Prophylactic gancyclovir treatment reduces fungal as well as cytomegalovirus infections after heart transplantation. *Transplantation* 1995; 60: 1473–1477.
35. Denning DW, Venkateswarlu K, Oakley KL, *et al.* Itraconazole resistance in *Aspergillus fumigatus*. *Antimicrob Agents Chemother* 1997; 41: 1364–1368.