

CASE STUDY

False-positive diagnosis of pulmonary hypertension by Doppler echocardiography

J.L. Vachiéry*, S. Brimiouille**, V. Crasset*, R. Naeije**

False-positive diagnosis of pulmonary hypertension by DOPPLER echocardiography. J.L. Vachiéry, S. Brimiouille, V. Crasset, R. Naeije. ©ERS Journals Ltd 1998.

ABSTRACT: A 37-yr-old female presented with a history of several months of exertional dyspnoea. A diagnosis of primary pulmonary hypertension was suspected on the basis of a negative extensive cardiorespiratory work-up with a systolic pulmonary artery pressure of 41–46 mmHg calculated from repeated measurement of the maximum velocity of tricuspid regurgitation jets at 2.8–3 m·s⁻¹ by continuous-wave Doppler echocardiography. However, a right heart catheterization with a high-fidelity transducer-tipped catheter revealed pulmonary artery pressures of 22/8 mmHg at rest, which remained within normal limits at exercise. This case indicates a possible misleading overestimation of pulmonary artery pressures from Doppler echocardiographic studies of tricuspid regurgitation.

Eur Respir J 1998; 12: 1476–1478.

*Medical-Surgical Dept of Cardiology and
**Dept of Intensive Care, Erasme University Hospital, Brussels, Belgium.

Correspondence: J.L. Vachiéry, Dept of Cardiology, Erasme University Hospital, 808, Lennik Road, B-070 Brussels, Belgium. Fax: 32 25556652

Keywords: Echocardiography, pulmonary hypertension, transducer-tipped pulmonary catheter, tricuspid regurgitation

Received: May 5 1998

Accepted after revision August 6 1998

Doppler echocardiography has increasingly been used in recent years for the noninvasive diagnosis of pulmonary hypertension [1, 2], and is currently integrated as an early step in diagnostic algorithms [3]. One popular technique is the measurement of the maximum velocity of tricuspid regurgitation jets for the estimation of systolic pulmonary artery pressure, as first reported by YOCK and POPP [4] in 1984. This technique is now generally believed to be reasonably accurate and repeatable [1–3]. However, there may be an underestimation of pressures measured concomitantly with a high-fidelity transducer-tipped catheter in patients with severe pulmonary hypertension [5], and recovery of sufficient quality signals may be a problem in patients with chronic obstructive pulmonary disease (COPD) [6]. Until now, there has been no report of a clinically relevant overestimation of pulmonary artery pressures by Doppler echocardiography.

Case report

A 37-yr-old nonsmoking female cook presented with a 3-month history of exertional dyspnoea, typically when climbing stairs carrying a light load or dancing. Two years before, she had been treated with an angiotensin-converting enzyme inhibitor for a diagnosis of systemic hypertension. Her medical history disclosed no other abnormalities. Her clinical examination was normal, with a weight of 60 kg, a height of 164 cm, a blood pressure of 140/80 mmHg and a cardiac frequency (*f*_C) of 76 beats·min⁻¹. The electrocardiogram and chest radiography were normal. A sample of arterial blood showed an arterial oxygen tension (*P*_{a,O₂}) of 15.4 kPa (116 mmHg), an arterial carbon dioxide tension (*P*_{a,CO₂}) of 4.1 kPa (31 mmHg) and a pH of 7.45. Lung function tests showed normal val-

ues for volumes, airway resistance and carbon monoxide diffusing capacity. An echocardiograph was normal, with no right atrial or ventricular dilatation, no valvular abnormality and no abnormal characteristics of Doppler inferior vena cava flow. A pulsed Doppler study of pulmonary blood flow revealed normal-shaped flow-velocity waves, with an acceleration time of 122 ms (normal: 110–162 ms) and a ratio between acceleration time and ejection time of 0.39 (normal: 0.34–0.51). However, continuous Doppler studies of tricuspid regurgitation repeatedly showed maximum velocities between 2.8–3 m·s⁻¹ (normal: 1.5–2.5 m·s⁻¹), allowing for an estimated systolic pulmonary artery pressure between 41–46 mmHg. The limits of normal for maximum velocities of tricuspid regurgitation, and of acceleration times and ratio between acceleration and ejection times of pulmonary flow velocities, were established from previously reported measurements in 20 healthy young adults [7].

A diagnosis of primary pulmonary hypertension was suspected on the basis of a negative cardiorespiratory work-up, with a positive Doppler echocardiographic measurement [3], and the patient, therefore, underwent a right heart catheterization. This examination was performed with a balloon-tipped, high-fidelity, transducer-tipped thermodilution catheter (Hugos Sentron, Ohmeda, Roden, the Netherlands). At rest, pulmonary artery pressure was 22/8 (mean 13 mmHg), pulmonary artery occluded pressure 8 mmHg, right atrial pressure 6 mmHg, cardiac output 4.9 L·min⁻¹, *f*_C 82 beats·min⁻¹ and pulmonary vascular resistance 82 dyne·s⁻¹·cm⁻⁵. During exercise, pedalling without a load in supine position, mean pulmonary artery pressure was 20 mmHg, pulmonary artery occluded pressure 14 mmHg, right atrial pressure 10 mmHg, cardiac output 9.6 L·min⁻¹, *f*_C 110 beats·min⁻¹ and pulmonary vascular resistance 48 dyne·s⁻¹·cm⁻⁵. A full Doppler echocardiographic

examination was performed simultaneously (Hewlett-Packard Sonos 5500, Andover, USA). The presence of a tricuspid regurgitation was confirmed by colour-coded Doppler and recorded in continuous-wave mode from the apical four-chamber view. Pulmonary blood flow velocity was obtained in the right ventricular outflow tract from the parasternal short-axis view just below the pulmonic valve. The pulsed-wave Doppler sample of 3 mm was moved along the ultrasound beam to obtain the highest maximal velocity. To minimize errors on Doppler recordings, angle correction was avoided and colour-coded Doppler helped to achieve the best alignment of blood flow with an ultrasound beam. Pulmonary and tricuspid Doppler recordings are shown in figure 1, together with the catheter pressure measurements. All measurements were performed at end-expiration. Systolic right ventricular and pulmonary artery pressures were superimposable. The maximum velocity of tricuspid regurgitation jets averaged over four cardiac cycles was $2.87 \text{ m}\cdot\text{s}^{-1}$, allowing the calculation of a transtricuspid gradient of 33 mmHg, and a systolic right ventricular pressure of 40 mmHg was found by adding the invasively measured right atrial pressure at 7 mmHg. At the same time, pulmonary artery systolic pressure was measured at 22 mmHg. Seven cardiac cycles were used to measure the pulmonary artery blood flow velocity. Mean values for acceleration time, ejection time and the ratio between acceleration and ejection times were 122 ms, 316 ms and 0.39, respectively.

Discussion

This is the first reported case of a wrong diagnosis of pulmonary hypertension on the basis of Doppler echocardiographic studies of tricuspid regurgitation.

The recording of tricuspid regurgitation jets by continuous-wave Doppler echocardiography was first reported in

1984 by YOCK and POPP [4] in a series of 62 patients with right heart failure. The authors calculated a transtricuspid gradient ($\dot{\gamma}P$) from the maximum velocity (v) of tricuspid regurgitation using the simplified form of the Bernoulli equation, $\dot{\gamma}P \text{ (mmHg)} = 4 \times v^2 \text{ (m}\cdot\text{s}^{-1})$. Adding $\dot{\gamma}P$ to a clinical estimate of right atrial pressure yielded predicted systolic right ventricular pressures which were very close to those obtained by catheterization, even if not studied simultaneously [4]. The method has now been widely used in patients with pulmonary hypertension secondary to a variety of cardiac diseases, with reported correlations between Doppler and catheter measurements ranging 89–0.97, interobserver variability of <3% and average standard errors on systolic pulmonary artery pressure ranging 5–9 mmHg [1, 2]. In patients with COPD, the recovery rate of good-quality tricuspid regurgitation signals is decreased and the standard error on systolic pulmonary artery pressure may increase to an average of 12 mmHg [6].

Lack of agreement between Doppler and catheter measurements is usually explained by a variety of factors, including nonsimultaneous invasive measurements, clinical estimate instead of direct measurement of right atrial pressure, sonic unavoidable beam to flow angle, uncertainty in the assignment of the maximum velocity of the regurgitant signal, the fact that $\dot{\gamma}P$ may be maximal before peak right ventricular systolic pressure in the presence of a prominent right atrial V-wave, and some gradient between right ventricular and pulmonary artery pressures, more or less positive in early systole and negative in late systole, depending on the severity and type of pulmonary hypertension [2]. An additional problem is that most previous studies used fluid-filled Swan Ganz catheters, the frequency response of which is insufficient for measurements of instantaneous pulmonary artery pressures [2]. Thus, although some studies on large series of patients include a few examples of Doppler overestimations of systolic pulmonary artery pressure by up to around 20 mmHg,

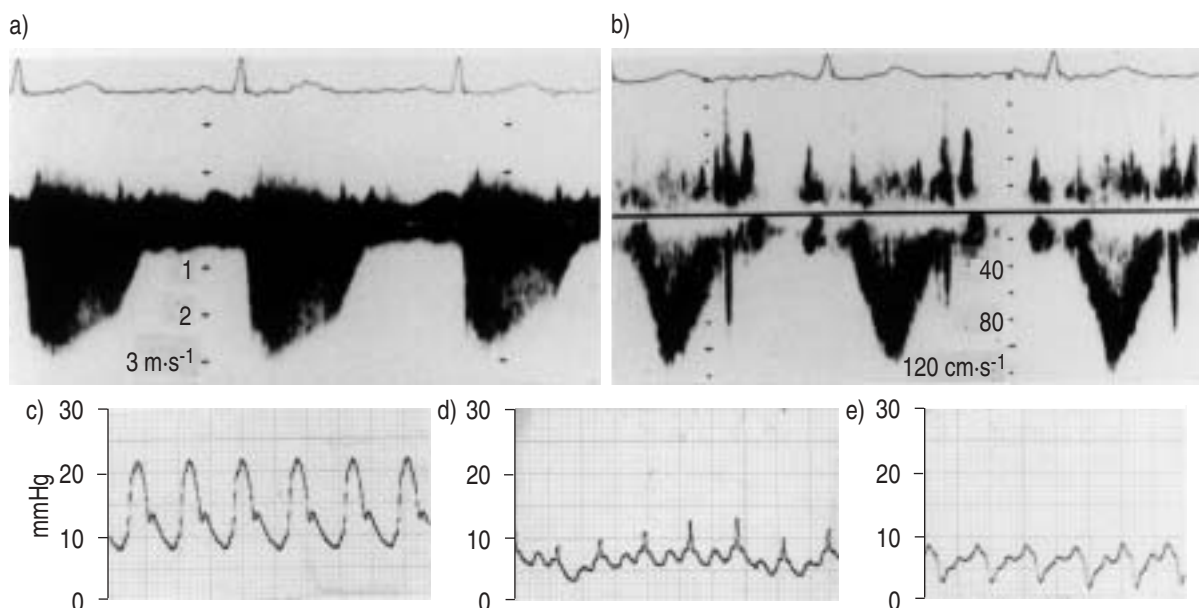


Fig. 1. – Doppler studies of a) tricuspid regurgitation and b) pulmonary artery flow velocity (with electrocardiogram (ECG) traces above) and concomitant measurements of c) pulmonary artery pressure, d) pulmonary artery occluded pressure (by a high-fidelity transducer-tipped catheter) and e) right atrial pressure (by a fluid-filled catheter) in a patient with suspected primary pulmonary hypertension. The calculated systolic pulmonary artery pressure from the maximum velocity of the tricuspid regurgitation jet led to an overestimation of systolic pulmonary artery pressure by 20 mmHg.

as observed in the present patient [6, 8, 9], they do not allow a reliable estimate of the maximum possible errors, because the "real" concomitant pressures are not known.

Estimates of systolic pulmonary artery pressures from Doppler tricuspid regurgitation have been compared to simultaneous pressure measurements by high-fidelity, transducer-tipped catheters in only one previous study [5]. In 10 patients with severe pulmonary hypertension an important underestimation of right ventricular systolic pressure was found, with an average catheter-Doppler difference of 21 mmHg, which the authors attributed to the assumptions on the geometry of the tricuspid orifice on which the simplified form of the Bernoulli equation is based [5]. It is interesting to note that peak right ventricular systolic pressure was overestimated by Doppler tricuspid regurgitation in only one of the 10 patients, by an absolute amount of 8 mmHg.

In the present patient, the Doppler signal was excellent and care was taken to ensure that the bloodstream was parallel to the Doppler beam. Right atrial pressure was measured directly, avoiding errors in estimated systolic pulmonary artery pressures by adding and arbitrary or clinically or echographically derived values. There was no enlarged V-wave on the right atrial pressure tracing. The tricuspid regurgitation was mild, as expected in a subject with normal bidimensional echocardiograms, but the signal was of good quality. The systolic right ventricular and pulmonary artery pressure tracings were superimposable, excluding the possibility of a right ventricular outflow tract obstruction that would have been missed at echo-Doppler examination.

The overestimation of pulmonary artery pressures by Doppler echocardiography of tricuspid regurgitation in this patient cannot be readily explained. The error was large enough to support a late positive diagnosis of pulmonary hypertension. However, it is important that the Doppler pulmonary artery flow wave had a normal shape, with an acceleration time of 128 ms, well within normal limits, and that there was no other echo cardiographic clue to pulmonary hypertension. False-positive diagnosis of pulmonary hypertension on the basis of Doppler echocardiography of tricuspid regurgitation seems to be uncommon and can probably be avoided if all other echo-Doppler signals usually found in pulmonary hypertension [1, 2] are also care-

fully taken into consideration. Our recommendation, therefore, is not to disregard the echo-Doppler examination of tricuspid regurgitation as an early essential step in the diagnosis of pulmonary hypertension, but rather to integrate it within the context of a complete echocardiographic examination.

References

1. Raeside D, Peacock AJ. Making measurements in the pulmonary circulation: when and how? *Thorax* 1997; 52: 9–11.
2. Naeije R, Torbicki A. More on the noninvasive diagnosis of pulmonary hypertension: Doppler echocardiography revisited. *Eur Respir J* 1995; 8: 1445–1449.
3. D'Alonzo GE, Dantzker DR. Diagnosing primary pulmonary hypertension. In: Rubin LJ, Rich S, eds. Primary Pulmonary Hypertension. New York, Marcel Dekker, Chap. 9, 1997; pp. 227–252.
4. Yock PG, Popp RL. Noninvasive estimation of right ventricular systolic pressure by Doppler ultrasound in patients with tricuspid regurgitation. *Circulation* 1984; 70: 657–662.
5. Brecker SJD, Gibbs SR, Fox KM, Yacoub MH, Gibson DG. Comparison of Doppler derived haemodynamic variables and simultaneous high fidelity pressure measurement in severe pulmonary hypertension. *Br Heart J* 1994; 72: 384–389.
6. Tramarin R, Torbicki A, Marchandise B, Laaban JP, Mompurgo M. Doppler echocardiographic evaluation of pulmonary artery pressure in chronic obstructive pulmonary disease. A European multicentre study. *Eur Heart J* 1991; 12: 103–111.
7. Vachiéry JL, McDonagh T, Moraine JJ, *et al.* Doppler assessment of hypoxic pulmonary vasoconstriction and susceptibility to high altitude pulmonary oedema. *Thorax* 1995; 50: 22–27.
8. Currie PJ, Seward JB, Chan KL, *et al.* Continuous wave Doppler determination of right ventricular pressure: a simultaneous Doppler-catheterization study in 127 patients. *J Am Coll Cardiol* 1985; 6: 750–756.
9. Chan KL, Currie PJ, Seward JB, Hagler DJ, Mair DD, Tajik J. Comparison of three Doppler ultrasound methods in the prediction of pulmonary artery pressure. *J Am Coll Cardiol* 1987; 9: 549–554.