

Cytology of bronchial biopsy rinse fluid to improve the diagnostic yield for lung cancer

A. Rosell*, E. Monsó*, L. Lores*, X. Vilà*, M. Llatjós**, J. Ruiz*, J. Morera*

Cytology of bronchial biopsy rinse fluid to improve the diagnostic yield for lung cancer. A. Rosell, E. Monsó, L. Lores, X. Vilà, M. Llatjós, J. Ruiz, J. Morera. ©ERS Journals Ltd 1998.

ABSTRACT: Sampling techniques are combined during bronchoscopy to increase the diagnostic yield for endobronchial malignant tumours. Bronchial biopsy provides the definitive histological diagnosis in most cases, but accompanying cytological procedures such as washing, brushing, needle aspiration or imprint cytology can increase diagnostic yield. In this prospective study, a different cytological technique, that could enhance the diagnostic yield of bronchoscopy without increasing its time or cost, was tested.

Flexible bronchoscopy was performed in 93 patients suspected of having pulmonary neoplasms. Bronchial biopsies were initially placed in a balanced salt solution. When bronchoscopy was finished, all visible tissue fragments were removed and placed in formalin to undergo histopathological examination and the rinse fluid was sent for cytological examination. Washing was performed routinely but no cytological brushing was employed.

Eighty-two patients had final diagnoses of malignant neoplasm. In four (4.8%) of these patients, the only positive result came from the cytological examination of the bronchial biopsy rinse fluid. No false-positive results were found. The agreement with the histological results was 81.8%. The addition of bronchial biopsy rinse-fluid examination increased the sensitivity of bronchoscopy from 65.8% to 70.7% (McNemar's $p=0.009$).

The cytological study of bronchial biopsy rinse fluid offers reliable positive results in an additional 4.8% of cases, thus enhancing bronchoscopic diagnostic yield for malignant endobronchial tumours while neither prolonging the procedure nor increasing costs.

Eur Respir J 1998; 12: 1415–1418.

*Servei de Pneumologia and **Servei d'Anatomia Patològica, Hospital Universitari "Germans Trias i Pujol", Badalona, Barcelona, Catalonia, Spain.

Correspondence: A. Rosell
Servei de Pneumologia
Hospital Universitari "Germans Trias i Pujol"
Carretera de Canyet s/n
08916 Badalona
Barcelona
Catalonia
Spain.
Fax: 349 34978843

Keywords: Biopsy
bronchoscopy
cancer
cytology
diagnosis
lung

Received: January 16 1998

Accepted after revision July 10 1998

Bronchoscopic techniques performed for the diagnosis of endobronchial lesions include bronchial biopsy and some accompanying cytological procedures such as needle aspiration and bronchial washing or brushing. Some combinations of these techniques are reported to increase diagnostic yield for lung cancer [1–14]. Harvesting cellular debris shed from cytological or histology specimens has proven useful in some respiratory diagnostic procedures, such as trans-thoracic needle aspiration [15], bronchoscopic needle aspiration [16] and brushing [17, 18]. The saline solution used to rinse and handle the specimens in these procedures is cytologically examined. Examination of rinse fluid from bronchial biopsies, however, has only been mentioned once in the literature, in 1975 [4]. This study, therefore, tested the value of this apparently forgotten cytological technique, which can be used routinely whenever bronchial biopsies are performed and would, therefore, be cost-effective if shown to improve diagnostic yield.

Materials and methods

This study was carried out on 93 consecutive patients suspected of having pulmonary neoplasms who were referred to the authors' university hospital for bronchoscopy.

Flexible bronchoscopy was performed transnasally with an Olympus 200 (Olympus, Tokyo, Japan) or a Pentax 15X (Pentax, Tokyo, Japan), under topical 2% lidocaine and *i.v.* midazolam ($0.07 \text{ mg}\cdot\text{kg}^{-1}$) anaesthesia. All patients had single endobronchial lesions suspected of being malignant and were sampled with 2 mm Olympus alligator jaw forceps to obtain at least three specimens from each case. Based on their endoscopic appearance, endobronchial lesions were classified as having either direct (endobronchial tumour, exophytic and irregular mucosa) or indirect signs of malignancy (inflamed mucosa, extrinsic compression). Bronchial washings were routinely collected for cytology. No brushing was performed as this technique is employed in the authors' hospital only for visible lesions that cannot be reached with the biopsy forceps.

The biopsy specimens obtained were initially placed in 5 mL of balanced salt solution. When flexible bronchoscopy was finished, all tissue fragments visible to the naked eye were gently removed with tweezers forming part of the same endoscopic respiratory unit and transferred to another plastic medicine cup for fixing in 10% buffered formalin to undergo histopathological examination. The 5 mL rinse fluid, now containing cells shed from all the bronchial biopsy specimens, was sent to the laboratory within

1 h of specimen collection, before autolysis could take place, then processed in the cytospin (Shandon®; Shandon, Zeist, Holland) and finally stained by Papanicolaou's cytological method.

The specimens were classified as benign, dysplastic, suspicious or positive with respect to malignancy. The positive smears were then typed as adenocarcinoma, squamous cell carcinoma, small cell carcinoma, large cell carcinoma, nonsmall cell carcinoma, undifferentiated carcinoma and metastatic carcinoma. The cytological and histological specimens were evaluated independently, with the cytopathologist blinded as to the histological results, and *vice versa*. For the purpose of this study, dysplastic and suspicious results were considered negative to avoid false positives.

All statistical tests comparing the sensitivity of bronchoscopy techniques used two-sample tests for matched-pair data (McNemar's test).

Results

Of the 93 patients, 82 had final diagnoses of malignancy (by positive specimens from bronchoscopy, transthoracic needle aspiration, surgery or autopsy). The other 11 patients were diagnosed with pneumonia (four cases), tuberculosis (three), bronchiectasis (two), mycobacteriosis (one case) and bronchiolitis obliterans (one).

Bronchoscopic biopsies were positive in 48/82 patients. Fifty-eight patients had direct endoscopic signs of invasion, with positive biopsies in 77.5% of them, while 12.5% in the group with indirect endoscopic signs of invasion had positive biopsies for cancer. Cytological specimens significantly increased the sensitivity of bronchoscopy, as in 10 patients the final diagnoses were provided by washings and/or rinse fluid of bronchial biopsies (fig. 1). The final diagnostic yield of bronchoscopy increased from 58.5 to 70.7% (table 1).

The malignancy results for all biopsies and rinse-fluid cytology are shown in table 2. There was a high degree of

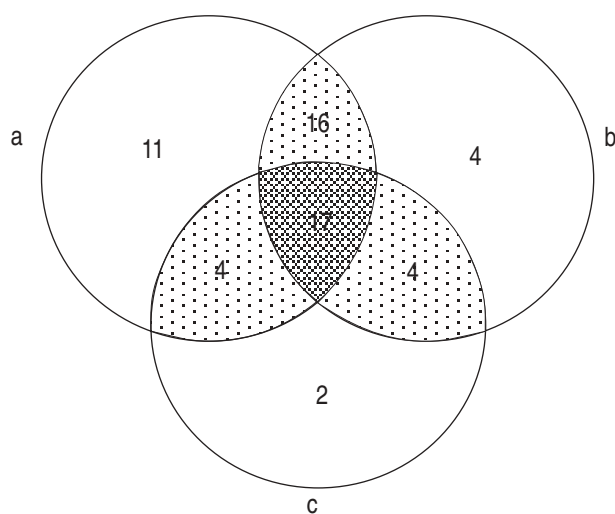


Fig. 1. — Venn diagram showing the positive results for each technique, presented with their coincidences. a) Bronchial biopsy; b) rinse-fluid cytology; c) bronchial washing. The dark grey area represents the cases in which all three procedures were positive.

Table 1. — Sensitivity of forceps biopsy, bronchial washing and bronchial biopsy rinse fluid in flexible bronchoscopy of endobronchial lesions for the diagnosis of cancer

	Positive specimens n	Sensitivity for diagnosis of cancer %
Bronchial biopsy	48	58.5 (47.9–69.0)
Washing	27	32.9 (22.7–43.0)
Rinse-fluid cytology	41	50.2 (39.4–60.9)
Bronchial biopsy plus washing	54	65.8 (55.6–75.9)
Bronchial biopsy plus rinse-fluid cytology	56	68.2 (58.2–78.2)
Bronchial biopsy plus washing and rinse-fluid cytology	58	70.7 (60.9–80.5)

Values shown in parentheses are 95% confidence intervals. n=82.

agreement in positivity (33/82) as well as negativity (26/82) between the two diagnostic techniques, indicating an accuracy of 71.9% (59/82). The sensitivity and specificity of the rinse fluid technique were 50 and 100%, respectively. The positive predictive value was 100% and the negative predictive value was 21%.

The combination of a positive biopsy and a negative rinse-fluid cytology result (15 cases) occurred mainly in cases of nonsmall cell carcinoma (eight squamous, two adenocarcinoma, two small cell carcinoma, two undifferentiated and one melanoma). A positive rinse-fluid cytology result, along with a negative biopsy, was found in eight out of 82 (9.7%) patients, four of whom also had positive bronchial washings. None of the other four patients, for whom rinse-fluid cytology results were the only evidence for malignancy, had false-positive results, as cancer was confirmed in all of them by late obtention of histological evidence (three during surgery and one by autopsy). The bronchoscopic appearance of the lesions was: indirect signs of malignancy in three and direct signs of malignancy in one. Their cytological diagnoses were: two adenocarcinoma, one undifferentiated carcinoma and one nonsmall cell carcinoma. The sensitivity for diagnosis of cancer increased from 65.8 to 70.7% (McNemar's $p=0.009$) (table 1).

Comparing the diagnoses by positive bronchial biopsy and positive rinse-fluid cytology, it was found that, in 27 out of 33 (81.8%) the histological findings agreed fully with the cytological results. Rinse-fluid cytology gave the correct histopathological group (nonsmall cell carcinoma or small cell carcinoma), but with incorrect typing in four cases and wrongly diagnosed one small cell pulmonary carcinoma as a squamous carcinoma.

The quality of the bronchial biopsies was altered by neither the short time of suspension in the balanced salt solution nor the gentle manipulation with tweezers, according to the pathologist's final description.

Table 2. — Correlation between bronchial biopsy and rinse-fluid cytology results in 82 patients with lung cancer

	Bronchial biopsy	
Rinse-fluid cytology	Positive	Negative
Positive	33	8
Negative	15	26

Discussion

The examination of rinse fluid from bronchial biopsies was first mentioned by ZAVALA [4] as early as 1975. This author published a broad description of all diagnostic techniques performed during flexible bronchoscopy on the largest series of patients at that time. Nevertheless, this technique was not analysed separately from the others, so that no conclusion as to its particular diagnostic yield can be reached from that paper. The technique has not been further described as being used in bronchoscopy until now.

In the present study, the cytological analysis of the rinse fluid from bronchial biopsies increased the sensitivity of the diagnosis of cancer by 4.8% (from 65.8 to 70.7%, McNemar's $p=0.009$), meaning that for four out of 82 patients, in whom lung cancer was diagnosed, the only positive result for malignancy was that provided by bronchial biopsy rinse fluid. These cells are probably at the boundary between normal tissue and the tumour. This cytological technique (based simply on collecting cells shed from the biopsy specimen) involves no additional time or expenditure during bronchoscopy, obtains a specimen from the precise endoscopic site of the abnormality and has an absolute specificity for malignancy and a good agreement with histological typing (81.8%).

The apparently low percentage of positive bronchial biopsies is similar to published data, when only true endobronchial lesions are considered and extrinsic compression is excluded. GELLERT *et al.* [19] found 78.6% positive in the group of true endobronchial lesions and 26.8% when only indirect signs of malignancy were considered. MINAMI *et al.* [20] classified endobronchial lesions according to the criteria of the Japanese Lung Cancer Society, finding a rate of positive results for epithelial lesions of 97% and for extramural lesions of 25%. In the present study, the rate of positive results for true endobronchial lesions was 77.5%, but only 12.5% in lesions with indirect signs of neoplastic invasion.

Cytological techniques known to enhance the diagnostic yield for a visible tumour in bronchoscopy include imprint cytology, needle aspiration, brushing and bronchial washings. Imprint cytology is used with good results, mainly with larger biopsy specimens. Some authors have applied this technique to bronchial biopsy, removing the tissue from the forceps and rolling it over the surface of a glass slide. POPP *et al.* [10] found that this procedure yields a higher number of positive results than does forceps biopsy histology (84.9 versus 62.9%); however, no other authors have reported using this technique in the last 10 yrs. This technique is considered to be unsuitable for bronchial biopsies, as tissue can be damaged during the smear manoeuvre. When tumours are vascular, highly necrotic or have submucosal proliferation it is useful to obtain a cytological specimen by needle aspiration, which yielded diagnostic information in 92% of a recent series [14]. Other than these indications, the practice of needle aspiration for endobronchial lesions is not recommended. Brushing, in contrast, is commonly used, even though findings of malignancy are low, when other bronchoscopic procedures give negative results. The percentages reported range 0 [8] to 4.8% [5]. Additional drawbacks to brushing are that it prolongs the bronchoscopic procedure, can cause bleeding and makes the procedure more expensive, as each disposable brush cost US\$9–10.50 in 1996 [1, 21]. Brushing,

however, remains a good candidate for sampling lesions that cannot be taken by forceps biopsy. Finally, bronchial washings are performed routinely because they are easy to collect, provide material suitable for both cytological and microbiological study and have a rate of positive diagnosis of central tumours ranging 46 [8] to 88.5% [22]. The incremental sensitivity over endobronchial biopsies ranges 4.8 [1] to 19% [22]. In the present study, bronchial washings were positive in 27 out of 82 (32.9%) patients and gave the only positive result for malignancy in two (2.4%) cases. Brushing, needle aspiration and imprint cytology are taken from the exact site of a suspected tumour, giving them an advantage over bronchial washings, a procedure in which collected secretions can emerge from different sides of the bronchial tree or even be contaminated with oropharynx-aspirated secretions. Cytological examination of bronchial biopsy rinse fluid is also precise regarding the site.

Based on these findings of increased diagnostic yield for central malignant tumours, it is suggested that this inexpensive and nontime-consuming rinse technique be applied routinely during bronchoscopy. It may be a good alternative to bronchial brushing in the diagnosis of central lesions.

Acknowledgements: The authors wish to thank M.E. Kerans for kindly reviewing the English style of this manuscript and D. Ruiz for daily work in the bronchoscopy unit.

References

1. Govert JA, Kopita JM, Matchar D, Kussin PS, Samuelson WM. Cost-effectiveness of collecting routine cytologic specimens during fiberoptic bronchoscopy for endoscopically visible lung tumours. *Chest* 1996; 109: 451–456.
2. Solomon DA, Solliday NH, Gracey DR. Cytology in fiberoptic bronchoscopy. Comparison of bronchial brushing, washing and post-bronchoscopy sputum. *Chest* 1974; 65: 616–619.
3. Saltzstein SL, Harell JH, Cameron T. Brushings, washings, or biopsy? Obtaining maximum value from flexible fiberoptic bronchoscopy in the diagnosis of cancer. *Chest* 1977; 71: 630–632.
4. Zavala DC. Diagnostic fiberoptic bronchoscopy: techniques and results of biopsy in 600 patients. *Chest* 1975; 68: 12–19.
5. Mak VHF, Johnston IDA, Hetzel MR, Grubb Ch. Value of washings and brushings at fiberoptic bronchoscopy in the diagnosis of lung cancer. *Thorax* 1990; 45: 373–376.
6. Chaudhary BA, Yoneda K, Burki NK. Fiberoptic bronchoscopy. Comparison of procedures used in the diagnosis of lung cancer. *J Thorac Cardiovasc Surg* 1978; 76: 33–37.
7. Stringfield JT, Markowitz DJ, Bentz RR, Welch MH, Weg JG. The effect of tumor size and location on diagnosis by fiberoptic bronchoscopy. *Chest* 1977; 72: 474–476.
8. Lundgren R, Bergman F, Angström T. Comparison of transbronchial fine needle aspiration biopsy, aspiration of bronchial secretion, bronchial washing, brush biopsy and forceps biopsy in the diagnosis of lung cancer. *Eur J Respir Dis* 1983; 64: 378–385.
9. Kvale PA, Bode FR, Kini S. Diagnostic accuracy in lung cancer. Comparison of techniques used in association with

- flexible fiberoptic bronchoscopy. *Chest* 1976; 69: 752–757.
10. Popp W, Rauscher H, Ritschka L, Redtenbacher S, Zwick H, Dutz W. Diagnostic sensitivity of different techniques in the diagnosis of lung tumors with the flexible fiberoptic bronchoscope. *Cancer* 1991; 67: 72–75.
 11. Lyall JRW, Summers GD, O'Brien IM, Bateman NT, Pike CP, Braimbridge MV. Sequential brush biopsy and conventional biopsy: direct comparison of diagnostic sensitivity in lung malignancy. *Thorax* 1980; 35: 929–931.
 12. Popovich J, Kvale PA, Eichenhorn MS, Radke JR, Ohorodnik JM, Fine G. Diagnostic accuracy of multiple biopsies from flexible fiberoptic bronchoscopy. A comparison of central *versus* peripheral carcinoma. *Am Rev Respir Dis* 1982; 125: 521–523.
 13. Matsuda M, Horai T, Nakamura S, *et al.* Bronchial brushing and bronchial biopsy: comparison of diagnostic accuracy and cell typing reliability in lung cancer. *Thorax* 1986; 41: 475–478.
 14. Bilaceroglu S, Gunel O, Cagirci U, Perim K. Comparison of endobronchial needle aspiration with forceps and brush biopsies in the diagnosis of endobronchial lung cancer. *Monaldi Arch Chest Dis* 1997; 52: 13–17.
 15. Greene R, Szyfelbein WM, Isler RJ, Stark P, Jantsch H. Supplementary tissue-core histology from fine-needle transthoracic aspiration biopsy. *Am J Roentgenol* 1985; 144: 787–792.
 16. Schenk D, Chambers S, Derdak S, *et al.* Comparison of the Wang 19-gauge and 22-gauge needles in the mediastinal staging of lung cancer. *Am Rev Respir Dis* 1993; 147: 1241–1258.
 17. Steinmann G, Creul W. Effect of methods of sample taking on the cytologic diagnosis of lung tumors. *Acta Cytol* 1978; 22: 425–430.
 18. Smith MJ, Kini SR, Watson E. Fine needle aspiration and endoscopic brush cytology. Comparison of direct smears and rinsings. *Acta Cytol* 1980; 24: 456–459.
 19. Gellert AR, Mudd RM, Sinha G, Geddes DM. Fiberoptic bronchoscopy: effect of multiple bronchial biopsies on diagnostic yield in bronchial carcinoma. *Thorax* 1982; 37: 684–687.
 20. Minami H, Ando Y, Nomura F, Saki S, Shimokata K. Inter-bronchoscopist variability in the diagnosis of lung cancer by flexible bronchoscopy. *Chest* 1994; 105: 1658–1562.
 21. Kovitz K. Bronchoscopic brushing techniques. *J Bronchol* 1996; 3: 217–223.
 22. Piaton E, Grillet-Ravigneaux MH, Saugier B, Pellet H. Prospective study of combined use of bronchial aspirates and biopsy specimens in diagnosis and typing of centrally located tumors. *BMJ* 1995; 310: 624–627.