

Bronchopulmonary disease in Iranian housewives chronically exposed to indoor smoke

K. Amoli

Bronchopulmonary disease in Iranian housewives chronically exposed to indoor smoke. K. Amoli. ©ERS Journals Ltd 1998.

ABSTRACT: Tobacco smoking is recognized as the main cause of chronic bronchitis followed by occupational exposure to dust, fumes and gases. Indoor inhalation of smoke is being investigated increasingly but mainly the acute morbidity has been described while the late features and complications which may lead to respiratory disability are less well known.

Among the 388 female patients who were referred to the main Bronchoscopy Unit of Tehran University of Medical Sciences between 1986 and 1995, 10 nonsmoking elderly housewives were found with chronic bronchopulmonary lesions characterized by widespread mucosal swelling and anthracotic plaques of the airways. Enquiry into their past history revealed massive exposure to smoke over many years whilst baking household rustic bread inside dwellings. No other source of air pollution was detected. The main clinicopathological features were respiratory disability due to chronic bronchitis with intracellular as well as extracellular black particles.

As similar cases may present to medical practitioners even in affluent societies as a result of increasing amounts of immigrants from developing countries, recognition of these patients is important to avoid irrelevant diagnoses and unnecessary interventions.

Eur Respir J 1998; 11: 659–663.

Dept of Medicine, Tehran University of Medical Sciences, Tehran, Iran.

Correspondence: K. Amoli
448 Asadabadi Avenue
Tehran 14368
Iran
Fax: c/o 98 21 8075227

Keywords: Anthracosis
anthracotic chronic bronchitis
chronic bronchitis
chronic obstructive pulmonary disease
indoor air pollution

Received: April 15 1997

Accepted after revision December 12 1997

Chronic obstructive pulmonary disease (COPD) is a common disorder all over the world. Tobacco smoking has been recognized as the main exogenous factor in its aetiology, followed by certain occupational exposures and urban air pollution. However, in our experience clinically important COPD may also be found in nonsmoking patients without significant occupational histories and who come from apparently unpolluted areas. Such observations have been made in various areas of the developing world, and indoor air pollution resulting from the burning of biomass or wood smoke during cooking and baking has been proposed as a possible cause of such respiratory disease [1–12]. Most of these studies, however, are based on case reports [1, 2] or limited clinical data [3, 4], or are epidemiological surveys [5–12]. With the exception of one case [2], bronchoscopic examination and histological changes of the airways have not been reported. In this study, well-documented clinicopathological observations are presented from a series of 10 elderly Iranian female patients who were referred to the main Bronchoscopy Unit of Tehran University of Medical Sciences because of diagnostic problems regarding their advanced bronchopulmonary disorders. These patients had no history of asthma, had never smoked cigarettes, had never worked outside their homes, and had originally come from nonindustrialized villages. Upon further questioning it appeared that all of them had been exposed to indoor smoke from wood or biomass for many years, a fact they did not volunteer because they did not think this to be of any relevance to their present complaints.

Patient selection and methods

From April 1986 to March 1995, at the main Bronchoscopy Unit of the Tehran University of Medical Sciences (a nationwide referral centre) 891 fiberoptic bronchoscopies were carried out by the author (503 males, 388 females). In an effort to study the role of indoor air pollution as a possible cause of chronic bronchopneumopathies, patients with no other apparent cause of COPD and with no specific pulmonary disease (*i.e.*, tuberculosis, postpneumonic bronchiectasis *etc.*) were considered. A total of 10 cases were found fulfilling the following criteria:

- 1) All were elderly or middle-aged females. Males with similar conditions were excluded because they often had occupations exposing them to air pollution.
- 2) All came originally from the highland rural areas of the country with cold winters, although five had later become town-dwellers.
- 3) None were, or had been, cigarette smokers.
- 4) During their youth all had had an active life but, towards middle-age, had gradually begun to suffer from respiratory symptoms ultimately leading to disability.
- 5) Bronchoscopy revealed widespread chronic inflammatory changes and characteristically extensive bronchial anthracotic areas.
- 6) Microscopy of the bronchial samples showed intra-epithelial and subepithelial anthracosis as well as free black particles.
- 7) The course of the ailment was chronic and, if acute episodes were relieved, patients could survive having been

cared for by their relatives. Many more patients showed similar characteristics but were not included in this report due to lack of data, possible confounding parenchymal pathologies and single referrals.

On presentation the mean age of patients was 62.5 (range 46–72) yrs. All were married and multiparous (up to 16 pregnancies). Patients gave no clues as to the cause of their disorders but further questioning relating to their past history revealed that all had been subjected to heavy smoke inhalation while cooking homemade bread in ovens. Biomass or wood was used and, during the freezing winters, the work was conducted inside small enclosures with almost no ventilation. Filled with heavy smoke, the area would be blotted with soot (fig. 1). The duration and frequency of the baking differed according to the size of the household, ranging from daily to once a week, each procedure lasting 2–3 h. All the patients had already stopped baking and there was a gap of at least 4 yrs between the last exposure and the time they were referred. There was no other source of air pollution that could be identified in the aetiology.

Clinical examination, routine blood chemistry, and haematology were carried out for all the patients. In all cases chest radiographs, and in two cases computed tomography (CT) scans, were available. Pulmonary function tests were limited to forced vital capacity (FVC) and forced expiratory volume in one second (FEV₁) using the Farafan computerized spirometer (SP 722; Farafan Co., Tehran, Iran). The figures were compared with the findings of normal values from an Iranian study [13–14], although the latter



Fig. 1. – A rustic housewife cooking bread for the family is exposed to smoke and fire from a ground oven. Extensive soot-covering of the walls can be seen.

measurements had been restricted to urban females. No specific equivalents for the rural inhabitants are available.

Fibreoptic bronchoscopy was indicated in all cases because of diagnostic problems. Olympus (Olympus Optical Co., Tokyo, Japan) or Pentax (Asahi Optical Co., Tokyo, Japan) equipment with videoscopic facilities (Pentax) were used that enlarged and recorded the views for more detailed observation. Biopsies were tried along with bronchial washings in all patients for cytobacteriology.

Results

All patients were referred with symptoms of COPD (table 1). The main complaints were dyspnoea on exertion (in nine patients) and cough (in seven patients). Sputum production was not excessive although it was present during all bronchoscopies. Some patients, too weak to cough up these secretions, swallowed them instead. Only one patient was found to suffer from haemoptysis. None had or mentioned attacks of bronchospasm. While resting, the patients looked to be fairly comfortable but exercise tolerance was severely limited and they could barely manage to look after themselves. None lived in geriatric homes but were cared for by their offspring. Rhonchi and inspiratory crackles were heard in six and four cases, respectively. Clubbing was noticed in only one patient. Seven cases were hypertensive, three suffered from arthrosis and one had diabetes mellitus.

Chest radiographs and CT scans revealed a variety of changes: linear shadows along the bronchovascular bundles were seen in all cases in proximal areas of the middle and lower zones and adjacent to the lateral parts of the cardiac outline (fig. 2). Patchy or confluent opacities were also seen that intensified during exacerbations. Nodular patterns were noticed in two cases, mainly in the lower zones. Small translucent round areas were present within irregular opacities suggesting medium bronchi with thickened walls. CT scans in two patients showed narrowing of the large airways with wall thickening. Airspace shadows with air bronchograms, occasional ground glass opacities and destructive lesions were found. Hilar or mediastinal lymph gland enlargement was not outstanding. Criteria for emphysema were lacking.

FVC and FEV₁/FVC measurements

Pulmonary function tests in seven patients who managed to carry out the procedures showed a decreased FVC

Table 1. – The clinical and functional course in 10 nonsmoking Iranian housewives with anthracotic bronchial plaques

Patient No.	Age yrs	Symptoms and signs	VC % pred	FEV ₁ /FVC	Follow-up* yrs
1	55	Cough, dyspnoea, wheeze, rhonchi	40	52	8 (alive)
2	46	Cough, dyspnoea, wheeze, insomnia, rhonchi, clubbing	36	66	8 (alive)
3	60	Cough, fever, wheeze, chest pain, rhonchi	46	66	2 (unknown)
4	60	Cough, dyspnoea, sputum, rhonchi, crackles	62	49	0.5 (unknown)
5	72	Cough, dyspnoea, fever, wheeze, weight loss, rhonchi	-	-	7 (died)
6	63	Dyspnoea, fever, wheeze, palpitation, crackles	-	-	6.5 (alive)
7	67	Cough, dyspnoea, wheeze, rhonchi	-	-	5.5 (alive)
8	69	Dyspnoea, fever, epigastric pain	69	64	4 (alive)
9	65	Dyspnoea, fever, rigours, crackles	-	-	1 (died)
10	68	Cough, dyspnoea, wheeze, sputum, crackles	67	72	3 (died)

VC: vital capacity; % pred: percentage of predicted value; FEV₁: forced expiratory volume in one second; FVC: forced vital capacity. *: duration of observation with present condition in parenthesis.

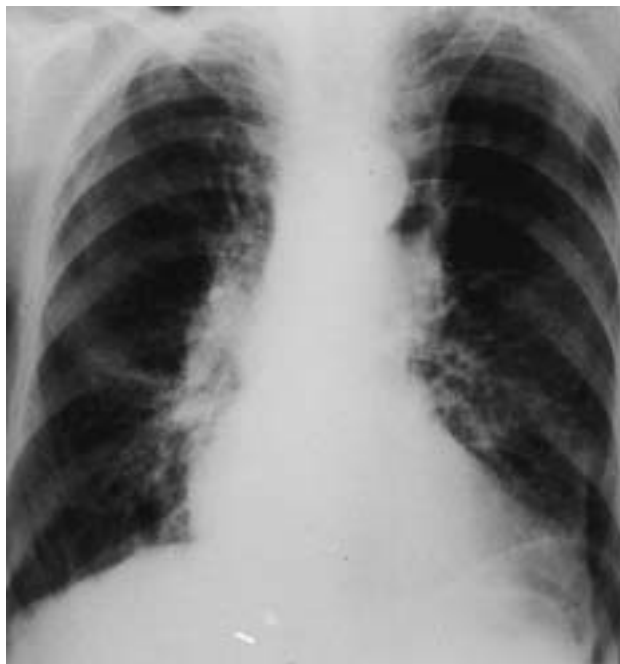

Fig. 2. — Chest radiograph of patient No. 7 with hilar shadows and proximal streaky opacities.

from 36–69% of the predicted value (table 1) and the ratio FEV₁/FVC ranged 42–72%. Bronchodilators had only minimal effect and did not reveal a background of asthma. Four patients could not produce satisfactory spirometry. In four patients follow-up tests showed progressive accelerated deterioration.

Bronchology

Fibreoptic bronchoscopy in all patients showed generalized inflammation of the visible airways with a moderate quantity of mucopurulent secretions coming from both sides. The trachea and the large bronchi were narrowed due to bulging of the wrinkled surfaces. In some patients the tip of the bronchoscope could not pass even through the main bronchi. The most characteristic finding, however, was the presence of multiple patches of black material in the main (fig. 3), lobar and segmental bronchi (fig. 4). These anthracotic plaques were resistant to biopsy procedures, leaving only a minor superficial haemorrhage. No massive bleeding occurred during the bronchoscopies.

Bacteriology

Sputum and bronchial washings did not reveal acid fast bacilli on direct examination and on cultures. Various bacteria detected included *Pseudomonas* spp; *Klebsiella*; *Escherichia coli*; *Hafnia* sp; *Proteus mirabilis*; and *Staphylococci*; but the pathogenicity of any of these organisms could not be confirmed.

Pathology

Biopsies were tried in all patients and revealed epithelial metaplasia containing black deposits and, in some cases, squamous changes. The surface epithelium, how-

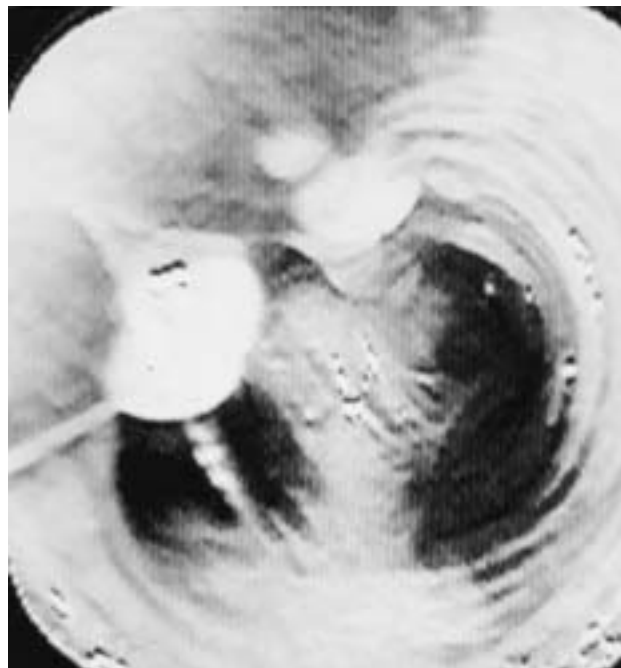

Fig. 3. — Endoscopic view of the main bronchi in patient No. 7. Anthracotic plaques at the bifurcation of trachea with mucus droplets on the surface epithelium.



Fig. 4. — Further endoscopic view of the segmental bronchi in patient No. 7 with anthracotic depositions at the entrance of divisions in the right lower lobe.

ever, was often intact (table 2, fig. 5). Subepithelial infiltration of nonspecific inflammatory cells was prominent. Anthracotic pigments were observed in the hyalinized connective tissue stromas. In one case relatively concentrated collections of lymphoid cells with irregular nuclei were recognized. Polymorphonuclear leucocytes were seen only occasionally. No evidence of granuloma formation or malignancy was found. The sample in one case was unremarkable for histology but abundant free black particles were outstanding in the bronchial washings.

Patients' management and course

Acute episodes, the main cause of the presentations, were treated empirically with antibiotics (mainly ampicillin

Table 2. – Pathological findings from bronchoscopies in the 10 nonsmoking Iranian housewives studied

Patient No.	Pathology
1	Intact epithelium, subepithelial nonspecific inflammatory infiltration and fibrosis with anthracotic pigments
2	Bronchial mucosa and lung tissue with anthracotic pigments
3	Epithelial and submucosal tissue with mononuclear cells
4	Epithelial mucosa with abundant macrophages containing anthracotic pigments
5	Intact epithelium with anthracotic pigments, infiltration of lymphoid cells with irregular nuclei and occasional macrophages in subepithelial stroma
6	Epithelial mucosa with sparse mononuclear infiltration, some macrophages containing dark grey-black pigments
7	Bronchial mucosa with clusters of goblet cells and abundant pigments in macrophages, also extracellular pigments in the interstitium; some subepithelial fibrosis; patchy stromal mononuclear infiltration; free black particles in bronchial washings
8	Sample not remarkable for histology; abundant free black particles in bronchial washings
9	Bronchial mucosa with abundant anthracotic pigments; extracellular pigments in subepithelial stroma; free black particles in bronchial washings
10	Fibroblastic active proliferation of the interstitium with anthracosis and silicon-like deposits




Fig. 5. – Bronchial biopsy from patient No. 10 showing intact surface epithelium, subepithelial anthracotic pigments and inflammatory cells. Haematoxylin and eosin stain. Internal scale bar=25 μ m.

or cotrimoxazole). Management also included bronchodilators (with little benefit), physiotherapy and postural drainage. Short courses of corticosteroids were tried with no remarkable benefit. Two patients had to be admitted for 1–2 weeks; otherwise they were treated as out-patients. The mean period of follow-up was 4.6 yrs. Five patients were still alive while preparing this report (table 1); three patients died with respiratory failure. Communication with two cases was unsuccessful.

Discussion

Recognition of the aetiology of generalized bronchopulmonary lesions in nonsmokers with an unknown history of previous exposure is a challenge to any physician. The patients presented here did not volunteer information as to the cause of their ailments. Retrospectively, it was discovered that they had been exposed to indoor smoke for many years. Thus the course and the pathogenesis could not be followed from the onset in any of these cases. However, it was possible to speculate on the sequence of events. In Iranian villages baking bread is one of the duties of the housewife, a task carried out in ovens using biomass or wood. These patients all came from the highland regions where bread is the main nutriment. There were no cases from the lowland Caspian Sea counties where rice is pre-

ferred. In the highlands, with long freezing winters, baking is arranged within small enclosures with almost no ventilation so that the walls can be observed to be covered with soot (fig. 1). The patients stated that they had been exposed to fire and heavy smoke regularly. No masks or any other preventive measures against smoke inhalation had been used. The putative relationship between the anthracotic pathology of the patients presented here and the past exposures is evidenced by the bronchoscopic findings, the presence of free soot particles in bronchial washings and the intracellular anthracotic deposits in bronchial walls. No other source of air pollution could be detected.

Remodelling of the airways as observed during the bronchoscopies, *i.e.*, the narrowed and tortuous bronchi with metaplasia, presumably disturbs the local defence mechanisms and the mucous secretions are colonized by opportunist bacteria. Superimposed infections interrupt the chronic course of the lesions. Treatment of the acute episodes improves the additional symptoms but the underlying process continues and deteriorates over time.

The structural changes of the airways, including anthracosis, is not exclusive to rural female bakers. Similar patterns may be found in a variety of occupations including coal-miners [15] and in any environment where there is prolonged exposure to smoke. These are, however, related to occupational air pollution and were not included in the present study. The diagnostic problem in the Iranian housewife model is that because of the long interval between exposure and the onset of symptoms the possible causation is not immediately suspected. On presentation, patients usually describe their recent symptoms, with no detailing of past circumstances and events. Even when this information is recalled, it is often considered irrelevant. Moreover, the rustic origin of the patients may remain unknown due to immigration to urban areas, as has happened in half of the cases presented in the present study.

It is difficult to categorize these patients within the classic pulmonary pathologies because both bronchial and extra-bronchial tissues are affected. Lesions of the classic chronic bronchitis are rather restricted to the airways although the disease may be complicated by parenchymal extension. On the other hand, respiratory disorders acquired by inhalation of dusts (the pneumoconioses) are mainly defined by parenchymal and small airways lesions rather than those of the larger bronchi. More clinicopathological studies are

required to elucidate the nosology of these extensive bronchopulmonary changes in relation to indoor-smoke air pollution. Prospective examination and follow-ups of the population who are still living under similar conditions should be contemplated. Prevalence of the condition requires investigation.

Such patients are not only encountered in Iran. Similar conditions prevail in neighbouring countries [3] and in the developing world, including South America [2, 13]. It has been estimated that 300–400 million people worldwide are now living under comparable circumstances [16]. Furthermore, dynamic social changes transform villages into urban centres and the new generations emigrate to the cities. The population of Iran, with an established area of 1.64 million km², has rapidly soared from 19 million in 1946, when some of the patients presented here were young and active, to 60 million in 1996. Meanwhile the proportion of the rural inhabitants decreased from 61 to 38% respectively. This represents the trend in population movement towards the more centralized areas, as has happened in half of the patients reported here. Moreover, hundreds of thousands of Iranians have established themselves abroad, mainly in Europe and North America, many of them taking the elderly parent with them. There are other countries that share the same phenomenon. On presentation to the local physician or the specialized chest services, usually when an acute episode occurs, a variety of irrelevant differential diagnoses may confound the management of these patients. Unnecessary procedures, and even thoracotomies, may be contemplated.

Apart from the therapeutic aspects, investigation of the mechanisms of disease in these patients, including the pathology and immunology, is required. As the incidence of new cases continues to remain at a high level in the less developed parts of the world, preventive measures directed to reform the traditional methods of cooking and baking should be taken seriously. It is true that public bakeries are replacing household practises but the old habit still prevails and the patients already affected need medical attention.

References

1. Dhar SN, Pathania AGS. Bronchitis due to biomass fuel burning in North India: "Gujjar Lung", an extreme effect. *Semin Respir Med* 1991; 12: 69–73.
2. Sandoval J, Salas J, Martinez-Guerra ML, *et al.* Pulmonary arterial hypertension and cor pulmonale associated with chronic domestic woodsmoke inhalation. *Chest* 1993; 103: 12–20.
3. Dossig MJ, Khan J, Al-Rabiah F. Risk factors for chronic obstructive lung disease in Saudi Arabia. *Respir Med* 1994; 88: 519–522.
4. Ellegard A. Cooking fuel smoke and respiratory symptoms among women in low-income areas in Maputo. *Environ Health Perspect* 1996; 104: 980–985.
5. Pandey MR. Domestic smoke pollution and chronic bronchitis in rural community of the Hill Region of Nepal. *Thorax* 1984; 39: 337–339.
6. Chen BH, Hong CJ, Pandey MR, Smith KR. Indoor air pollution in developing countries. *World Health Statist Quart* 1990; 43: 127–138.
7. Behera D, Jindal SK, Mahorta HS. Ventilatory function of nonsmoking rural Indian women using different cooking fuels. *Respiration* 1994; 61: 89–92.
8. Zu X, Wang L. Association of indoor particulate levels with chronic respiratory illness. *Am Rev Respir Dis* 1993; 148: 1516–1522.
9. Qureshi KA. Domestic smoke pollution and prevalence of chronic bronchitis/asthma in a rural area of Kashmir. *Indian J Chest Dis Allied Sci* 1994; 36: 61–72.
10. Zhou X, Hih Y, He X. A study on the relationship between indoor air pollution and chronic obstructive pulmonary disease in Zuanwer City. *Chung-hua-Yu-Fang-I-Hsueh-Tsa-Chin* (abstract) 1995; 29: 38–40.
11. Dutt D, Srinivasa DK, Rotti SB, Sahai A, Konar D. Effect of indoor air pollution on the respiratory system of women using different fuels for cooking in an urban slum of Pondicherry. *Nat Med J India* 1996; 9: 113–117.
12. Dennis RJ, Maldonado D, Norman S, Baena E, Martinez G. Woodsmoke exposure and risk for obstructive airways disease among women. *Chest* 1996; 109: 115–119.
13. Masjedi MR, Faqihi AH, Johnson DC. Measurement of standard spirometric figures in healthy non-smokers. *Daru-va-Darman* 1988; 5–15 (in Persian).
14. Masjedi MR, Kazemi H, Johnson DC. Effects of passive smoking on pulmonary function of adults. *Thorax* 1990; 45: 27–31.
15. Christiani DC, Mark EJ. Case Records. *N Engl J Med* 1988; 319: 1401–1410.
16. Dekoning HW, Smith HW, Last JM. Biomass fuel combustion and health. *Bull World Health Organ* 1985; 63: 11–26.