

**SERIES 'THE PLEURA'**

**Edited by H. Hamm and R.W. Light**

**Number 12 in this Series**

## Thoracoscopy - state of the art

R. Loddenkemper

*Thoracoscopy - state of the art. R. Loddenkemper. ©ERS Journals Ltd 1998.*

**ABSTRACT:** "Medical" thoracoscopy as compared with "surgical" thoracoscopy (which is more precisely known as video-assisted thoracic surgery (VATS)) has the advantage that it can be performed under local anaesthesia or conscious sedation, in an endoscopy suite, using nondisposable rigid instruments. Thus, it is considerably less invasive and less expensive.

The main diagnostic and therapeutic indications for medical thoracoscopy are pleural effusions and pneumothorax. Due to its high diagnostic accuracy, approaching almost 100% in malignant and tuberculous pleural effusions, it should be used when pleural fluid analysis and needle biopsy are nondiagnostic. In addition, medical thoracoscopy provides staging for lung cancer and diffuse malignant mesothelioma. Talc poudrage, as the best conservative method for pleurodesis in 1998, can also be performed with medical thoracoscopy. It can also be effectively used in the early management of empyema. In spontaneous pneumothorax it allows staging, thereby facilitating treatment decisions, and in addition coagulation of eventual blebs and talc poudrage for efficient pleurodesis.

Medical thoracoscopy is a safe procedure which is even easier to learn than flexible bronchoscopy. Due to its high diagnostic and therapeutic efficiency, it should be applied increasingly in the management of the above-mentioned pleuropulmonary diseases.

*Eur Respir J 1998; 11: 213–221.*

Thoracoscopy was introduced by JACOBÆUS [1], an internist in Stockholm in 1910, primarily as a diagnostic procedure in two cases of exudative (tuberculous) pleuritis. In his excellent overview "Thoracoscopy and its practical importance" JACOBÆUS [1] published his accumulated experience of thoracoscopy in all the indications which are still in 1998 the domain of pneumologists [2]. With malignant effusion, he was frequently able to differentiate between primary and secondary tumours of the chest wall, pleura, lung and mediastinum. He divided tuberculous pleurisy into different stages, studied rheumatic and non-specific parapneumonic effusions and he performed thoracoscopy in more than 100 empyemas, many of which were nontuberculous. He also appreciated that, frequently, one could not visualize the defect in idiopathic, spontaneous pneumothorax. However, during the ensuing 40 yrs, thoracoscopy was applied on a worldwide scale almost exclusively for the lysis of pleural adhesions by means of thoracocautery ("Jacobæus' Operation") to facilitate pneumothorax treatment of tuberculosis (TB) [3].

With the advent of antibiotic therapy for TB, a generation of physicians, already familiar with the therapeutic application of thoracoscopy, began, mainly in Europe, to use this technique on a wider basis for evaluating many pleuropulmonary diseases [4, 5]. Detailed descriptions of pleural disease, with emphasis on tuberculous and malignant effusions, appeared in the literature and the diagnostic potential was again verified. Concurrently, many American surgeons preferred thoracotomy and open biopsy for evaluation of these diseases.

Due to technical improvements and a trend towards less invasive procedures, thoracoscopy was rediscovered by thoracic surgeons at the beginning of this decade, and termed "surgical" thoracoscopy, which is more precisely known as video-assisted thoracic surgery (VATS) [6–8]. Interestingly, this revival has also supported the introduction of "medical" thoracoscopy into the scope of respiratory physicians, in particular in the USA where, according to a national survey in 1994, already more than 5% of all pulmonologists were applying medical thoracoscopy [9]. In

Lungenklinik Heckeshorn, Zum Heckeshorn 33, D-14109 Berlin, Germany.

Correspondence: R. Loddenkemper  
Lungenklinik Heckeshorn  
Zum Heckeshorn 33  
D-14109 Berlin  
Germany  
Fax: 00 49 3080022286

Keywords: Empyema  
malignant pleural effusions  
mesothelioma  
pleural effusions  
pneumothorax  
thoracoscopy

Received: August 15 1997

Accepted after revision October 8 1997

**Previous articles in this series:** No. 1: G. Miserocchi. Physiology and pathophysiology of pleural fluid turnover. *Eur Respir J* 1997; 10: 219–225. No. 2: R.W. Light. Diagnostic principles in pleural disease. *Eur Respir J* 1997; 10: 476–481. No. 3: G.T. Kinasevitz. Transudative effusions. *Eur Respir J* 1997; 10: 714–718. No. 4: J. Ferrer. Pleural tuberculosis. *Eur Respir J* 1997; 10: 942–947. No. 5: H. Hamm, R.W. Light. Parapneumonic effusion and empyema. *Eur Respir J* 1997; 10: 1150–1156. No. 6: G. Hillerdal. Chylothorax and pseudochylothorax. *Eur Respir J* 1997; 10: 1157–1162. No. 7: F.M.N.H. Schramel, P.E. Postmus, R.G.J.R.A. Vanderschueren. Current aspects of spontaneous pneumothorax. *Eur Respir J* 1997; 10: 1372–1379. No. 8: F. Rodriguez-Panadero, V.B. Antony. Pleurodesis: state of the art. *Eur Respir J* 1997; 10: 1648–1654. No. 9: S.A. Sahn. Pleural diseases related to metastatic malignancies. *Eur Respir J* 1997; 10: 1907–1913. No. 10: C. Kroegel, V.B. Antony. Immunology of pleural inflammation: potential implications for pathogenesis, diagnosis and therapy. *Eur Respir J* 1997; 10: 2411–2418. No. 11: R.W. Light, H. Hamm. Pleural disease and acquired immune deficiency syndrome. *Eur Respir J* 1997; 10: 2638–2643.

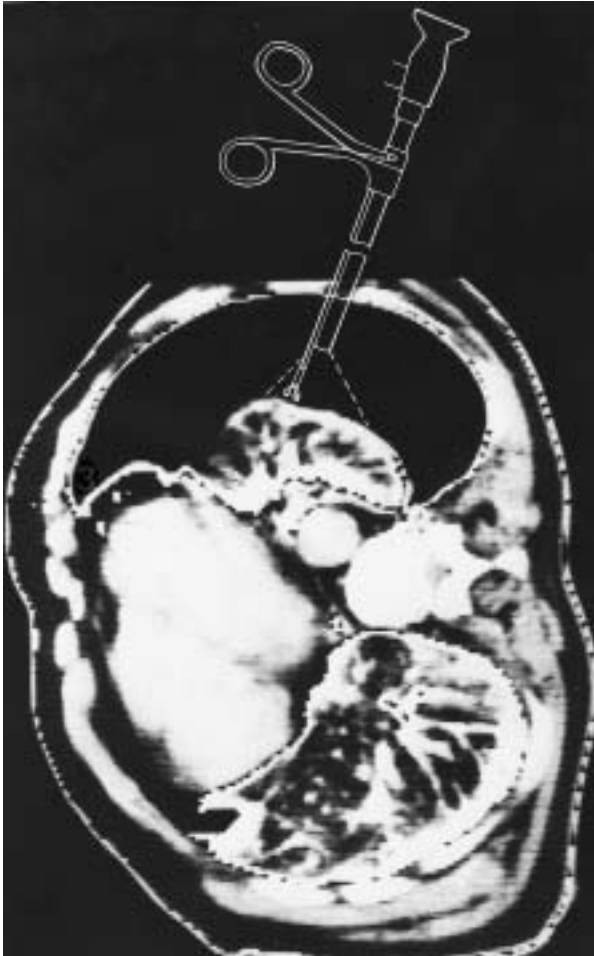


Fig. 1. – Computed tomography simulation of medical thoracoscopy (right thoracic cavity in left lateral position). Visualization of chest wall pleura, diaphragm, lung, anterior and partially of posterior mediastinum possible.

Europe, thoracoscopy is intrinsic in the training programme of pneumology [10].

The purpose of this article is to describe the present role of "medical" thoracoscopy in the diagnosis and treatment of pleural effusions, including empyema, and of pneumothorax.

### Techniques

Medical thoracoscopy is an invasive technique which should be used only when other more simple methods fail. As with all technical procedures there is certainly a learning curve before full competence is achieved [11, 12]. Therefore, appropriate training is mandatory [13]. Actually, the technique is very similar to chest-tube insertion by means of a trocar, the difference being that, in addition, the pleural cavity can be visualized and biopsies can be taken from all areas of the pleural cavity including the chest wall, diaphragm, mediastinum and lung (fig. 1). This is also the reason that the term thoracoscopy should be preferred to "pleuroscopy", which is occasionally used instead [14].

An absolute prerequisite for thoracoscopy is the presence of an adequate pleural space which should be at least 6–10 cm in diameter. If not present, a pneumothorax is induced, immediately or the day before thoracoscopy under fluoroscopic (or radiographic/sonographic) control. If extensive pleuropulmonary adhesions are present, "extended" thoracoscopy without creating a pneumothorax can be carried out [15], but this requires special skills and should not be undertaken without special training.

The main advantage of medical thoracoscopy compared to VATS is that the examination can be performed under local anaesthesia or conscious sedation (neurolept analgesia) after adequate premedication, and thus without the support of an anaesthetist. Furthermore, medical thoracoscopy is also less expensive because it may be safely performed with nondisposable instruments and in an appropriate endoscopy room.

The different techniques of diagnostic and therapeutic thoracoscopy, as performed by the pneumologist, are described in detail elsewhere [4, 5, 16, 17]. Essentially, one method prefers a single entry with a 9 mm thoracoscope, with a working channel for accessory instruments and optical biopsy forceps (fig. 2), and local anaesthesia [4, 12, 17–20]. The other favours two entries, one with a 7 mm trocar for the examination telescope and the other with a 5 mm trocar for accessory instruments including the biopsy forceps and neurolept (or general) anaesthesia [5, 21]. However, the experienced thoracoscopist will certainly use a combination of these techniques, depending upon the individual needs and the facilities available.

For cauterization of adhesions and blebs or in cases of bleeding after biopsy electrocoagulation (or laser coagulation) should be available [4, 5]. For pleurodesis of effusions 8–10 mL of sterile, dry asbestos-free talc is insufflated through a rigid or flexible suction catheter with a pneumatic atomizer [5, 19]. Additional pain medication should be given as necessary. In pneumothorax patients 2–3 mL of talc is sufficient [5, 19, 22]. Immediate suction through the chest-tube is always applied following the procedure.

Flexible bronchoscopes have also been used, which in comparison with rigid thoroscopes have several disadvantages, in particular the less adequate orientation within the pleural cavity and the smaller biopsies [18, 23]. Most authors use flexible instruments only because rigid instruments are not available or appear dangerous: some authors believe that local anaesthesia is not adequate [24]. Currently under development are special semi-flexible instruments with a rigid shaft and a flexible tip. Video equipment is not mandatory but allows better teaching and documentation.

### Prevention of complications

Medical thoracoscopy is a safe examination if the contra-indications are observed and if certain standard criteria are fulfilled [4, 5, 21, 25]. An obliterated pleural space is an absolute contra-indication. Relative contra-indications include bleeding disorders, hypoxaemia and an unstable cardiovascular status and persistent uncontrollable cough.

During the procedure, cardiorespiratory functions should be monitored by electrocardiography (ECG), measurement of blood pressure and continuous oximetry. Complications such as benign cardiac arrhythmias, low-grade




Fig. 2. – Instruments for medical thoracoscopy: a) trocar and cannula with valve; b) single incision thoracoscope (9 mm diameter); c) biopsy forceps with straight optics; and d) magnification of optics and forceps in the thoracoscope shaft ready for biopsy.

hypertension or hypoxaemia can be prevented almost completely by administration of oxygen [26]. The most serious, but fortunately least frequent, complication is severe haemorrhage due to blood vessel injury during the procedure. However, this, and also pulmonary perforations, can be avoided by using safe points of entry and a cautious biopsy technique. In the case of smaller persistent bleedings, electrocoagulation may become necessary. In our experience of more than 6,000 thorascopies, there was never the need for a surgical intervention to stop bleeding caused by thoracoscopy. The most serious complication of pneumothorax induction is air or gas embolism, which occurs very rarely (<0.1%), as long as necessary precautionary measures are observed [4].

Reported mortality rates (<0.01%) are very low [5, 25]. Even several litres of fluid can be completely removed during thoracoscopy with little risk of pulmonary oedema, because immediate equilibration of pressures is provided by direct entrance of air through the cannula into the pleural space [4]. If the re-expansion potential of the lung appears to be diminished, at most, only low pressure suction should be applied through the intrapleural drainage tube which is always put into place at the end of thoracoscopy. Following lung biopsy, a bronchopleural fistula may result. This may require longer than the usual suction periods of 3–5 days, particularly in cases with stiff lungs [4, 5]. After talc poudrage fever may occur. Local site infection is however uncommon and empyema has been reported only very rarely [22].

In cases of mesothelioma, 10–12 days after thoracoscopy, radiotherapy may be carried out in order to prevent

the late complications of tumours growing at the sites of entry [27].

### Indications

Medical thoracoscopy is today primarily a diagnostic procedure, but it can also be applied for therapeutic purposes [28, 29]. Pleural effusions are by far the leading indication for medical thoracoscopy both for diagnosis, mainly in exudates of unknown aetiology and for staging in diffuse malignant mesothelioma or lung cancer, and for treatment by talc pleurodesis in malignant or other recurrent effusions, or in cases of empyema. Spontaneous pneumothorax for staging and, in stage I and II, for local treatment is also an excellent indication. For those who are familiar with the technique other (mainly diagnostic) indications are biopsies from the diaphragm, the lung, the mediastinum and the pericardium [28]. In addition, medical thoracoscopy offers a remarkable tool for research as a "gold standard" in the study of pleural effusions.

At our institution, Lungenklinik Heckeshorn in Berlin, there has during the last three decades been a definite trend, both in absolute and relative numbers, towards an increase in the application of medical thorascopies in pleural effusions, which comprises 90% of the annual 170–200 medical thorascopies performed. There has also been a corresponding decline in the other indications [4, 28] (table 1). This decrease in all indications other than pleural effusions is explained by several factors. The reason that the absolute number of pleural effusions has risen so much is due to the fact that more and more pleural effusions are transferred to our hospital for diagnostic and

Table 1. – Indications for thoracoscopy: comparison between 1971–1979, 1980–1988 and 1995–1996 in Lungenklinik Heckeshorn, Berlin, Germany

Indications	1971–1979	1980–1988	1995–1996
	(n=1652) %	(n=1519) %	(n=369) %
Pleural effusion	48	74	90
Malignant	39	48	68
Tuberculous	24	14	8
Others	37	38	24
Diffuse lung disease	22	8	1
Localized lung lesion	17	6	3
Chest wall lesion	6	5	2.5
Mediastinal tumour	5	2	0
Pneumothorax	1	4	3
Postoperative cavity	1	1	0.5

n: number of patients.

therapeutic purposes. On the other hand, the indications for diagnosis in localized lung and chest wall lesions have diminished considerably since imaging techniques such as computed tomography (CT) or magnetic resonance imaging (MRT), which are available routinely today, deliver very often the diagnosis or allow the differentiation between malignant and benign disease. In addition, VATS or "surgical" thoracoscopy can be preferably performed in these indications for diagnosis and for simultaneous removal of the lesion. Furthermore, our indications for lung biopsies in diffuse lung diseases have decreased, too. This is due to the improved diagnostic results of bronchoscopy using transbronchial lung biopsies and bronchoalveolar lavage as well as to the development of high-resolution CT (HRCT) which improves the definition of structural changes, *e.g.* the degree of fibrosis, and sometimes even gives the diagnosis, *e.g.* in histiocytosis X. The low number of pneumothorax patients in our series is explained by the historic policy of our institution that the Department of Thoracic Surgery takes care of almost all patients who are admitted with spontaneous pneumothorax. However, our surgeons always include the routine use of an optic for the inspection of the pleural cavity at the time of chest-tube insertion through the cannula, in local anaesthesia, what actually means that they perform a "medical" thoracoscopy. The same is frequently true for cases of empyema which are traditionally treated almost exclusively by our surgeons [30].

### Pleural effusions

Even after extensive diagnostic work-up of the pleural fluid the aetiology of a number of pleural effusions remains undetermined [31, 32]. Blind needle biopsies may establish the diagnosis in some additional cases, particularly in tuberculous pleurisy [33–35]. In a series by BOUTIN *et al.* [11], of 1,000 consecutive patients with pleural effusions, 215 cases remained undiagnosed after repeated pleural fluid analyses and performance of pleural biopsies. This is in agreement with the results of several other authors who, without the use of thoracoscopy, report that at least 20–25% of pleural effusions remain undiagnosed [36–38], although this certainly depends upon patient populations.

If the facilities for medical thoracoscopy are available, medical thoracoscopy should be performed on these undiagnosed patients because of its high sensitivity in malignant and tuberculous pleural effusions [28]. In addition it allows fast and more definite biopsy diagnosis, including a higher yield in TB-cultures and the determination of hormone receptors in some malignancies. Furthermore staging in lung cancer and diffuse mesothelioma is possible. The exclusion of an underlying malignancy or TB is provided with high probability. Surgery, including surgical thoracoscopy, is not only much more invasive and expensive but does not produce better results than medical thoracoscopy and, therefore, should be reserved for very selected cases [39]. Repeated therapeutic thoracenteses may often create pleuropulmonary adhesions which make medical thoracoscopy much more difficult or even impossible [4]. The application of medical thoracoscopy today allows the simultaneous insufflation of talc powder which currently offers the best results in pleurodesis treatment. Further therapeutic advantages include complete fluid removal, and evaluation of the re-expansion potential of the lung. Fibrinous loculations in tuberculosis and empyema can be easily removed, thus creating a single pleural cavity which can be treated more efficiently.

Therefore, we prefer to perform a diagnostic medical thoracoscopy in almost all exudates in which the aetiology remains undetermined after pleural fluid analysis [28]. At present, at our institution, more than 68% of all thorascoped pleural effusions are of malignant and only 8% of tuberculous origin. In 24% of the cases medical thoracoscopy was performed mainly for differential diagnosis, in particular for exclusion of malignancy or TB. LIGHT [40] estimated for the USA, annual incidences of 750,000 non-cardiac and nonparapneumonic pleural effusions, thus by that rationale one would expect in our catchment area which comprises, mainly the western part of Berlin with approximately 2 million inhabitants, about 6,000 pleural effusions. Of these approximately 2,000 would be of malignant origin, of which less than 5–10% would undergo medical thoracoscopy.

### Malignant pleural effusions

As already mentioned, malignant pleural effusions in 1997 represent the leading diagnostic and therapeutic indication for medical thoracoscopy [28, 29]. In a prospective inpatient comparison, the diagnostic yield of the nonsurgical biopsy methods in malignant pleural effusions was studied simultaneously in 208 patients [41]. These included: 58 diffuse malignant mesotheliomas; 29 cancers of the lung; 116 metastatic pleural effusions with 28 breast cancers; 30 cancers of various other origins; 58 of undetermined origin; and five malignant lymphomas.

The overall diagnostic yield with cytological results from effusion was 62%, with needle biopsy (Trucut; Baxter Healthcare Corporation, Valencia, CA, USA) 44%, and with medical thoracoscopy 95%, the latter showing a significantly higher sensitivity ( $p < 0.001$ ) than needle biopsy with cytological results from effusions combined, which were positive in 74%. All methods taken together were diagnostic in 97% of cases of malignant pleural effusions (fig. 3). In six cases an underlying neoplasm was suspected at thoracoscopy but confirmed only by thoracotomy or

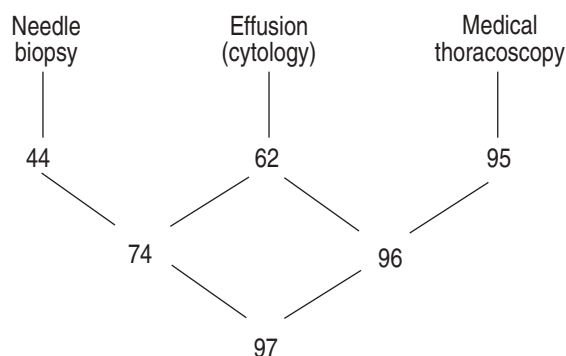


Fig. 3. – The different biopsy techniques used in the diagnosis of malignant pleural effusions and their sensitivity expressed in percentages (cytological and histological results combined). Prospective inpatient comparison (n=208). Taken from [28].

autopsy in three cases each. Similar results were reported by a number of other investigators [11, 18, 20, 42].

Reasons for false-negative thoracoscopy include insufficient and nonrepresentative biopsies, that depend largely on the experience of the thoracopist [11, 12], and the presence of adhesions which deny access to neoplastic tissue [5, 28]. In our experience, there is virtually no difference in the yield, using medical thoracoscopy for the different types of malignant effusions. The overall yield in 287 cases was for cytology 62% and for medical thoracoscopy 95%; the yield for cytology and in particular thoracoscopy did not vary much between lung carcinomas (67 *versus* 96%, n=67), extrathoracic primaries (62 *versus* 95.5%, n=154) or diffuse malignant mesotheliomas (58 *versus* 92%, n=66) (unpublished data).

Medical thoracoscopy is helpful in the staging of lung cancer, diffuse malignant mesothelioma and metastatic cancers. In lung cancer patients, thoracoscopy can determine whether the tumour has spread to the pleura, is secondary to venous or lymphatic obstruction or is parapneumonic [28]. As a result, it may be possible to avoid exploratory thoracotomy or determine operability. WEISSBERG *et al.* [43] performed thorascopies in 45 patients with lung cancer and pleural effusion. In 37, they found pleural invasion; three patients had mediastinal disease; the remaining five had no evident metastatic disease and, therefore, no contra-indication to resection. CANTO *et al.* [44] found similar results: eight of 44 patients (18%) had no thorascopic evidence of pleural involvement and six went to resection where no tumour was found.

In diffuse malignant mesothelioma, medical thoracoscopy provides an earlier diagnosis and a better histological classification due to larger and consequently more representative biopsies, as well as more precise staging [45–47]. This may have important therapeutic implications since much better responses to local immunotherapy or local chemotherapy in the early stages (I and II) have been observed [48–50]. Thoracoscopy is also helpful in the diagnosis of benign asbestos-related pleural effusion which, by definition, is a diagnosis of exclusion [51].

Fibrohyaline or calcified, thick and pearly white pleural plaques may be found indicating possible asbestos exposure. Thorascopic pulmonary biopsies and even biopsies from special lesions on the parietal pleura may demonstrate high concentrations of asbestos fibres providing further support to the diagnosis of asbestos disease [52].

In metastatic pleural effusions, biopsies of the visceral and diaphragmatic pleura are only possible under direct vision. Since the chest wall pleura is frequently (approximately 30% of cases) not involved, it is impossible in these cases to provide a diagnosis by blind needle biopsy [53]. Furthermore, because of the large size of biopsies obtained at thoracoscopy it may be much easier for the pathologist to suggest the organ from which the tumour originates [11]. In metastatic breast cancer, tissue can be obtained for determination of hormone receptors [54]. Even with lymphomas, the diagnostic yield as well as the morphological classification is improved [41, 55].

Therapeutically, several litres of fluid can be completely and immediately removed during thoracoscopy with little risk of pulmonary oedema, because of immediate equilibration of pressures by direct entrance of air into the pleural space [4]. Furthermore the re-expansion potential of the lung can be evaluated by visual inspection. In addition, the extent of intrapleural tumour spread can be described using a scoring system which correlates quite close with survival [56]. The main advantage is certainly that talc poudrage can be performed during medical thoracoscopy, which today is the best conservative option for pleurodesis [5, 22, 57–62], possibly because a very even distribution of the talc powder to all parts of the pleura is achieved. It has also been shown to be very efficient in the treatment of lymphomatous chylothorax [63].

### Tuberculous pleural effusions

Tuberculosis now causes less than 10% of all effusions seen in Western Europe and the USA, and comprises a still lower percentage of all chronic cases [34, 40]. Although, in a review of the literature on 1,325 cases [64], the yield of blind needle biopsy averages 69% with a range of 28–88% including results from multiple biopsies and TB cultures. The diagnostic accuracy of thoracoscopy is greater, because the pathologist is provided with multiple, selected biopsies and because the cultural proof of tubercle bacilli growth is more frequently positive. In a prospective inpatient comparison [65], the immediate diagnosis in 100 TB cases was established histologically by thoracoscopy in 94%, compared to needle biopsy (Trucut) with only 38% positive results. This may be of clinical importance, because antituberculous chemotherapy can be started without delay. The combined yield of histology and bacteriological culture was for medical thoracoscopy 99% and for needle biopsy 51% and when culture results from effusions were added 61% (fig. 4). The percentage of positive TB cultures was twice as high from thorascopic biopsies, including cultures from fibrous membranes (78%), as the percentage in pleural effusions and needle biopsies combined (39%), allowing bacteriological confirmation of the diagnosis and, furthermore, susceptibility tests. In five of the 78 positive cases (6.4%), resistance against one or multiple antituberculous drugs was found, which had some influence on therapy and prognosis. The chance for positive TB cultures was much higher (87%) in cases with fibrin production. This type, with a diffusely thickened pleura, multiple adhesions and sometimes formation of encapsulating membranes with fluid loculations was present in 75% of cases. By comparison, the pathognomonic picture of sago-like early pleuri-

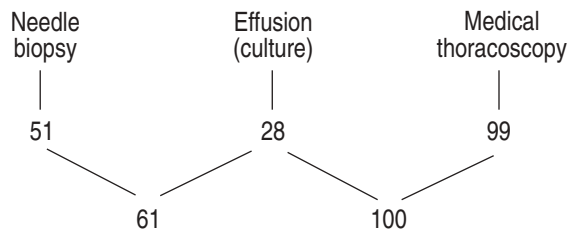


Fig. 4. — The different biopsy techniques used in the diagnosis of tuberculous pleural effusions and their sensitivity expressed in percentages (histological and bacteriological results combined). Prospective intrapatient comparison (n=100). Taken from [28].

tis with miliary tuberculous granulomas and without fibrin layers was seen in only 25%. Here, a positive TB culture was obtained from all materials in only 50%, giving a highly significant difference ( $p < 0.0005$ ). Interestingly, this study also showed that the chance of positive TB cultures from pleural effusion alone was statistically much better in cases with a low pleural glucose level ( $< 50 \text{ mg}\cdot\text{dL}^{-1}$ ) indicating an increased metabolism by TB bacilli and/or a higher degree of inflammation (59% positive *versus* 25% with glucose levels above  $50 \text{ mg}\cdot\text{dL}^{-1}$ ,  $p < 0.005$ ). But the first group comprised only 17% of the patients, suggesting that the majority of the cases were diagnosed at quite an early stage. Cell differentiation was shown: in 71% mainly lymphocytes, in 9% neutrophils, predominating in the early stages of growth without fibrin production, and in 20% no characteristic cells at all.

In another prospective study in 40 cases from South Africa, thoracoscopy had a diagnostic yield of 98% in comparison with an 80% diagnostic yield with Abram's needle biopsies [66]. This led to the conclusion that in areas with a high prevalence of TB, Abram's needle biopsy (in this case three biopsies were obtained and each examined histologically and microbiologically) can contribute significantly to the diagnosis. However, in a further study on the effect of corticosteroids in the treatment of TB pleurisy, the authors found that the initial complete drainage of the effusion, performed during thoracoscopy, was associated with greater symptomatic improvement than any subsequent therapy [67]. No studies are known which compare the influence of thoracoscopy with its early diagnosis and complete drainage and subsequent drug treatment to a group with drug treatment alone. At least in our institution, after thoracoscopy with the possibility of open-ing intrapleural loculations and evacuating the pleural fluid completely, together with the early initiation of drug treatment, no single case has been observed during the last decade which needed decortication because of development of fibrothorax.

In our view, one should not treat patients with antituberculous drugs, merely on the suspicion of a tuberculous pleurisy, if they present with a high lymphocyte count in the pleural fluid and a positive skin test [68]. At least in countries with a low prevalence of TB, where even other laboratory tests such as adenosine deaminase may not be very distinctive [69, 70], medical thoracoscopy should be performed when needle biopsies show negative results, in order to prove or exclude TB. In addition, the high yield in positive TB cultures from thoracoscopic biopsies gives rise to the possibility of obtaining susceptibility tests which,

in the case of drug resistance, may have some influence on therapy and prognosis [65].

### Other pleural effusions

In cases with effusions that are neither malignant nor tuberculous, thoracoscopy may give macroscopic clues to their aetiology, *e.g.* in rheumatoid effusions, effusions following pancreatitis, liver cirrhosis, extension from the abdominal cavity, or trauma [4, 71]. Although, in these entities history, pleural fluid analysis, physical and other examinations are usually diagnostic [31, 35], thoracoscopy may be indicated in those cases without a definite diagnosis. When the pleural effusions are secondary to underlying primary lung diseases, such as pulmonary infarct or pneumonia, the diagnosis can frequently be made on macroscopic examination, and be confirmed microscopically from a biopsy of the lung [4]. As already mentioned, thoracoscopy is well suited for the diagnosis of benign asbestos-related pleural effusions, which, by definition, present a diagnosis of exclusion [51].

In other pleural effusions, when the origin is unknown, the main diagnostic value of thoracoscopy lies in its ability to exclude malignant and tuberculous disease [71]. By means of thoracoscopy the proportion of so-called idiopathic pleural effusions falls usually markedly below 10% [11, 42, 64, 72], whereas studies which have not used thoracoscopy report failure to obtain a diagnosis in over 20% [36–38]. But, this certainly also depends upon the selection of patients [72, 73] and the definition of "idiopathic". In a study from an area with a high prevalence of TB, diagnosis was established in 86.5% without the use of thoracoscopy. Only very few malignant cases were detected during the follow-up [32]. In another series of 620 patients, although no details are given on the definite diagnosis of 92%, it was supposed that only 8% remained without a diagnosis after less invasive procedures [74]. Thoracoscopy established the diagnosis of malignancy in half of these patients. In our own experience, the proportion of pleural effusions from other origins, which underwent medical thoracoscopy, is in relative numbers decreasing: falling from 37% in the 1970s and 38% in the 1980s [28] to 24% in the 1995–1996 time period. The proportion of tuberculous pleurisy fell from 24 to 14 and 8% in the same time period, whereas the proportion of malignant pleural effusions rose from 39% in the 1970s to 48% in the 1980s to 68% in 1997 (see table 1).

Occasionally, it is impossible to perform thoracoscopy in the presence of effusion because of dense pleuropulmonary adhesions. This is usually observed as a consequence of repeated aspirations of larger volumes of pleural fluid and we would not consider this an appropriate diagnostic approach [4, 28]. Only in rare cases where it is impossible to perform thoracoscopy because of pleuropulmonary adhesions or in those cases remaining undiagnosed after medical thoracoscopy and thought to be due to disease for which there might be a specific therapy, it may be worthwhile to consider as a further diagnostic step surgical thoracoscopy (VATS) or exploratory thoracotomy, eventually combined with decortication [39].

In some selected cases of recurrent pleural effusions of nonmalignant aetiology including chylothorax, pleurodesis may be induced by applying talc poudrage during medical thoracoscopy [62, 75, 76].

## Empyema

Medical thoracoscopy can also be useful in the management of early empyema [30, 77]. In cases with multiple loculations, it is possible to open these spaces, to remove the fibrinopurulent membranes by forceps and to create one single cavity, which can be drained and irrigated much more successfully [5, 78, 79]. This treatment should be carried out early in the course of empyema, before the adhesions become too fibrous and adherent. Thus, if the indication for placement of a chest tube is present [80] and if the facilities are available, medical thoracoscopy should be performed at the time of chest-tube insertion. Overall, medical thoracoscopy is a procedure similar to chest-tube placement but allows the creation of one single pleural cavity allowing much better local treatment [21]. Prospective studies on this use of medical thoracoscopy have not yet been done. Successful thoracoscopic treatment has also been reported in children [81, 82].

VATS is definitely a more invasive procedure because general anaesthesia and selective double lumen intubation are necessary. This should be avoided, if possible, in these often very sick patients [21]. Surgery, however, is certainly indicated in the later, organizational stage with dense and extensive adhesions [83].

## Spontaneous pneumothorax

In spontaneous pneumothorax, medical thoracoscopy can be applied easily for diagnostic and therapeutic purposes, if the skills and the facilities for this technique are available [4, 5, 16, 28]. In particular, if a chest tube is introduced by trocar technique, it is easy to use an optic for visual inspection of the lung and the pleural cavity, before the insertion of the chest tube through this cannula. On inspection during medical thoracoscopy, the underlying lesions can be directly assessed according to the classification of VANDERSCHUEREN [19]: stage I with an endoscopically normal lung; stage II with pleuropulmonary adhesions; stage III with small bullae and blebs (<2 cm in diameter); and stage IV with numerous large bullae (>2 cm in diameter). In 1,047 cases where medical thoracoscopy was used by three different teams [84–86], pathological lesions were detected in about 70% of the cases with only slightly differing percentages for stages II–IV; blebs and bullae were present in 45–62%. False classification of stage I was shown at surgery in 8–28% of cases [84–86]. Although the detection rates of blebs and bullae are higher (76–100%) in series with VATS or thoracotomy [87], it is unlikely that larger bullae and blebs or fistulae will not be detected during medical thoracoscopy.

Medical thoracoscopy offers the possibility to combine chest drainage with coagulation of blebs and bullae as well as pleurodesis with talc poudrage [5, 88]. Talc poudrage achieves the best conservative treatment results with recurrence rates below 10% [22, 89, 90]. Subsequent surgical intervention was necessary in 4–10% of the cases in the three above-mentioned series [84–86]. In stage IV with numerous large bullae, usually the indication for VATS or thoracotomy is given. These patients should be transferred directly to the surgical department after insertion of a chest tube. Talc poudrage and/or coagulation of bullae are performed only in cases where surgery is con-

tra-indicated, e.g. because of respiratory insufficiency, secondary to severe bronchitis or other advanced pulmonary disease [90].

In our view, medical thoracoscopy is routinely justified in all patients with spontaneous pneumothorax where tube drainage is indicated, since several advantages are offered: precise assessment of underlying lesions under direct visual control, choice of best (conservative or surgical) treatment measures, direct treatment by coagulation of blebs and bullae, and by severing of adhesions, if necessary, followed by talc poudrage as well as selection of the best location for the chest-tube placement [28]. Furthermore, pneumothorax is a practical and easy opportunity for the young pneumologist to learn medical thoracoscopy and to gain confidence in handling the various instruments.

## Summary

Primarily introduced as a diagnostic procedure, thoracoscopy was applied between 1915–1955 almost exclusively therapeutically in the pneumothorax treatment of tuberculosis. In the early 1960s, thoracoscopy was used, mainly by pneumologists in Europe, on a much broader basis for the diagnosis of many pleuropulmonary diseases. At the beginning of the 1990s with the tremendous advances in endoscopy technology and the trend toward less invasive operations, thoracoscopy was also rediscovered by the thoracic surgeons. But surgical thoracoscopy requires general anaesthesia with selective endobronchial intubation and at least three points of entry, and it should be called more correctly "video-assisted thoracic surgery (VATS)". Medical thoracoscopy, performed by the pneumologist in an endoscopy suite, is much less invasive requiring only local anaesthesia or conscious sedation and only one or two points of entry.

The main indications of medical thoracoscopy are in 1998 in the diagnosis and treatment of pleural effusions and pneumothorax. In pleural effusions medical thoracoscopy provides the proof or exclusion of malignancy and tuberculosis with an accuracy approaching 100%. As a staging procedure it helps determine the aetiology and extent, and possibly, prognosis of malignant effusions as well as treatment strategies.

The insufflation of talc powder during thoracoscopy is in 1998 the best conservative method of pleurodesis in malignant and recurrent benign effusions, including chylothorax. Medical thoracoscopy has proved also to be successful in the management of empyema and of spontaneous pneumothorax. In the future, it may become even more popular once more respiratory physicians are trained in using the procedure.

## References

1. Jacobaeus HC. Über die Möglichkeit, die Zystoskopie bei Untersuchung seröser Höhlen anzuwenden. *Munch Med Wschr* 1910; 40: 2090–2092.
2. Jacobaeus HC. Die Thorakoskopie und ihre praktische Bedeutung. *Ergebn ges Med* 1925; 7: 112–166.
3. Jacobaeus HC. The cauterization of adhesions in artificial pneumothorax therapy of tuberculosis. *Am Rev Tuberc* 1922; 6: 871–897.
4. Brandt HJ, Loddenkemper R, Mai J. Atlas of Diagnostic

- Thoracoscopy. New York, Thieme Stuttgart, Thieme Inc., 1985.
5. Boutin C, Viallat JR, Aelony Y. Practical Thoracoscopy. Berlin, Springer, 1991.
  6. Miller JI Jr. Therapeutic thoracoscopy: new horizons for an established procedure (Editorial). *Ann Thorac Surg* 1991; 52: 1036–1037.
  7. LoCicero J. Minimally invasive thoracic surgery, video-assisted thoracic surgery and thoracoscopy (Editorial). *Chest* 1992; 102: 330–331.
  8. Inderbitzi R. Chirurgische Thorakoskopie. Berlin, Springer, 1993.
  9. Tape TG, Blank LL, Wigton RS. Procedural skills of practicing pulmonologists: a national survey of 1,000 members of the American College of Physicians. *Am J Respir Crit Care Med* 1995; 151: 282–287.
  10. Dijkman JH, Martinez Gonzales del Rio J, Loddenkemper R, Prowse K, Siafakas N. Report of the working party of the "UEMS monospecialty section on pneumology" on training requirements and facilities in Europe. *Eur Respir J* 1994; pp. 1019–1022.
  11. Boutin C, Viallat JR, Cargnino P, Fariße P. Thoracoscopy in malignant pleural effusions. *Am Rev Respir Dis* 1981; 124: 588–592.
  12. Rodriguez Panadero F. Derrames pleural malignos. *Rev Port Pneumol* 1995; 1: 25–31.
  13. American Thoracic Society. Medical thoracoscopy (Position paper). In preparation.
  14. Bartter T, Santarelli RJ, Pratter MR. Transudate versus exudate: Genug! (Editorial). *Chest* 1996; 109: 1419–1421.
  15. Janssen J, Boutin C. Extended thoracoscopy: a method to be used in case of pleural adhesions. *Eur Respir J* 1992; 5: 763–766.
  16. Mathur PN, Boutin C, Loddenkemper R. Medical thoracoscopy: technique and indications in pulmonary medicine. *J Bronchol* 1994; 1: 228–239.
  17. Mathur PN. "Medical" thoracoscopy. How I do it. *J Bronchol* 1994; 1: 144–151.
  18. Oldenburg FA Jr, Newhouse MT. Thoracoscopy. A safe accurate diagnostic procedure using the rigid thoracoscope and local anesthesia. *Chest* 1979; 75: 45–50.
  19. Vanderschueren RG. Le talcage pleural dans le pneumothorax spontané. *Poumon Coeur* 1981; 37: 273–276.
  20. Menzies R, Charbonneau M. Thoracoscopy for the diagnosis of pleural disease. *Ann Intern Med* 1991; 114: 271–276.
  21. Colt HG. Thoracoscopy: a prospective study of safety and outcome. *Chest* 1995; 108: 324–329.
  22. Kennedy L, Sahn SA. Talc pleurodesis for the treatment of pneumothorax and pleural effusion. *Chest* 1994; 106: 1215–1222.
  23. Davidson AC, George RJ, Sheldon CD, Sinha G, Corin B, Geddes DM. Thoracoscopy: assessment of a physician service and comparison of a flexible bronchoscope used as a thoracoscope with a rigid thoracoscope. *Thorax* 1988; 43: 327–332.
  24. Yim AP. Improved technique for fiberoptic pleuroscopy (letter). *Chest* 1996; 109: 1667.
  25. Viskum K, Enk B. Complications of thoracoscopy. *Poumon Coeur* 1981; 37: 11–19.
  26. Faurschou P, Madsen F, Viskum K. Thoracoscopy: influence of the procedure on some respiratory and cardiac values. *Thorax* 1983; 38: 341–343.
  27. Boutin C, Rey F, Viallat JR. Prevention of malignant seeding after invasive diagnostic procedures in patients with pleural mesothelioma. A randomized trial of local radiotherapy. *Chest* 1995; 108: 754–758.
  28. Loddenkemper R, Boutin C. Thoracoscopy: Diagnostic and therapeutic indications (Review). *Eur Respir J* 1993; 6: 1544–1555.
  29. Harris RJ, Kavuru MS, Rice TW, Kirby TJ. The diagnostic and therapeutic utility of thoracoscopy. A Review. *Chest* 1995; 108: 828–841.
  30. Kaiser D. Indikationen zur Thorakoskopie beim Pleuraempyem. *Pneumologie* 1989; 43: 76–79.
  31. Light RW. Diagnostic principles in pleural disease. *Eur Respir J* 1997; 10: 476–481.
  32. Ferrer JS, Munoz XG, Orriols RM, Light RW, Morrell FB. Evolution of idiopathic pleural effusion. A prospective, long-term follow-up study. *Chest* 1996; 109: 1508–1513.
  33. Loddenkemper R, Mai J, Scheffler N, Brandt HJ. Prospective individual comparison of blind needle biopsy and of thoracoscopy in the diagnosis and differential diagnosis of tuberculous pleurisy. *Scand J Resp Dis* 1978; 102 (Suppl.): 196–198.
  34. Ferrer J. Pleural tuberculosis. *Eur Respir J* 1997; 10: 942–947.
  35. Sahn SA. Pleural diseases related to metastatic malignancies. *Eur Respir J* 1997; 10: 1907–1913.
  36. Storey DD, Dines DE, Coles DT. Pleural effusion. A diagnostic dilemma. *J Amer Med Ass* 1976; 236: 2183–2186.
  37. Hirsch A, Ruffie P, Nebut M, Bignon J, Chrétien J. Pleural effusion: laboratory tests in 300 cases. *Thorax* 1979; 34: 105–112.
  38. Lamy P, Canet B, Martinet Y, Lamaze R. Evaluation des moyens diagnostiques dans les épanchements pleuraux. *Poumon Coeur* 1980; 36: 83–94.
  39. Ryan CJ, Rodgers RF, Uni UK, Hepper NG. The outcome of patients with pleural effusion of indeterminate cause at thoracotomy. *Mayo Clin Proc* 1981; 56: 145–149.
  40. Light RW. Pleural diseases. 3rd Edn. Baltimore, Williams and Wilkins, 1995.
  41. Loddenkemper R, Grosser H, Gabler A, Mai J, Preussler H, Brandt HJ. Prospective evaluation of biopsy methods in the diagnosis of malignant pleural effusions. Inpatient comparison between pleural fluid cytology, blind needle biopsy and thoracoscopy. *Am Rev Respir Dis* 1983; 127 (Suppl. 4): 114.
  42. Canto A, Blasco E, Casillas M, et al. Thoracoscopy in the diagnosis of pleural effusions. *Thorax* 1977; 32: 550–554.
  43. Weissberg D, Kaufmann M, Schwecher I. Pleuroscopy in clinical evaluation and staging of lung cancer. *Poumon Coeur* 1981; 37: 241–243.
  44. Canto A, Ferrer G, Romagosa V, Moya J, Bernat R. Lung cancer and pleural effusion. Clinical significance and study of pleural metastatic locations. *Chest* 1985; 87: 649–652.
  45. Boutin C, Rey F. Thoracoscopy in pleural malignant mesothelioma: a prospective study of 188 consecutive patients. Part 1: Diagnosis. *Cancer* 1993; 72: 389–393.
  46. Boutin C, Rey F, Gouvert J, Viallat J-R, Astoul P, Ledoray V. Thoracoscopy in pleural malignant mesothelioma. Part 2: Prognosis and staging. *Cancer* 1993; 72: 394–404.
  47. International Mesothelioma Interest Group. A proposed new international TNM staging system for malignant pleural mesothelioma. *Chest* 1995; 108: 1122–1128.
  48. Boutin C, Viallat JR, Van Zandwijk N, et al. Activity of intrapleural recombinant gamma-interferon in malignant mesothelioma. *Cancer* 1991; 67: 2033–2037.
  49. Astoul P, Viallat JR, Laurent JC, Brandely M, Boutin C.



- Intrapleural recombinant IL-2 in passive immunotherapy for malignant pleural effusion. *Chest* 1993; 103: 209–213.
50. Boutin C, Nussbaum E, Monnet I, *et al*. Intrapleural treatment with recombinant gamma-interferon in early stage malignant pleural mesothelioma. *Cancer* 1994; 74: 2460–2467.
  51. Hillerdal G, Ozermi M. Benign asbestos pleural effusions: 73 exudates in 60 patients. *Eur J Respir Dis* 1997; 71: 113–121.
  52. Boutin C, Dumortier P, Rey F, Viallat JR, De Vuyst P. Black spots concentrate oncogenic asbestos fibers in the parietal pleura. Thoracoscopic and mineralogic study. *Am J Respir Crit Care Med* 1996; 153: 444–449.
  53. Canto A, Rivas J, Saumench J, Morera R, Moya J. Points to consider when choosing a biopsy method in cases of pleurisy of unknown origin. *Chest* 1983; 84: 176–179.
  54. Levine MN, Young JE, Ryan ED, Newhouse MT. Pleural effusion in breast cancer. Thoracoscopy for hormone receptor determination. *Cancer* 1986; 57: 324–327.
  55. Celikoglu F, Teirstein AS, Krellenstein DJ, Strauchen JA. Pleural effusion in non-Hodgkin's lymphoma. *Chest* 1992; 101: 1357–1360.
  56. Sanchez-Armengol A, Rodriguez-Panadero F. Survival and talc pleurodesis in metastatic pleural carcinoma, revisited. Report of 125 cases. *Chest* 1993; 104: 1482–1485.
  57. Aelony Y, King R, Boutin C. Thoracoscopic talc poudrage pleurodesis for chronic recurrent pleural effusions. *Ann Intern Med* 1991; 115: 778–782.
  58. Hartman DL, Gaither JM, Kesler KA, Mylet DM, Brown JW, Mathur PN. Comparison of insufflated talc under thoracoscopic guidance with standard tetracycline and bleomycin pleurodesis for control of malignant pleural effusions. *J Thorac Cardiovasc Surg* 1993; 105: 743–748.
  59. Walker-Renard PB, Vaughan LM, Sahn SA. Chemical pleurodesis for malignant pleural effusions. *Ann Intern Med* 1994; 120: 56–64.
  60. Colt HG. Thoracoscopic management of malignant pleural effusions. *Clin Chest Med* 1995; 16: 505–518.
  61. Viallat JR, Rey F, Astoul P, Boutin C. Thoracoscopic talc poudrage. Pleurodesis for malignant effusions. A review of 360 cases. *Chest* 1996; 110: 1387–1393.
  62. Rodriguez-Panadero F, Antony VB. Pleurodesis. State of the art. *Eur Respir J* 1997; 10: 1648–1654.
  63. Mares CC, Mathur PN. Thoracoscopic talc pleurodesis for lymphoma induced chylothorax, a case series of twenty two treated hemithoraces in eighteen patients. *Am J Respir Crit Care Med* 1997; 155: A481.
  64. Loddenkemper R, Mai J, Scheffler N, Brandt HJ. Wertigkeit bioptischer Verfahren beim Pleuraerguß: Individueller Vergleich zwischen Exsudatuntersuchung, Stanzenbiopsie und Thorakoskopie. *Prax Klin Pneumol* 1978; 32: 334–343.
  65. Loddenkemper R, Grosser H, Mai J, Preussler H, Wundschöck M, Brandt HJ. Diagnostik des tuberkulösen Pleuraergusses: Prospektiver Vergleich laborchemischer, bakteriologischer, zytologischer und histologischer Untersuchungsergebnisse. *Prax Klin Pneumol* 1983; 37: 1153–1156.
  66. Walz G, Wyser C, Smedema J, Corbett C, van de Wal B. Comparing the diagnostic yield of Abrams needle pleural biopsy and thoracoscopy. *Am J Respir Crit Care Med* 1996; 153: A460.
  67. Wyser C, Walz G, Smedema JP, Swart F, van Schalkwyk EM, van de Wal BW. Corticosteroids in the treatment of tuberculous pleurisy. A double-blind, placebo-controlled, randomized study. *Chest* 1996; 110: 333–338.
  68. Roper WH, Waring JJ. Primary serofibrinous pleural effusion in military personnel. *Am Rev Tuberc* 1955; 71: 616–634.
  69. van Kempeima AR, Slaats EH, Wagenaar JP. Adenosine deaminase activity, not diagnostic for tuberculous pleurisy. *Eur J Respir Dis* 1987; 71: 15–18.
  70. Maartens G, Bateman ED. Tuberculous pleural effusions: increased culture yield with bedside inoculation of pleural fluid and poor diagnostic value of adenosine deaminase. *Thorax* 1991; 46: 96–99.
  71. Loddenkemper R. Thoracoscopy: results in non-cancerous and idiopathic pleural effusions. *Poumon Coeur* 1981; 37: 261–264.
  72. Martensson G, Petterson K, Thiringer G. Differentiation between malignant and non-malignant pleural effusion. *Eur J Respir Dis* 1985; 67: 326–334.
  73. Valdes L, Alvares D, Valle JM, Pose A, San José E. The etiology of pleural effusions in an area with high incidence of tuberculosis. *Chest* 1996; 109: 158–162.
  74. Kendall SW, Bryan AJ, Large SR, Wells FC. Pleural effusions: is thoracoscopy a reliable investigation? A retrospective review. *Respir Med* 1992; 86: 437–440.
  75. Sudduth C, Sahn SA. Pleurodesis for non-malignant pleural effusions. Recommendations. *Chest* 1992; 102: 1855–1860.
  76. Vargas FS, Milanez JRC, Filomeno LTB, Fernandez A, Jatene A, Light RW. Intrapleural talc for the prevention of recurrence in benign or undiagnosed pleural effusions. *Chest* 1994; 106: 1771–1775.
  77. Weissberg D. Pleuroscopy in empyema: is it ever necessary? *Poumon Coeur* 1981; 37: 269–272.
  78. Ridley PD, Braimbridge MV. Thoracoscopic debridement and pleural irrigation in the management of empyema thoracis. *Ann Thorac Surg* 1991; 51: 461–464.
  79. Sendt W, Forster E, Hau T. Early thoracoscopic debridement and drainage as definite treatment for pleural empyema. *Eur J Surg* 1995; 161: 73–76.
  80. Hamm H, Light RW. Parapneumonic effusion and empyema. *Eur Respir J* 1997; 10: 1150–1156.
  81. Kern JA, Rodgers BM. Thoracoscopy in the management of empyema in children. *J Pediatr Surg* 1993; 28: 1128–1132.
  82. Stovroff M, Teague G, Heiss KF, Parker P, Ricketts PR. Thoracoscopy in the management of pediatric empyema. *J Pediatr Surg* 1995; 30: 1211–1215.
  83. Martella AT, Santos GH. Decortication for chronic post-pneumonic empyema. *J Am Coll Surg* 1995; 180: 573–576.
  84. vd Brekel JA, Duurkens VAM, Vanderschueren RGJRA. Pneumothorax: results of thoracoscopy and pleurodesis with talc poudrage and thoracotomy. *Chest* 1993; 103: 345–347.
  85. El Khawand C, Marchandise FX, Maynel A, *et al*. Pneumothorax spontané. Résultats du talcage pleural sous thoracoscopie. *Rev Med Resp* 1995; 12: 275–281.
  86. Hausmann M, Keller R. Thorakoskopische Pleurodese beim Spontanpneumothorax. *Schweiz Med Wochenschr* 1994; 124: 97–104.
  87. Schramel FMNH, Postmus PE, Vanderschueren RGJRA. Current aspects of spontaneous pneumothorax. *Eur Respir J* 1997; 10: 1372–1379.
  88. Keller R, Guterson J, Herzog H. Die Behandlung des persistierenden Pneumothorax durch thorakoskopische Maßnahmen. *Thoraxchirurgie* 1974; 22: 457–460.
  89. Almind M, Lange P, Viskum K. Spontaneous pneumothorax: comparison of simple drainage, talc pleurodesis and tetracycline pleurodesis. *Thorax* 1989; 44: 627–630.
  90. Boutin C, Astoul P, Rey F, Mathur PN. Thoracoscopy in the diagnosis and treatment of spontaneous pneumothorax. *Clin Chest Med* 1995; 16: 497–503.