Eur Respir J 2009; 34: 324–331
DOI: 10.1183/09031936.00123008

Elastin expression in very severe human COPD

G. Deslee*,#,, J.C. Woods¶,+,**, C.M. Moore*, L. Liu*, S.H. Conradi¶, M. Milne+, D.S. Gierada¶, J. Pierce*, A. Patterson§, R.A. Lewit*, J.T. Battaile*, M.J. Holtzman*, J.C. Hogg^f and R.A. Pierce***

ABSTRACT: Alveolar elastic fibres are key targets of proteases during the pathogenesis of chronic obstructive pulmonary disease (COPD). In the current study, we hypothesised that a response to injury leads to enhanced alveolar elastin gene expression in very severe COPD.

Lung samples obtained from 43 patients, including 11 with very severe COPD (stage 4), 10 donors, 10 with moderate/severe COPD (stage 2–3) and 12 non-COPD subjects, were analysed for elastin mRNA expression by real-time RT-PCR and *in situ* hybridisation. Alveolar elastic fibres were visualised using Hart's staining of sections of frozen inflated lungs obtained from 11 COPD stage 4 patients and three donor lungs.

Compared with donors, non-COPD and stage 2–3 COPD, elastin mRNA expression was significantly increased in very severe COPD lungs (12-fold change), and localised *in situ* hybridisation induced elastin expression to alveolar walls. Compared with donors, alveolar elastic fibres also comprised a greater volume fraction of total lung tissue in very severe COPD lungs ($p<0.01$), but elastic fibre content was not increased per lung volume, and desmosine content was not increased.

The present study demonstrates enhanced alveolar elastin expression in very severe COPD. The efficiency of this potential repair mechanism and its regulation remain to be demonstrated.

KEYWORDS: Chronic obstructive pulmonary disease, elastin, emphysema, gene expression

AFFILIATIONS
*Depts of Internal Medicine,
¶Radiology,
+Physics, and
§Thoracic Surgery, Washington University School of Medicine, St Louis, MO, USA.
#Service de Pneumologie CHU Reims, IFR53, Reims, France.
^f James Hogg iCapture Centre for Cardiovascular and Pulmonary Research, University of British Columbia, Vancouver, BC, Canada.
**These authors contributed equally to the study.

CORRESPONDENCE
R.A. Pierce
Washington University School of Medicine
Campus Box 8052
660 So. Euclid Ave
St Louis
MO 63110
USA
E-mail: rpierce@dom.wustl.edu

Received:
Aug 08 2008
Accepted after revision:
March 31 2009
First published online:
April 08 2009

The pathogenesis of chronic obstructive pulmonary disease (COPD) involves both small airway remodelling and emphysema. Interconnecting elastic fibre cables facilitate coordinated expansion and relaxation of alveoli during respiration. Emphysema progression is inextricably linked to destruction of these alveolar elastic fibres by elastolytic proteases associated with a chronic tobacco smoke-induced inflammatory process and/or related to an antiprotease deficiency such as in α_1-antitrypsin deficiency [1]. At the present time, studies have not been carried out in order to determine whether damage to alveolar elastic fibres during the progression of COPD induces elastin expression as a response to injury. Pulmonary elastin expression normally peaks during alveolar development, declines thereafter, and is nearly undetectable in the healthy adult lung. Animal studies have shown that lung collagen and elastin synthesis is rapidly re-initiated following instillation of elastase and can limit the extent of alveolar destruction [2]. The objectives of the present study were to determine whether there is re-initiation of elastin expression in alveolar walls in severe emphysema, and to quantify alveolar elastic fibre density in severe emphysema.

Once formed, elastic fibres remain remarkably durable in normal, healthy lungs [3], but the concentration of urinary desmosines, which are cross-links unique to elastin, increases in COPD patients compared with controls. This biochemical evidence of elastin degradation is supported by findings of altered elastic fibre content and form in the emphysematous lung [4–6]. Of note, elastic fibre density has never been investigated in very severe COPD, and the potential for attempted repair of elastic fibres in very severe COPD has received little attention.

Our analysis of lung tissue from very severe (stage 4) COPD confirmed a robust induction of elastin expression in alveolar walls. These data indicate that lung tissue from patients with very severe COPD retains the capacity to express elastin precisely at sites of damage to elastic fibres.

MATERIALS AND METHODS

Study subjects

Patients scheduled for lung transplantation were recruited for the study following standards

European Respiratory Journal
Print ISSN 0903-1936
Online ISSN 1399-3003

established and approved by the institutional review board at Barnes-Jewish Hospital (St Louis, MO, USA). All COPD lung transplant patients without associated pulmonary fibrosis were eligible. The lungs from 11 individuals with very severe COPD (stage 4) were investigated. Donor lungs not used for transplantation (primarily because of last-minute surgical changes; n=3) and pieces of donor lungs resected to adjust the lung to an appropriate size for transplantation (n=7) were used for comparisons. Lung samples were also obtained from 12 non-COPD and 10 moderate/severe COPD (stage 2–3) patients undergoing lung resection for lung cancer. Demographic and lung function data were collected for all patients. COPD diagnosis was established on the basis of the Global Initiative for Chronic Obstructive Lung Disease consensus statement [7]. Individual informed consent was obtained from all the patients.

Study design

The objectives of the present study were to investigate elastin gene expression and elastic fibre density in very severe COPD lungs. Elastin gene expression was investigated in 43 patients including those with very severe COPD (n=11) and moderate/severe COPD (n=10), along with non-COPD patients (n=12) and donors (n=10) by real-time RT-PCR and *in situ* hybridisation. Elastic fibre density was investigated in 14 inflated whole lungs from 11 very severe COPD patients undergoing lung transplant and three donor lungs not used for transplantation. Elastic fibres were stained using Hart's staining and quantified in the alveolar walls. The relationships between alveolar elastic fibre density and the local–regional levels of emphysema assessed by histology, computed tomography (CT) scan and ^{3}He diffusion magnetic resonance imaging (MRI) were investigated.

Methods

Sampling scheme and image analysis

Explanted very severe COPD lungs and donor lungs not used for transplantation were placed on ice immediately and then cannulated. The intact lungs were frozen while inflated with air at constant pressure (13 cmH_2O) over circulating 77 K nitrogen vapour within 8 h of removal at transplantation, as previously described [8]. For five very severe COPD lungs and two donor lungs, imaging using ^{3}He diffusion MRI was performed just before the freezing process, as previously described [9]. CT imaging of frozen inflated lungs was performed and reconstructed in transverse planes. Frozen inflated lungs were then cut into 2 cm thick transverse slices (nine to 13 slices, depending on the size of the lung) in the same plane as the CT scan and then multiple cores of tissue measuring 1.3 cm in diameter were removed from each slice using a systematic, uniform random sampling system. The frozen tissue cores were subsequently divided for morphological analysis and for isolation of RNA and gene expression studies. Four to six cores per patient were randomly selected and studied.

Photos of sampled lung slices were used to match samples to CT and MRI images; each sample's location was carefully noted in relation to anatomical landmarks. The mean lung density, expressed in Hounsfield units (HU), was determined in regions of interest in the CT sections corresponding to each core using ImageJ (http://rsbweb.nih.gov/ij/; Bethesda, MD, USA). The ^{3}He apparent diffusion coefficient (ADC) was determined by MRI for each core [9].

Lung samples obtained from donor lungs (pieces resected to adjust the lung to an appropriate size for transplantation), and non-COPD and moderate/severe COPD patients treated by resection for lung cancer (avoiding areas affected by tumour) were kept frozen and divided for subsequent histological analysis and isolation of RNA for gene expression studies in the same manner as the cores from lung transplants. As these lung samples were not frozen inflated, elastic fibre density and morphometric analyses were not performed on these samples; they were only used for elastin real-time RT-PCR and *in situ* hybridisation.

RNA isolation and quantitative RT-PCR for elastin expression

Total RNA was isolated from each lung tissue sample using a commercial kit (RNAqueous; Ambion, Austin, TX, USA). The quality of RNA was assessed by an Agilent bioanalyser (Agilent Technologies, Palo Alto, CA, USA). cDNA was prepared using Superscript Plus (Invitrogen, Carlsbard, CA, USA) RT and random hexamer priming. cDNA was then subjected to PCR amplification for elastin (exons 2–4) and glyceraldehyde-3-phosphate dehydrogenase (GAPDH) as an internal control. Primers used were 5′-GGCCATTCCTGGT-GGAGTTCC-3′ as the elastin forward primer and 5′-AAC-TGGCTTAAGAGGTTTGCCTCCA-3′ for the elastin reverse primer, yielding a 106 bp product, and 5′-TGCACCACC-AACTGCTTAGC-3′ as the GAPDH forward primer and 5′-GGCATGGACTGTGGTCATGAG-3′ for the GAPDH reverse primer, yielding 87 bp with a Stratagene MX 3000 instrument (Stratagene, La Jolla, CA, USA). Standard and dissociation curves were generated and results using Sybr Green (Sigma-Aldrich, St Louis, MO, USA) for detection were standardised using the ΔΔCt method. Briefly, a ΔCt value was calculated for each sample using the cycle threshold (Ct) values for GAPDH and elastin. The fold change in elastin/GAPDH was expressed relative to the median value of the donor lungs. The ΔΔCt values were calculated by subtracting the median ΔCt of the donor group from the ΔCt of the non-COPD, stage 2–3 and stage 4 COPD patients. The ΔΔCt values were converted to fold differences *versus* the donors by raising 2 to the power ΔΔCt ($2^{-\Delta\Delta Ct}$).

In situ *hybridisation of elastin mRNA*

Digoxygenin-labelled antisense or sense riboprobes were generated from linearised human tropoelastin cDNA pHDE-1 by *in vitro* transcription (Promega, Madison, WI, USA) [10]. Rehydrated fixed sections of lung tissue were digested with proteinase K, blocked with triethanolamine and acetic anhydride then hybridised with denatured digoxygenin-labelled riboprobe overnight at 60°C. Following hybridisations, tissue sections were subjected to a series of washes including digestion with RNase A, treated with blocking agents, and incubated with an antibody conjugated to alkaline phosphatase. For colour development, slides were incubated with a chromogen substrate for 1–3 days then were counterstained with nuclear fast red. A minimum of 10 random lung fields per core were analysed. The number of positive cells for *in situ* hybridisation relative to the total number of alveolar wall cells was manually counted while blinded for sample identity.

TABLE 1 Characteristics of the study groups

	Donor	Non-COPD	COPD stage 2–3	COPD stage 4
Subjects	10	12	10	11
Age yrs	21 (19–26)#	62 (57–68)	69 (65–75)	57 (55–64)¶
Sex males/females	7/3	8/4	7/3	2/9
Smoking history pack-yrs	0 (0–1)#	45 (18–64)	48 (43–77)	55 (44–62)
Smoking status current/former/never	3/0/7	3/9/0	3/7/0	0/11/0
FEV_1 % pred	NA	101 (94–114)	61 (41–63)+	16 (15–19)§
FVC % pred	NA	103 (98–116)	84 (78–95)+	62 (50–63)§
FEV_1/FVC %	NA	76 (74–80)	57 (42–59)+	27 (23–29)§
TLC % pred	NA	103 (95–109)	111 (95–123)	147 (125–172)§
RV % pred	NA	112 (93–119)	129 (119–209)+	289 (229–376)§
Oral CS	NA	0/7ƒ	2/6##	2/11
Inhaled CS	NA	0/7ƒ	0/6##	4/11

Data are presented as n or median (interquartile range). COPD: chronic obstructive pulmonary disease; FEV_1: forced expiratory volume in 1 s; % pred: % predicted; FVC: forced vital capacity; TLC: total lung capacity; RV: residual volume; CS: corticosteroids; NA: not available. Differences between groups were determined using the Kruskall–Wallis test and differences between individual variables from two groups were analysed by the Mann–Whitney U-test. #: $p<0.05$ compared with non-COPD, COPD stage 2–3 and COPD stage 4; ¶: $p<0.05$ compared with donor, non-COPD and COPD stage 4; +: $p<0.05$ compared with non-COPD and COPD stage 4; §: $p<0.05$ compared with non-COPD and COPD stage 2–3.; ƒ: data available for seven out of 12 non-COPD patients; ##: data available for six out of 10 stage 2–3 COPD patients.

Morphometric analysis

Measurements of alveolar sizes (mean linear intercept (Lm)), were made on inflated tissue obtained from 11 stage 4 COPD and three donor lungs. Histological sections selected from each core following established stereological principles were stained with haematoxylin and eosin [11, 12]. A minimum of 10 random lung fields per core were analysed using a computer-assisted digital image analysis programme that was previously developed and tested in our laboratories [9]. The number of cells per area of inflated lung tissue was also manually counted while blinded for tissue identity.

Hart's elastin staining and quantification of elastic fibre density

Elastic fibre staining was performed on inflated lung samples obtained from 11 stage 4 COPD lungs and three donor lungs. Rehydrated lung tissue sections (5 μm) were soaked in 0.25% potassium permanganate solution for 5 min, cleared in 5% oxalic acid and soaked in resorcin–fuchsin solution (Poly Scientific, Bay Shore, NY, USA) overnight. After washing, sections were counterstained with tartrazine. A minimum of 10 random lung fields of Hart's-stained sections from each lung tissue core were captured with a digital camera at 20× magnification and imported into Image Pro Plus software

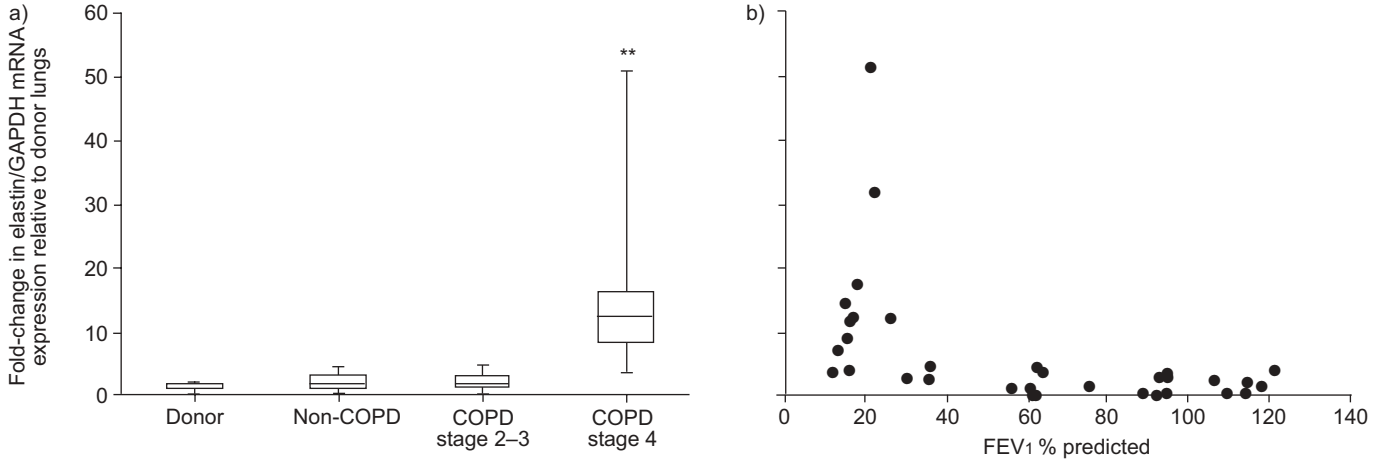

FIGURE 1. Elastin mRNA expression measured by real-time RT-PCR. a) Elastin mRNA relative to gylceraldehyde-3-phosphate dehydrogenase (GAPDH) mRNA in lung tissue from donors (n=10), non-chronic obstructive pulmonary disease (COPD) patients (n=12), and COPD stage 2–3 (n=10) and COPD stage 4 (n=11) patients. Differences between groups were determined using the Kruskall–Wallis test and differences between individual variables from two groups were analysed by the Mann–Whitney U-test. **: $p<0.01$ COPD stage 4 compared with donor, non-COPD and COPD stage 2–3. b) Relationships between elastin mRNA expression and forced expiratory volume in 1 s (FEV_1). Spearman correlation test was used to study the correlation between elastin mRNA expression and FEV_1. r= -0.58; $p<0.01$.

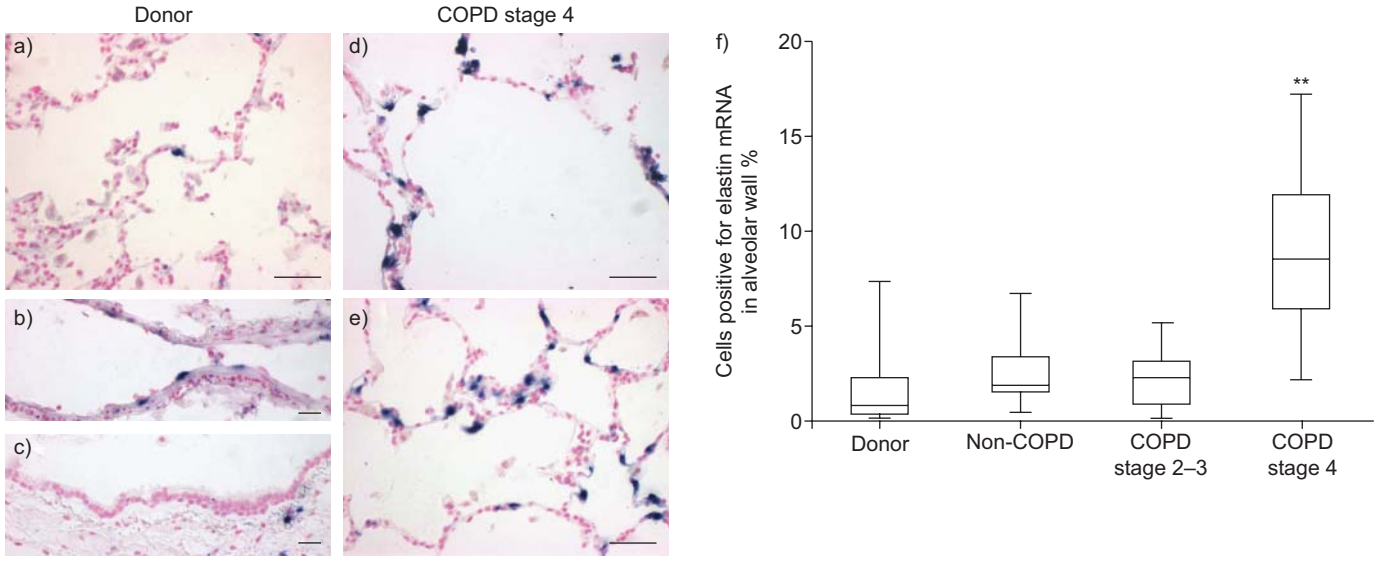

FIGURE 2. Localisation of elastin mRNA expression by *in situ* hybridisation. Specimens were hybridised with digoxygenin-labelled antisense and sense (not shown) riboprobes. Development yielded a blue signal and specimens were counterstained with nuclear fast red. Donor specimens showed little positive signal in a) alveolar, b) vascular and c) airway compartments. Stage 4 chronic obstructive pulmonary disease (COPD) lung showed positive alveolar wall signal in regions with d) severe and e) modest alveolar enlargement. f) Quantification of proportion of cells positive for elastin mRNA in alveolar wall in donor (n=10), non-COPD (n=12), stage 2–3 (n=10) and stage 4 COPD (n=11). Differences between groups were determined using the Kruskall–Wallis test and differences between individual variables from two groups were analysed by the Mann–Whitney U-test **: $p<0.01$ COPD stage 4 compared with donor, non-COPD and COPD stage 2–3. Scale bars=50 μm.

(MediaCybernetics, San Diego, CA, USA). Quantification of elastic fibre density per tissue was accomplished by determining the proportion of the area of tissue on each image that was black (elastic fibres) and yellow (remaining tissue) using Image Pro Plus software. The percentage of elastic fibre and tissue per area of inflated lung was also calculated. All images were captured with the same exposure to control for signal intensity.

To quantify desmosine content in lung cores, the lung samples were hydrolysed overnight at 110°C using constant boiling in 6 N HCl. Desmosine levels in the hydrolysates were determined by radioimmunoassay [13] and normalised to total protein. Desmosine dosages were performed by B. Starcher (Dept of Biochemistry, University of Texas Health Center at Tyler, Tyler, TX, USA).

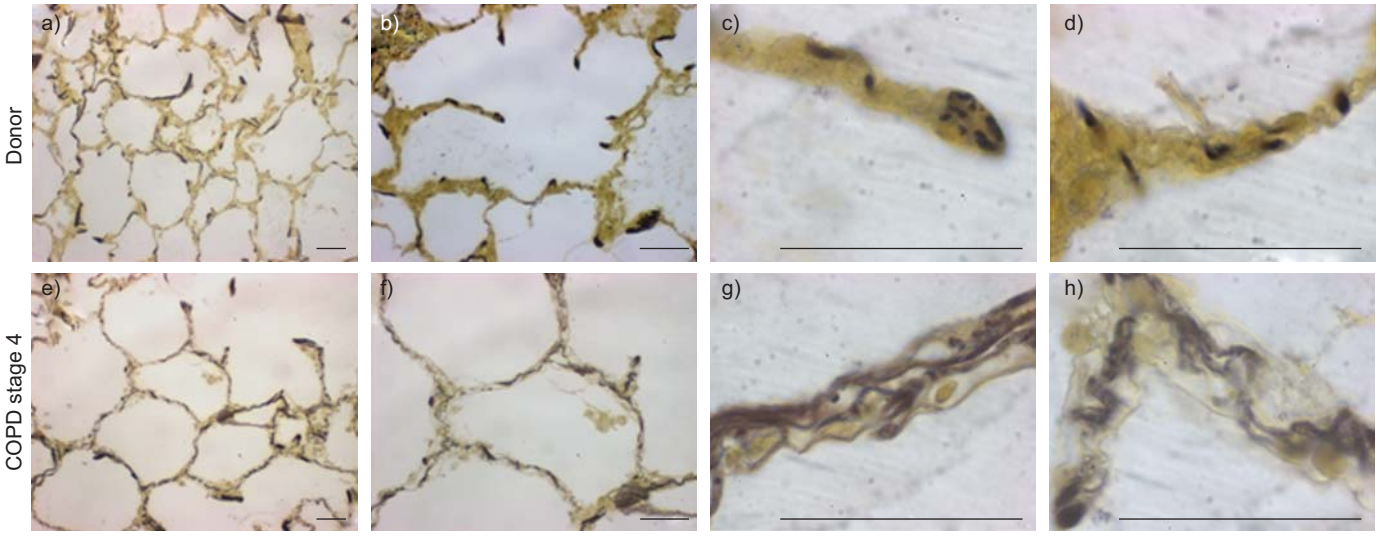

FIGURE 3. Elastic fibres in alveolar tissue. Representative sections of inflated lungs stained with Hart's stain for elastic fibres in a–d) donor lungs and e–h) stage 4 chronic obstructive pulmonary disease (COPD) lungs. Elastic fibres appear in black and the remaining tissue in yellow. Densely packed and tight elastic fibres are mainly localised to the tips of the alveolar ducts in donor lungs (a–d). Elastic fibres are less well organised, and appear unravelled and loose in COPD stage 4 (e–h). Data taken from three donor lungs and 11 stage 4 COPD lungs. Scale bars=50 μm.

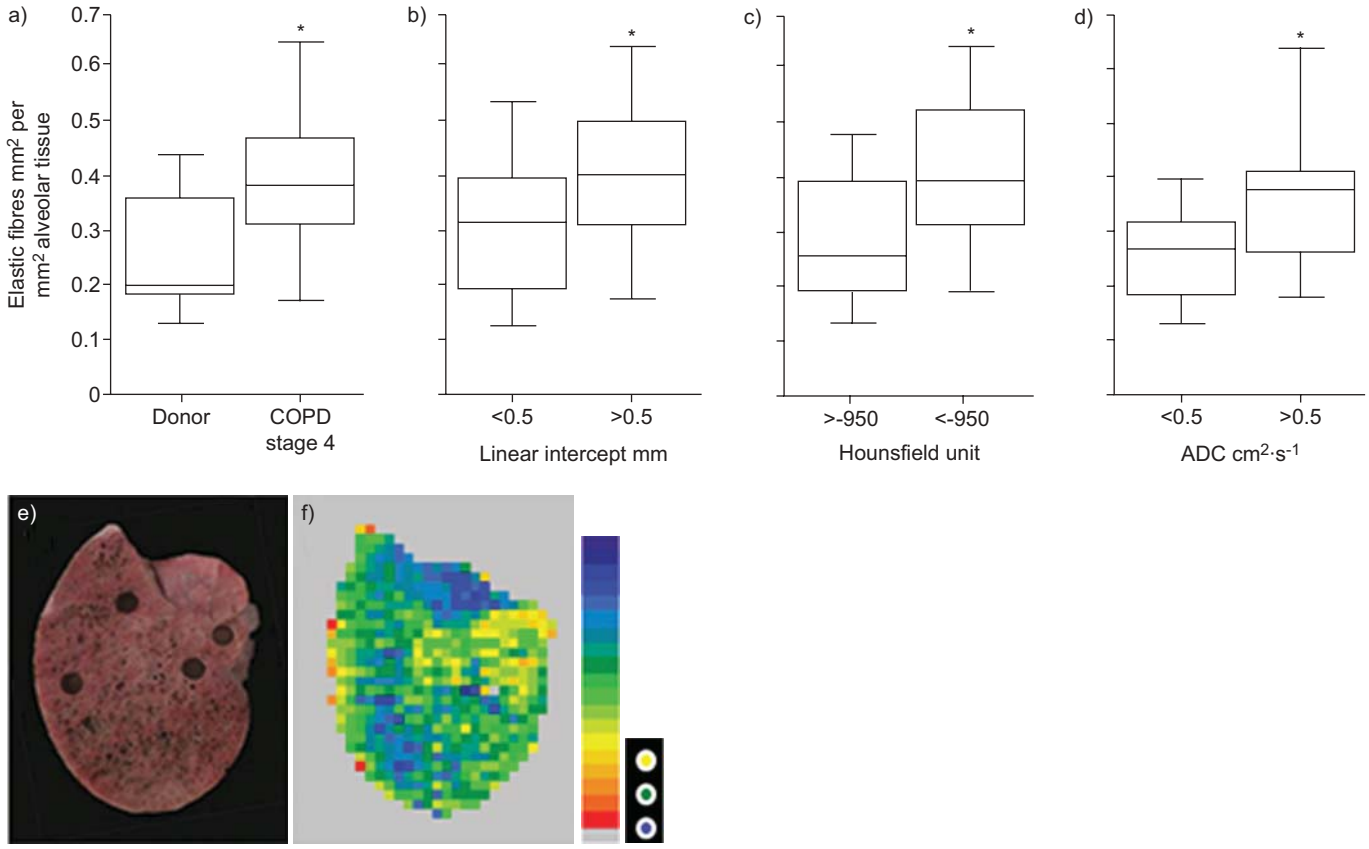

FIGURE 4. Elastic fibre density in alveolar tissue. a) Elastic fibre density in alveolar wall in inflated lung tissue from donor lungs and very severe stage 4 chronic obstructive pulmonary disease (COPD) patients. Comparison of elastic fibre density in areas with modest and significant alveolar enlargement assessed by b) histology, c) computed tomography scan and d) ^{3}He apparent diffusion coefficient (ADC). e) A representative photograph of a very severe COPD lung slice and its f) matched ^{3}He ADC image are shown. f) Yellow: ~0.3 $cm^2 \cdot s^{-1}$; green: ~0.5 $cm^2 \cdot s^{-1}$; blue: ~0.7 $cm^2 \cdot s^{-1}$. Data taken from three donor lungs (15 cores) and 11 very severe stage 4 COPD patients (51 cores), except for ^{3}He ADC, which was performed on two donor lungs and five stage 4 COPD lungs. Differences between the two groups were analysed by a Mann–Whitney U-test. *: $p<0.05$.

Data analysis

The data are expressed as median (interquartile range). Differences between groups were determined using the Kruskall–Wallis test and differences between individual variables from two groups were analysed by the Mann–Whitney U-test. Correlations between variables were analysed using the Spearman rank correlation test. A p-value <0.05 is considered significant.

RESULTS

Patient characteristics

The characteristics of the study subjects are presented in table 1. As expected by the selection of the patients, there were significant differences between very severe COPD (stage 4), moderate/severe COPD (stage 2–3) and non-COPD groups in airflow limitation and static hyperinflation. The donor group was significantly younger and had a much lower number of pack-years of smoking than the non-COPD and COPD groups. Pulmonary function tests were not obtained in donors.

Elastin gene expression

Elastin gene expression was investigated in very severe COPD, moderate COPD, non-COPD and donor lungs. Elastin mRNA expression relative to GAPDH was higher in very severe stage 4 COPD lungs (median 12.2-fold change) than in moderate/severe stage 2–3 COPD ($p<0.01$), non-COPD ($p<0.01$) and donor ($p<0.01$) lungs (fig. 1a). Elastin upregulation was correlated with the severity of airflow limitation (forced expiratory volume in 1 s; fig. 1b). No correlation was found between elastin gene expression and age, sex, pack-years of smoking or treatments (corticosteroid use) of the patients (not shown).

Localisation of elastin gene expression

Elastic fibres are present in multiple lung compartments, including the walls of airways and blood vessels, the pleura, and in alveolar walls. Therefore, the localisation of elastin mRNA expression was determined by *in situ* hybridisation with sense and antisense digoxygenin-labelled probes for elastin mRNA. Little signal for elastin mRNA was noted in alveolar walls of non-COPD, moderate/severe COPD and donor lung specimens (fig. 2a). Occasional positive cells were noted in smooth muscle layers in walls of intralobar pulmonary arteries (fig. 2b) and conducting airways (fig. 2c) in all groups. Elastin mRNA localised to individual cells in alveolar walls in lungs with very severe COPD, in regions of both modest (fig. 2d) and severe (fig. 2e) alveolar enlargement.

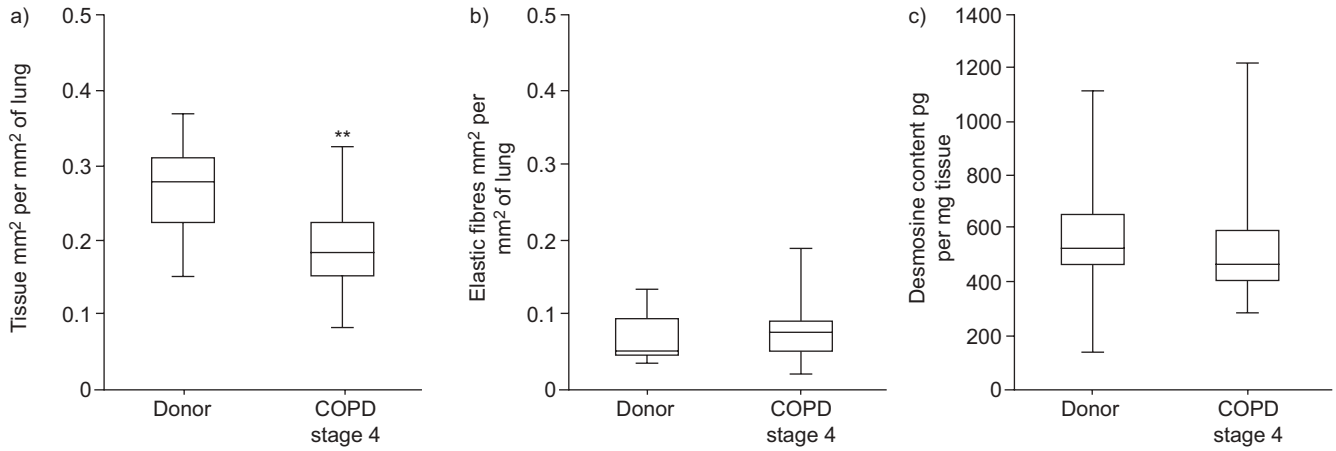

FIGURE 5. Tissue and elastic fibre density in the lung and desmosine content. a) Tissue density per area of lung in inflated lung tissue. b) Elastic fibre density per area of lung. c) Desmosine content per mg of tissue. Data taken from three donor lungs (15 cores) and 11 stage 4 chronic obstructive pulmonary disease (COPD) lungs (51 cores) for tissue and elastic fibre density, and from three donor lungs (12 cores) and seven stage 4 COPD lungs (23 cores) for desmosine. Differences between the two groups were analysed by a Mann-Whitney U-test. **: $p<0.01$.

Quantification of *in situ* hybridisation showed a significant increase in the number of positive cells in alveolar wall in very severe COPD compared with moderate/severe COPD, non-COPD and donor lungs (fig. 2f).

Elastic fibre staining and density

Alveolar elastic fibres were investigated in inflated tissue in donor (fig. 3a–d) and stage 4 COPD (fig. 3e–h) lungs. Alveolar elastic fibres were more densely packed and tight in donor lungs and mainly localised to the tips of the alveolar ducts (fig. 3b and c). In contrast, elastic fibres in stage 4 COPD lungs were less well organised and distributed in the alveolar wall with an unraveled and loose appearance (fig. 3f–h). Quantification of elastic fibre staining in alveolar sections showed that elastic fibres comprised a higher percentage of the total alveolar tissue in stage 4 COPD lung specimens than in donor lungs ($p<0.01$; fig. 4a). Next, we investigated the relationship between elastic fibre density and airspace enlargement assessed by histology (L_m), CT scan (HU) and ^{3}He ADC measured by MRI. Areas of lung with attenuation values lower than -950 HU on CT are considered emphysematous [14]. Based on our previous data, L_m >0.5 mm and ADC >0.5 $cm^2 \cdot s^{-1}$ were indicative of significant pulmonary emphysema [9]. The percentage of elastic fibres in total alveolar tissue was significantly higher in areas with greater airspace enlargement assessed by histology (L_m>0.5 mm; $p<0.05$; fig. 4b), CT scan (<-950 HU; $p<0.05$; fig. 4c) and ^{3}He ADC (>0.5 $cm^2 \cdot s^{-1}$; $p<0.05$; fig. 4d). As previously described by our group [9], ^{3}He ADC showed significant heterogeneity in alveolar size in COPD stage 4 lungs (fig. 4e and f). No correlation was found, however, between the levels of elastin expression and elastic fibre density or severity of emphysema destruction in very severe COPD patients (not shown).

As expected, the percentage of tissue (fig. 5a) and the number of cells (not shown) per area (mm^2) of inflated lung was lower in stage 4 COPD lungs than in donor lungs. Elastic fibre density per volume of lung (fig. 5b) and desmosine content (fig. 5c) was not increased in stage 4 COPD.

DISCUSSION

The most important result of our study was that elastin mRNA expression increased markedly and significantly in very severe COPD compared with moderate/severe COPD, non-COPD and donor specimens. This upregulation of gene elastin expression was correlated with the severity of airway limitation. *In situ* hybridisation demonstrated that gene elastin expression localised to alveolar walls, the sites of elastic fibre degradation in emphysema, and suggests that an attempted repair mechanism occurs in very severe COPD lungs. A substantial percentage of alveolar wall cells were positive for elastin mRNA in very severe COPD lungs. This result suggests that a substantial percentage of alveolar wall fibroblasts may switch to a synthetic, injury repair phenotype in severe COPD. Furthermore, we demonstrate that elastic fibres as a fraction of total alveolar tissue is increased in very severe COPD compared with donor lungs. On a volume basis including the enlarged airspace in COPD, desmosine content and elastic fibre density per area of inflated lung were not increased.

Research into the pathobiology of COPD has focused on an imbalance between proteases capable of degrading the elastin-rich architecture of the lung and their inhibitors, and more recently, on injury mechanisms that lead to changes in cellular phenotype and cellular death in the lung [15]. Most tissues respond to injury with repair mechanisms that, when successful, limit the loss of tissue function and re-establish homeostasis. TUDER *et al.* [16] have recently proposed that the heterogeneity of tissue destruction common in individual emphysematous lungs may result from local injury and variable efficacy of repair responses. Any potential for repair of alveolar wall elastic fibres before alveolar integrity that is lost is of interest. Except for reports of induced elastin expression in primary pulmonary hypertension [17], elastin expression in adult human lung has not been previously characterised. Finding induction of elastin expression in alveolar walls in very severe COPD may be unexpected, but KUHN and STARCHER [2] found that lung elastin and collagen synthesis were induced after elastolytic injury and limited the extent of alveolar enlargement in hamster lungs. Interestingly,

we found a significant upregulation of elastin expression only in very severe COPD, whereas moderate/severe COPD did not exhibit high elastin expression. The mechanisms involved in the upregulation of elastin expression in very severe COPD remain to be understood.

Given that elastin expression is strongly induced in lungs that have undergone significant alveolar enlargement, what role may elastin expression play in the pathogenesis of COPD? At this time, it is impossible to deduce whether such expression slows the progression of emphysema, or whether in patients who develop the most severe forms of COPD, new elastin expression occurs too late, after alveolar integrity is lost. Recently, SHIFREN and MECHAM [18] showed that elastin gene dosage determines susceptibility to cigarette smoke-induced emphysema in mice. URBAN *et al*. [19] have also shown that mutations in the elastin gene leading to cutis laxa in the skin also associate with bronchiectasis and pulmonary emphysema.

Not only is it surprising to find that elastin gene expression is strongly induced in alveolar walls in severe emphysema, but the present study finds increased elastic fibre density in alveolar walls in severe COPD. This additional new finding may differ from previous reports for several reasons. It must be pointed out that, in our study, the demographic characteristics of the two groups analysed for elastic fibre density in inflated tissue differed markedly in age and smoking history between donor and stage 4 COPD lungs. Still, we might expect to find higher elastic fibre density in younger and healthier lungs. One factor that could contribute to differences between this study and others is our use of inflation-fixed lung specimens, whereas many previous studies utilised uninflated lung specimens resected from cancer patients. In addition, we studied lungs with very severe COPD and many previous studies focused on mild-to-moderate COPD [4]. A limitation of our study is that we analysed only three inflated donor lungs. However, our study showed significant differences in elastic fibre density and morphology between the cores obtained from donor and COPD stage 4 lungs. Next, our results should be viewed in the context of extreme alveolar enlargement, with concomitant loss of alveolar wall tissue. When elastic fibre density is expressed relative to the volume of inflated lung, no difference is found between very severe COPD and donors. These results strongly suggest that the loss of tissue in very severe COPD outpaces the destruction of elastic fibres. Supporting this reasoning, it is well established that apoptosis and loss of capillary density occur in alveolar walls in COPD [15, 20–22]. Changes in alveolar elastic fibre form in severe emphysema may also affect the apparent elastic fibre density and volume fraction of total alveolar tissue. VLAHOVIC *et al.* [6] showed an increase in elastin per basement membrane in alveoli in mild-to-moderate emphysema, and suggested that the thin alveolar fibres of the septa disappear with only the thicker elastic fibres remaining at interacinar/intersegmentar walls in emphysema. Elastic fibres in emphysematous lungs have often been reported as having an unraveled appearance. If such changes do occur, as our studies indicate, the same mass of elastin could very well occupy a greater apparent volume. Regardless of changes in the form of elastic fibres, we did not find significant differences in desmosine content between donor lungs and very severe COPD lungs, indicating that the total mass of fully cross-linked elastin (including airway and vascular elastin) is not markedly increased in very severe COPD lung tissue. Interestingly, we did not find any correlation between the levels of elastin expression and the density of alveolar elastic fibres in very severe COPD, suggesting that the upregulation of elastin expression may not lead to efficient repair of elastic fibres in those patients with very severe emphysema.

In conclusion, the present study shows that elastin expression is highly upregulated in very severe COPD, raising the possibility of a repair process in very severe COPD. The efficiency of this potential repair mechanism and its regulation remain to be demonstrated in the context of very severe COPD.

SUPPORT STATEMENT

Grants were received from the National Institutes of Health (Bethesda, MD, USA; P50 HL084922) for R.A. Pierce and J.C. Woods, the Barnes-Jewish Hospital Foundation (St Louis, MO, USA; 6158-01) for J.C. Woods, and the Canadian Institute for Health Research (Ottawa, ON, Canada; 7246) for J.C. Hogg. G. Deslee received grants for post-doctoral training from the University and CHU of Reims, L'Association Régionale pour l'Aide aux Insuffisants Respiratoire de Champagne Ardenne (both Reims, France), College des Professeurs de Pneumologie and AstraZeneca (Paris, France).

STATEMENT OF INTEREST

A statement of interest for G. Deslee can be found at www.erj.ersjournals.com/misc/statements.dtl

REFERENCES

1 Shapiro SD. The pathogenesis of emphysema: the elastase:anti-elastase hypothesis 30 years later. *Proc Assoc Am Physicians* 1995; 107: 346–352.
2 Kuhn C 3rd, Starcher BC. The effect of lathyrogens on the evolution of elastase-induced emphysema. *Am Rev Respir Dis* 1980; 122: 453–460.
3 Shapiro SD, Endicott SK, Province MA, *et al.* Marked longevity of human lung parenchymal elastic fibers deduced from prevalence of D-aspartate and nuclear weapons-related radiocarbon. *J Clin Invest* 1991; 87: 1828–1834.
4 Black PN, Ching PS, Beaumont B, *et al.* Changes in elastic fibres in the small airways and alveoli in COPD. *Eur Respir J* 2008; 31: 998–1004.
5 Merrilees MJ, Ching PS, Beaumont B, *et al.* Changes in elastin, elastin binding protein and versican in alveoli in chronic obstructive pulmonary disease. *Respir Res* 2008; 9: 41.
6 Vlahovic G, Russell ML, Mercer RR, *et al.* Cellular and connective tissue changes in alveolar septal walls in emphysema. *Am J Respir Crit Care Med* 1999; 160: 2086–2092.
7 Pauwels RA, Buist AS, Ma P, *et al.* Global strategy for the diagnosis, management, and prevention of chronic obstructive pulmonary disease: National Heart, Lung, and Blood Institute and World Health Organization Global Initiative for Chronic Obstructive Lung Disease (GOLD): executive summary. *Respir Care* 2001; 46: 798–825.
8 Woods JC, Yablonskiy DA, Choong CK, *et al.* Long-range diffusion of hyperpolarized ^{3}He in explanted normal and emphysematous human lungs *via* magnetization tagging. *J Appl Physiol* 2005; 99: 1992–1997.
9 Woods JC, Choong CK, Yablonskiy DA, *et al.* Hyperpolarized ^{3}He diffusion MRI and histology in pulmonary emphysema. *Magn Reson Med* 2006; 56: 1293–1300.
10 Fazio MJ, Olsen DR, Kauh EA, *et al.* Cloning of full-length elastin cDNAs from a human skin fibroblast recombinant cDNA library:

further elucidation of alternative splicing utilizing exon-specific oligonucleotides. *J Invest Dermatol* 1988; 91: 458–464.
11 Weibel ER. Stereologic Methods. London, Academic Press, 1988.
12 Howard C, Reed M. Unbiased Stereology; Three dimensional measurements in microscopy. Biosciences Scientific Publishers in association with the Royal Microscopic Society. New York, Springer Verlag, 1998.
13 Starcher BC, Mecham RP. Desmosine radioimmunoassay as a means of studying elastogenesis in cell culture. *Connect Tissue Res* 1981; 8: 255–258.
14 Gevenois PA, De Vuyst P, Sy M, *et al.* Pulmonary emphysema: quantitative CT during expiration. *Radiology* 1996; 199: 825–829.
15 Tuder RM, Yoshida T, Arap W, *et al.* State of the art cellular and molecular mechanisms of alveolar destruction in emphysema: an evolutionary perspective. *Proc Am Thorac Soc* 2006; 3: 503–510.
16 Tuder RM, Yoshida T, Fijalkowka I, *et al.* Role of lung maintenance program in the heterogeneity of lung destruction in emphysema. *Proc Am Thorac Soc* 2006; 3: 673–679.
17 Botney M, Kaiser L, Cooper J, *et al.* Extracellular matrix protein gene expression in atherosclerotic hypertensive pulmonary arteries. *Am J Pathol* 1992; 140: 357–364.
18 Shifren A, Mecham RP. The stumbling block in lung repair of emphysema: elastic fiber assembly. *Proc Am Thorac Soc* 2006; 3: 428–433.
19 Urban Z, Gao J, Pope FM, *et al.* Autosomal dominant cutis laxa with severe lung disease: synthesis and matrix deposition of mutant tropoelastin. *J Invest Dermatol* 2005; 124: 1193–1199.
20 Kasahara Y, Tuder RM, Cool CED, *et al.* Endothelial cell death and decreased expression of vascular endothelial growth factor and vascular endothelial growth factor receptor 2 in emphysema. *Am J Respir Crit Care Med* 2001; 163: 737–744.
21 Calabrese F, Giacometti C, Beghe B, *et al.* Marked alveolar apoptosis/proliferation imbalance in end-stage emphysema. *Respir Res* 2005; 6: 14.
22 Elias JA, Kang MJ, Crouthers K, *et al.* State of the art mechanistic heterogeneity in chronic obstructive pulmonary disease: insights from transgenic mice. *Proc Am Thorac Soc* 2006; 3: 494–498.