

Word count: abstract 200, text 3,293

Hemosiderin-laden Macrophages in the BAL Fluid of Patients with Diffuse Alveolar Damage

Fabien Maldonado, M.D.*, Joseph G. Parambil, M.D.*, Eunhee S. Yi, M.D.[†],

Paul A. Decker, M.S.[‡], and Jay H. Ryu, M.D.*

* Division of Pulmonary and Critical Care Medicine, Mayo Clinic, Rochester, MN

[†] Department of Laboratory Medicine and Pathology, Mayo Clinic, Rochester, MN

[‡] Division of Biostatistics, Mayo Clinic, Rochester, MN

Running head: Diffuse Alveolar Damage

Funding: None

Address all correspondences to: Jay H. Ryu, M.D., Division of Pulmonary and Critical
Care Medicine, Desk East 18, Mayo Clinic, 200 1st St. SW, Rochester, MN 55905

Phone: 507-284-2447

Fax: 507 266-4372

E-mail: ryu.jay@mayo.edu

ABSTRACT (word count: 200)

Quantification of hemosiderin-laden macrophages in the bronchoalveolar lavage fluid (BALF) has been used to diagnose diffuse alveolar hemorrhage (DAH) but has not been assessed in patients with diffuse alveolar damage (DAD).

The current study analyzed BALF obtained in 21 patients with DAD diagnosed by surgical lung biopsy.

The median age of 21 patients with DAD was 68 years (range, 18 to 79 years) and 14 (67%) were men; 12 patients (57%) were immunocompromised. The median percentage of hemosiderin-laden macrophages in the BALF was 5% (range, 0 to 90%), but was $\geq 20\%$ in 7 patients (33%), fulfilling the commonly used BALF criterion for DAH. There was a trend toward a positive correlation between the percentage of hemosiderin-laden macrophages in the BALF and parenchymal hemorrhage assessed semiquantitatively on histopathologic analysis. Patients with $\geq 20\%$ hemosiderin-laden macrophages in the BALF had a significantly increased mortality rate ($p = 0.047$) compared to those with $< 20\%$.

In patients with an acute onset of diffuse lung infiltrates and respiratory distress, $\geq 20\%$ hemosiderin-laden macrophages in the BALF can occur with DAD, and is not necessarily diagnostic of DAH. The finding of $\geq 20\%$ hemosiderin-laden macrophages in the BALF is associated with a worse prognosis in patients with DAD.

Key words:

alveolar macrophages, acute lung injury, bronchoalveolar lavage, hemosiderin

Abbreviations:

ARDS = acute respiratory distress syndrome

BALF = bronchoalveolar lavage fluid

CT = computed tomography

DAD = diffuse alveolar damage

DAH = diffuse alveolar hemorrhage

P_aO_2/F_iO_2 = ratio of partial pressure of oxygen in the arterial blood to inspired oxygen fraction

P_aCO_2 = partial pressure of carbon dioxide in the arterial blood

INTRODUCTION

Diffuse alveolar hemorrhage (DAH) is a potentially life-threatening syndrome defined by diffuse alveolar bleeding resulting from injury to the pulmonary microcirculation, such as an immune-mediated capillaritis [1-7]. DAH can be associated with various underlying disorders, including connective-tissues disorders, systemic vasculitides, drugs, infections, and bone marrow or solid organ transplantation [1-7]. Patients with DAH usually present with dyspnea and diffuse lung infiltrates, but overt indication of bleeding, i.e., hemoptysis, is not always present [4, 6].

Because DAH is clinically occult in some patients, bronchoalveolar lavage (BAL) has been used in diagnosing this condition, particularly in patients at excessive risk for surgical lung biopsy, e.g., thrombocytopenic or unstable patients. Several criteria based on BAL data have been proposed for diagnosing alveolar hemorrhage [8-12]. Perhaps the most commonly employed BAL criterion is the presence of 20% or more hemosiderin-laden macrophages in the BAL fluid (BALF) [12]. This percentage of hemosiderin-laden macrophages correlates well with the traditional Golde score [8, 9], a semi-quantitative method of assessing the hemosiderin content of alveolar macrophages, and has been used as the diagnostic criterion of DAH in recent studies [12-14].

Diffuse alveolar damage (DAD) is a histopathologic pattern of lung injury, and is the pathologic correlate in most patients with acute respiratory distress syndrome (ARDS)[15-18]. Early DAD manifests an acute exudative phase that is characterized by interstitial edema, epithelial necrosis and sloughing, the presence of fibrinous exudates in alveolar air spaces, and hyaline membrane formation. In the later organizing phase, resorption of hyaline membranes and intra-alveolar exudates occurs accompanied by

proliferation of type II pneumocytes along the alveolar walls, and proliferation of fibroblasts in the interstitium as well as in the airspaces [18, 19].

In this study, we examined the issue of whether increased numbers of hemosiderin-laden macrophages can be found in the BALF of patients with DAD, and to correlate this finding with the clinico-pathologic features.

MATERIAL AND METHODS

Study subjects

Using a computer-assisted search, we identified 58 patients with DAD identified on surgical lung biopsy seen at our institution over a 7-year period, January 1, 1996 through December 31, 2002. This cohort of 58 patients was described in a previous publication [20]. Twenty-one of these patients (36%) had undergone BAL pre-operatively, and had the BALF analyzed for hemosiderin-laden macrophages. This subset of patients formed the study group. The Mayo Foundation Institutional Review Board approved this study.

Lung Biopsy

Surgical lung biopsy was obtained by limited thoracotomy in 13 cases (62%) and by video-assisted thoracoscopic surgery (VATS) in 8 cases (38%). All biopsy slides were reviewed by one of us (E.S.Y.), an experienced pulmonary pathologist, to confirm the diagnosis of DAD, and to quantify the amount of parenchymal hemorrhage and hemosiderosis, without knowledge of correlative clinical or radiological information. Parenchymal hemorrhage was histologically graded from 0 to 3 (0: absence of intra-alveolar red blood cells, 1: questionable DAH, presence of red blood cells, but little or no

fibrin, 2: intra-alveolar red blood cells and fibrin present, and 3: intra-alveolar red blood cells and fibrin present in large amounts). Hemosiderosis was assessed and graded 0 to 3 in a similar fashion (0: no hemosiderin present, 1: questionable hemosiderosis without definite hemosiderin present, 2: hemosiderin present, and 3: hemosiderin present in large amounts).

Bronchoscopy

Fiberoptic bronchoscopy was performed as previously described [21]. Sequential infusions of 20 ml aliquots of 0.9% sodium chloride solution at 37°C were promptly aspirated with suction set at 80 mmHg, and collected until a total volume of 40 ml of BAL effluent was obtained. A sample of fluid was used for bacteriologic, virologic, and fungal studies. The remaining fluid was used for cell counts and cytologic examination. Transbronchoscopic lung biopsies were performed in 4 patients (19%).

Detection of Hemosiderin-laden Macrophages in BALF

Examination of BALF for hemosiderin-laden macrophages was performed as follows. After centrifugation (Cytospin, Shandon Southern Instruments, Cheshire, England) at 500 revolutions per minute for 10 minutes, a cell pellet was obtained. Perl's Prussian blue stain was used to detect hemosiderin-laden macrophages. For this purpose, air-dried slides were incubated for 10 minutes in a stain containing hydrochloric acid and potassium ferricyanide, and then counterstained with eosin and Mayer's hemalum. At a magnification of 500X, at least 200 alveolar macrophages were examined for the number of cells that stained with Perl's Prussian blue stain, and a percentage score was

established by dividing the number of Prussian blue-positive cells by the total number of cells counted.

Statistical analysis

Data are summarized using median, range or mean \pm standard deviation (SD) for continuous variables, and number, percent for categorical variables. Comparisons were performed using the Fisher exact test for categorical variables, and the two-sample rank sum test for continuous variables. Correlation between continuous variables was assessed using Pearson's correlation coefficient. In all cases, two-tailed p values of 0.05 or less were considered statistically significant.

RESULTS

Demographic and Clinical Features

The median age of the 21 patients was 66 years (range, 18 years to 79 years); 14 (67%) were men (**Table 1**). Eleven patients (52%) had a smoking history, and 12 patients (57%) were immunocompromised. The causes for immunocompromised state were hematopoietic stem cell (4 patients) or solid organ (1 patient) transplantation, chemotherapy treatment for malignancy (2 patients), and immunosuppressive therapy for connective tissue disorders (4 patients) or chronic hypersensitivity pneumonitis (1 patient).

All patients presented acutely with dyspnea, and were admitted to the hospital. Other symptoms at presentation included cough (57%), fever (29%), and hemoptysis (14%). Inspiratory crackles were heard in 19 patients (90%); clubbing was absent. At

the time of surgical lung biopsy, 16 patients (76%) were on invasive mechanical ventilation with lung protective strategies; the remaining 5 patients (24%) were on noninvasive positive pressure ventilation.

All patients had peripheral blood analyzed for complete blood cell counts and coagulation parameters at initial presentation and serially during the course of their hospitalization. The mean hemoglobin on initial evaluation was 10.6 ± 1.6 g/dl (mean \pm SD), mean leukocyte count $11.1 \pm 7.3 \times 10^3$ cells/ μ l, and the mean platelet count was $177 \pm 96 \times 10^3$ cells/ μ l.

On the day of surgical lung biopsy, the mean ratio of partial pressure of oxygen in the arterial blood to inspired oxygen fraction (P_aO_2/F_iO_2) was 143.2 ± 64.7 . The mean partial pressure of carbon dioxide in the arterial blood (P_aCO_2) was 38.2 ± 9.2 mmHg and mean arterial pH was 7.43 ± 0.07 .

Chest Radiography and Computed Tomography

Mixed alveolar-interstitial infiltrates were seen bilaterally on chest radiographs of all 21 patients. Pleural effusions were seen in two patients (10%), bilateral in one patient and unilateral in the other.

Computed tomography (CT) of the chest was available on all patients, and revealed a combination of consolidation and ground glass opacities bilaterally in all patients. Other findings included pleural effusions in four patients (19%) that were all small in size. One patient underwent a CT angiogram which was negative for pulmonary embolism.

Analysis of BALF

BAL was performed prior to surgical lung biopsy in all patients after a median interval of 10 days (range, 3 to 43 days) following the onset of symptoms, and a median interval of 4 days (range, 0 to 29 days) before the surgical lung biopsy. Bronchoscopic inspection of the airways did not demonstrate gross bleeding in any patient. However, the BAL fluid was “blood-tinged” or pink in 10 patients (48%). In 2 of these patients (central venous catheter-related sepsis and idiopathic pneumonia syndrome, respectively), BAL return was initially clear, then became blood-tinged on sequential aliquots.

The median percentage of hemosiderin-laden macrophages in the BALF was 5% (range, 0 to 90%) (**Figure 1**). The percentage of hemosiderin-laden macrophages was $\geq 20\%$ in 7 patients (33%), fulfilling the BALF criterion for the diagnosis for DAH. Four of 10 patients with blood-tinged BALF had $\geq 20\%$ hemosiderin-laden macrophages. In the remaining 6 patients with blood-tinged BALF, the percentage of hemosiderin-laden macrophages ranged from 0% to 15%.

On differential cell count, neutrophils were the predominant cell type identified in the BAL fluid with a mean percentage of 46.5 ± 23.9 . Macrophages, lymphocytes, and eosinophils accounted for 39.8 ± 24.3 , 11.5 ± 9.2 , and 2 ± 2.6 percent of cells recovered by BAL, respectively. There was a significant negative correlation between the percentage of hemosiderin-laden macrophages and the percentage of neutrophils in the BALF (Pearson’s correlation coefficient $r=-0.62$, $p=0.003$). There was a positive correlation between the percentage of hemosiderin-laden macrophages and total percentage of macrophages in the BALF (Pearson’s correlation coefficient $r=0.64$, $p=0.002$).

Transbronchoscopic lung biopsies were performed in 4 patients (19%).

Histopathologic examination of these biopsy specimens revealed features of organizing pneumonia in one patient, diffuse alveolar damage in one patient, and were nondiagnostic in the remaining two patients.

Surgical Lung Biopsy

Surgical lung biopsy was performed to clarify the etiology of persistent lung infiltrates and associated respiratory insufficiency. Histopathologic features of DAD were demonstrated in all patients. The median interval from initial presentation to surgery was 12 days (range, 3 to 56 days). Lung specimens were obtained by limited thoracotomy in 13 patients (62%), and by video-assisted thoracoscopic surgery in 8 patients (38%). None of the patients had evidence of pulmonary capillaritis. Four of 21 patients showed areas of grade 3 hemorrhage, which involved relatively limited patchy foci. Three of 21 cases revealed grade 3 hemosiderosis, which was seen in only a few small areas as well. Additional histopathologic findings included superimposed acute bronchopneumonia (4 patients), usual interstitial pneumonia (3 patients), amyloid (1 patient), and necrotizing granulomas (1 patient).

There was no statistically significant correlation between the percentage of hemosiderin-laden macrophages in the BALF and semiquantitative assessment of parenchymal hemosiderosis on histopathologic analysis ($r = 0.16$, $p = 0.487$). Although not statistically significant, there was a trend toward a positive correlation between the percentage of hemosiderin-laden macrophages in the BALF and semiquantitative assessment of parenchymal hemorrhage on histopathologic analysis ($r = 0.42$, $p = 0.061$).

Causes of DAD

The underlying cause of DAD was identifiable in 17 patients (81%) and included infections in 5 patients (24%), drug-induced pulmonary toxicity in 4 patients (19%), idiopathic pulmonary fibrosis in 3 patients (“acute exacerbation”, 14%), non-infectious pulmonary complications of hematopoietic stem-cell or solid organ transplantation in 3 patients (14%), and chronic hypersensitivity pneumonitis in 1 patient (5%). The remaining patient had mixed connective tissue disease which was thought to be the cause of DAD. In 4 cases (14%), the underlying cause was not directly identifiable, i.e., acute interstitial pneumonia.

Subset Analysis of 7 Patients with $\geq 20\%$ Hemosiderin-laden Macrophages in BALF

As already noted, 7 patients had $\geq 20\%$ hemosiderin-laden macrophages in the BALF with the value ranging from 22% to 90% (median, 25%). The underlying causes of DAD and correlative findings of these 7 patients are listed in **Table 2**. One of these patients (74 year-old male) had been on chronic anticoagulant therapy for a prosthetic mitral valve; anticoagulant therapy was discontinued 2 days before bronchoscopy with prothrombin time international normalized ratio of 1.6 on the day of BAL. Two other patients (57 year-old male and 75-year-old male) were thrombocytopenic with platelet counts of $36 \times 10^9/L$ and $67 \times 10^9/L$, respectively on the day of BAL. These 3 patients accounted for those with the highest hemosiderin-laden macrophage percentages. However, 2 of 14 patients with $<20\%$ hemosiderin-laden macrophages in the BALF were

also thrombocytopenic (platelets $<50 \times 10^9/L$) at the time of their BAL. No other patient was known to have any bleeding diathesis.

Comparison of these 7 patients with 14 remaining patients who had $<20\%$ hemosiderin-laden macrophages in the BALF revealed no difference in the interval between onset of symptoms and bronchoscopy or surgical lung biopsy. All 7 patients with $\geq 20\%$ hemosiderin-laden macrophages in the BALF died during their hospitalization versus only 7 (50%) of those with $<20\%$ hemosiderin-laden macrophages, a difference that was statistically significant ($p = 0.047$, Fisher's exact test).

DISCUSSION

In this study of 21 patients with DAD diagnosed by surgical lung biopsy, one-third had $\geq 20\%$ hemosiderin-laden macrophages in the BALF, a criterion commonly used to diagnose DAH [12-14, 22]. Our findings suggest that the diagnosis of DAH that is based on the percentage of hemosiderin-laden macrophages in the BALF may be inaccurate. This is problematic since clinical presentation and radiologic features for DAD and DAH are similar [23].

DAH is histologically characterized by widespread intraalveolar hemorrhage that could be both acute and chronic. The vast majority of cases of DAH are thought to be secondary to capillaritis from immune or non-immune causes [1, 4-7, 24]. Although often regarded as synonymous with DAH, capillaritis is a pathological diagnosis defined by the presence of neutrophils infiltrating the capillary walls with occasional fibrinoid necrosis of the alveolar wall and secondary destruction of the lung architecture [1, 5]. Bland pulmonary hemorrhage (without capillaritis) may also result in DAH and most

often results from blood dyscrasias [5]. Other conditions associated with pulmonary hemorrhage such as Goodpasture's syndrome and systemic lupus erythematosus usually do not show significant pulmonary capillaritis. In such cases, the pathologic findings may resemble DAD, especially in exudative phase. Conversely, DAD may be associated with increased intraalveolar red blood cells, fibrin and hemosiderin that could occasionally mimic DAH. The absence of capillaritis could be helpful, but careful clinical correlation may be needed to distinguish DAD from DAH without capillaritis in some cases.

Several bronchoscopic diagnostic criteria have been proposed in the diagnosis of DAH but have not been systematically validated against pathological data [8, 10-12]. Surgical biopsy examination is considered the gold standard but is often impractical. Clues to true alveolar hemorrhage include the presence of hemosiderin in the interstitium, fibrin entangled with red blood cells and hemosiderin-laden macrophages [5]. The mere presence of intra-alveolar red blood cells is not diagnostic as it may result from surgical trauma, as is often the case in bronchoscopic lung biopsies.

Bronchoscopic alveolar lavage has been accepted as a minimally invasive procedure to establish the diagnosis of DAH [12-14]. Golde and colleagues[8] described the Golde score which assigned a rank to the hemosiderin content of alveolar macrophages based on a subjective estimate after examining 200 alveolar macrophages using the following scale; 0 = no color, 1 = faint blue in one portion of the cytoplasm, 2 = deep blue in a minor portion of the cell, 3 = deep blue in most areas of the cytoplasm, and 4 = deep blue throughout the cell. The total score on 200 cells was divided by 2 to obtain a hemosiderin score for an average of 100 alveolar macrophages. A Golde score greater

than 100 was considered severe DAH, while a Golde score between 20 to 100 was considered mild to moderate DAH. This original study consisted of five leukemic patients, one of whom had histopathologic confirmation (autopsy) of pulmonary hemorrhage.

DeLassence and colleagues [12] noted a close correlation between the Golde score and the percentage of hemosiderin-laden macrophages in the BAL fluid identified by Perl's Prussian blue staining and suggested the use of this percentage since it was easier to perform. Thus, a percentage of hemosiderin-laden macrophages $\geq 20\%$ is commonly regarded as diagnostic of DAH, however direct correlation to histopathology data has been lacking.

DAD is a relatively common histopathologic finding on lung biopsy or at autopsy [15] [17] [20]. It is the most common histology seen in patients with acute respiratory distress syndrome (ARDS) [15, 17]. DAD represents an evolving process of severe injury to the alveolar-capillary units [15, 17]. In particular, earlier exudative phase is associated with interstitial and alveolar edema resulting from disrupted integrity of the alveolar-capillary structures. Hyaline membranes form and intra-alveolar hemorrhage can be seen. In addition, microthrombi as well as larger thromboemboli and hemorrhagic infarcts are commonly seen in patients with DAD [15, 17]. Thus, it is not unexpected that DAD can be associated with increased numbers of hemosiderin-laden macrophages in the BAL fluid.

Nearly all (95%) of our patients with DAD had BAL neutrophilia ($>3\%$ neutrophils). This is consistent with the underlying process of acute lung injury. We also noted the percentage of hemosiderin-laden macrophages to correlate in a positive manner with the

total percentage of BAL macrophages, and negatively with the percentage of BAL neutrophils. Macrophages are thought to play an important role in the progression of DAD towards the fibroproliferative phase, and intra-alveolar neutrophils have been associated with membrane repair and remodeling [18, 19]. Since the number of our study subjects was relatively small, it is unclear whether these correlations represent a valid observation or not. Perhaps one would have expected results opposite from that observed here, i.e. a positive correlation between the percentage of hemosiderin-laden macrophages and the percentage of neutrophils, if the latter is reflective of the underlying inflammatory activity and alveolar-capillary injury. Another potential confounder in attempting to make sense of these correlations is the fact that BAL was performed at different time points in the evolving process of DAD.

We noted no significant correlation between BAL findings and hemorrhage and hemosiderin scores as determined on surgical biopsy specimen. One possible explanation for this is the varying interval between bronchoscopic sampling and surgical biopsy among these 21 patients which may have obscured the correlation in the temporally evolving process of DAD [25, 26]. The site of surgical lung biopsy was, in some cases, different from the lobe in which BAL was performed. We suspect that the degree of parenchymal hemorrhage present on lung biopsy would have better correlated with the percentage of hemosiderin-laden macrophages in the BALF if BAL had been performed near the time of surgical lung biopsy and in the same location. This inconsistency in the location and timing of BALF and lung biopsy also likely contributed to lack of correlation between the percentage of hemosiderin-laden macrophages in the BALF and semiquantitative assessment of parenchymal hemosiderosis on histopathologic analysis.

Complete clearance of hemosiderin from the lung has been observed to occur within 2 to 4 weeks after acute pulmonary hemorrhage [12, 25]. A larger and prospective study with a design addressing these shortcomings is needed to further clarify this issue.

Our results suggest that increased percentage of hemosiderin-laden macrophages in the BALF may have prognostic significance as all patients with $\geq 20\%$ hemosiderin-laden macrophages died during their hospitalization. This correlation is likely due to higher percentages of hemosiderin-laden macrophages reflecting more extensive acute lung injury. In this regard, it is interesting to note that Abu-Farsakh and colleagues noted better prognosis to be associated with absence of hemosiderin-laden macrophages in the BALF among bone marrow transplant patients [27].

Our study has limitations due to its retrospective nature and limited number of patients. However, our results raise important questions that should be addressed in larger prospective studies. Based on our data, it appears that DAD could be mistaken for DAH when the latter diagnosis is based on the percentage of hemosiderin-laden macrophages in the BAL fluid. Coexisting bleeding diathesis, such as thrombocytopenia or recent anticoagulant therapy, may contribute to elevating the percentage of hemosiderin-laden macrophage in the BALF of patients with DAD, as seen in 3 of our patients with the highest counts. Corticosteroid therapy is commonly employed in the management of patients with DAH but its role in the treatment of DAD remains unclear. In spite of fairly extensive data on the use of corticosteroids in ARDS in the literature, no consensus in their role has been established. Although they may offer benefit in some specific clinical contexts, they could be potentially harmful in others [28, 29]. Thus, accurate diagnostic separation of DAH and DAD may have management implications.

In conclusion, our results suggest that increased percentage of hemosiderin-laden macrophages in the BAL fluid can be seen in patients with DAD, and is not specific for DAH. Patients with $\geq 20\%$ hemosiderin-laden macrophages in the BAL fluid have a worse prognosis compared those with $<20\%$. Further studies analyzing the diagnostic and prognostic implications of BAL results in patients with DAD are warranted.

REFERENCES

1. Green RJ, Ruoss SJ, Kraft SA, Duncan SR, Berry GJ, Raffin TA. Pulmonary capillaritis and alveolar hemorrhage. Update on diagnosis and management. *Chest* 1996; 110(5): 1305-1316.
2. Dweik RA, Arroliga AC, Cash JM. Alveolar hemorrhage in patients with rheumatic disease. *Rheumatic diseases clinics of North America* 1997; 23(2): 395-410.
3. Zamora MR, Warner ML, Tudor R, Schwarz MI. Diffuse alveolar hemorrhage and systemic lupus erythematosus. Clinical presentation, histology, survival, and outcome. *Medicine* 1997; 76(3): 192-202.
4. Specks U. Diffuse alveolar hemorrhage syndromes. *Current opinion in rheumatology* 2001; 13(1): 12-17.
5. Colby TV, Fukuoka J, Ewaskow SP, Helmers R, Leslie KO. Pathologic approach to pulmonary hemorrhage. *Annals of diagnostic pathology* 2001; 5(5): 309-319.
6. Schwarz MI, Fontenot AP. Drug-induced diffuse alveolar hemorrhage syndromes and vasculitis. *Clinics in chest medicine* 2004; 25(1): 133-140.
7. Collard HR, Schwarz MI. Diffuse alveolar hemorrhage. *Clinics in chest medicine* 2004; 25(3): 583-592, vii.
8. Golde DW, Drew WL, Klein HZ, Finley TN, Cline MJ. Occult pulmonary haemorrhage in leukaemia. *British medical journal* 1975; 2(5964): 166-168.
9. Finley TN, Aronow A, Cosentino AM, Golde DW. Occult pulmonary hemorrhage in anticoagulated patients. *The American review of respiratory disease* 1975; 112(1): 23-29.

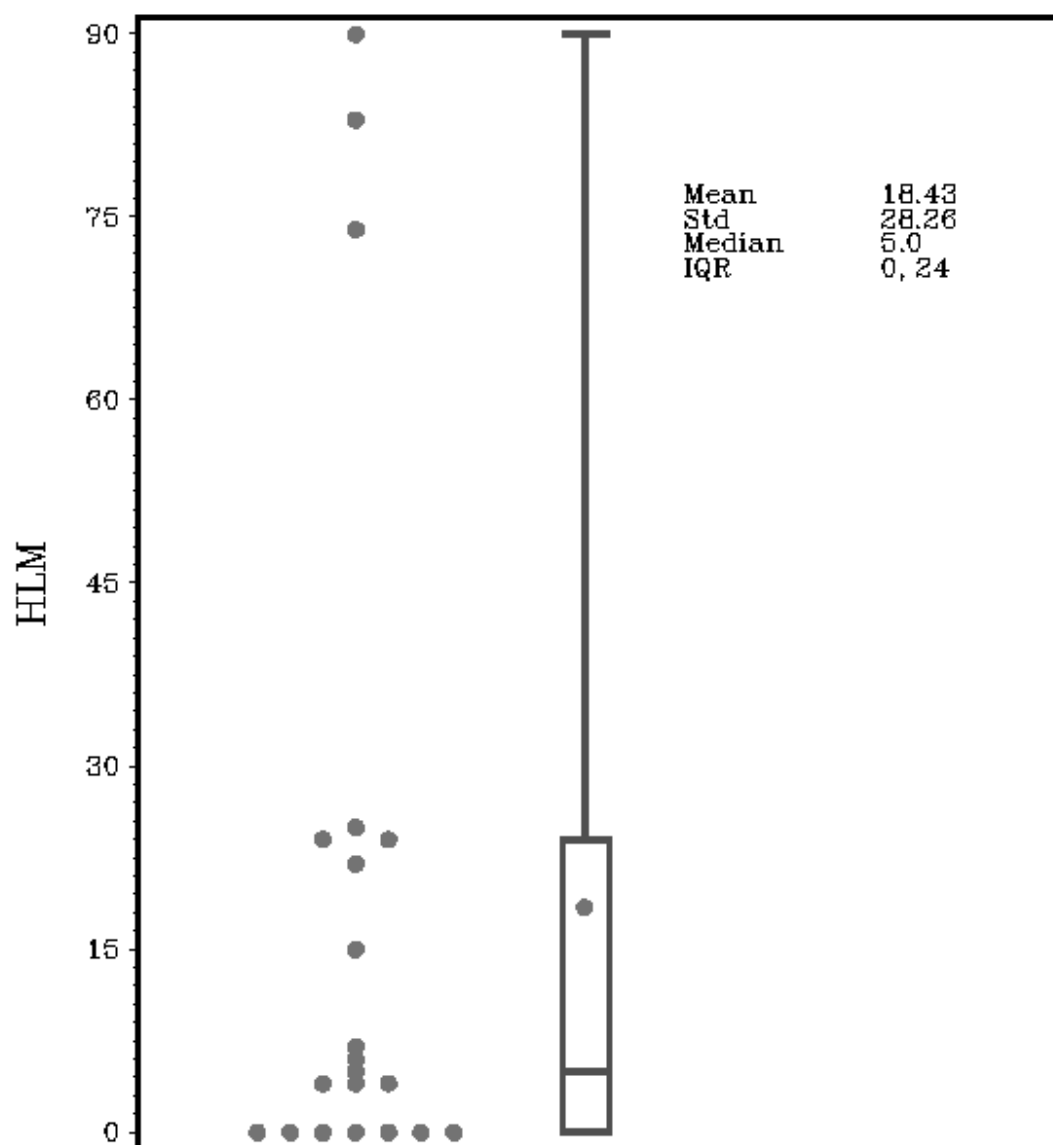
10. Grebski E, Hess T, Hold G, Speich R, Russi E. Diagnostic value of hemosiderin-containing macrophages in bronchoalveolar lavage. *Chest* 1992; 102(6): 1794-1799.
11. Kahn FW, Jones JM, England DM. Diagnosis of pulmonary hemorrhage in the immunocompromised host. *The American review of respiratory disease* 1987; 136(1): 155-160.
12. De Lassence A, Fleury-Feith J, Escudier E, Beaune J, Bernaudin JF, Cordonnier C. Alveolar hemorrhage. Diagnostic criteria and results in 194 immunocompromised hosts. *American journal of respiratory and critical care medicine* 1995; 151(1): 157-163.
13. Lauque D, Cadranel J, Lazor R, Pourrat J, Ronco P, Guillevin L, Cordier JF. Microscopic polyangiitis with alveolar hemorrhage. A study of 29 cases and review of the literature. Groupe d'Etudes et de Recherche sur les Maladies "Orphelines" Pulmonaires (GERM"O"P). *Medicine* 2000; 79(4): 222-233.
14. Afessa B, Tefferi A, Litzow MR, Krowka MJ, Wylam ME, Peters SG. Diffuse alveolar hemorrhage in hematopoietic stem cell transplant recipients. *American journal of respiratory and critical care medicine* 2002; 166(5): 641-645.
15. Tomashefski JF, Jr. Pulmonary pathology of acute respiratory distress syndrome. *Clinics in chest medicine* 2000; 21(3): 435-466.
16. Esteban A, Fernandez-Segoviano P, Frutos-Vivar F, Aramburu JA, Najera L, Ferguson ND, Alia I, Gordo F, Rios F. Comparison of clinical criteria for the acute respiratory distress syndrome with autopsy findings. *Annals of internal medicine* 2004; 141(6): 440-445.
17. Castro CY. ARDS and diffuse alveolar damage: a pathologist's perspective. *Semin Thorac Cardiovasc Surg* 2006; 18(1): 13-19.

18. Dos Santos CC. Advances in mechanisms of repair and remodelling in acute lung injury. *Intensive Care Med* 2008.
19. Dechert RE. The pathophysiology of acute respiratory distress syndrome. *Respir Care Clin N Am* 2003; 9(3): 283-296, vii-viii.
20. Parambil JG, Myers JL, Aubry MC, Ryu JH. Causes and prognosis of diffuse alveolar damage diagnosed on surgical lung biopsy. *Chest* 2007; 132(1): 50-57.
21. Cordonnier C, Bernaudin JF, Fleury J, Feuilhade M, Haïoun C, Payen D, Huet Y, Atassi K, Vernant JP. Diagnostic yield of bronchoalveolar lavage in pneumonitis occurring after allogeneic bone marrow transplantation. *The American review of respiratory disease* 1985; 132(5): 1118-1123.
22. Costabel U, Guzman J. Bronchoalveolar lavage in interstitial lung disease. *Current opinion in pulmonary medicine* 2001; 7(5): 255-261.
23. Schwarz MI, Albert RK. "Imitators" of the ARDS: implications for diagnosis and treatment.[see comment]. *Chest* 2004; 125(4): 1530-1535.
24. Travis WD, Colby TV, Lombard C, Carpenter HA. A clinicopathologic study of 34 cases of diffuse pulmonary hemorrhage with lung biopsy confirmation. *The American journal of surgical pathology* 1990; 14(12): 1112-1125.
25. Sherman JM, Winnie G, Thomassen MJ, Abdul-Karim FW, Boat TF. Time course of hemosiderin production and clearance by human pulmonary macrophages. *Chest* 1984; 86(3): 409-411.
26. Epstein CE, Elidemir O, Colasurdo GN, Fan LL. Time course of hemosiderin production by alveolar macrophages in a murine model. *Chest* 2001; 120(6): 2013-2020.

27. Abu-Farsakh HA, Katz RL, Atkinson N, Champlin RE. Prognostic factors in bronchoalveolar lavage in 77 patients with bone marrow transplants. *Acta cytologica* 1995; 39(6): 1081-1088.
28. Steinberg KP, Hudson LD, Goodman RB, Hough CL, Lanken PN, Hyzy R, Thompson BT, Ancukiewicz M. Efficacy and safety of corticosteroids for persistent acute respiratory distress syndrome. *N Engl J Med* 2006; 354(16): 1671-1684.
29. Peter JV, John P, Graham PL, Moran JL, George IA, Bersten A. Corticosteroids in the prevention and treatment of acute respiratory distress syndrome (ARDS) in adults: meta-analysis. *BMJ* 2008; 336(7651): 1006-1009.

Figure Legends

Figure 1. Dot plot showing the percentage of hemosiderin-laden macrophages in bronchoalveolar lavage fluid from 21 patients with diffuse alveolar damage.



Std = standard deviation

IQR = interquartile range

Table 1. Epidemiologic Aspects of 21 Subjects with Diffuse Alveolar Damage

Characteristic	Value
Age - yr.	
Mean	60.9 \pm 14.9
Median	66
Range	18 – 79
Sex – no. (%)	
Female	7 (33)
Male	14 (66)
Smoking history – no. (%)	
Current	10 (48)
Previous	1(5)
Never	9 (43)
Immunocompromised hosts – no. (%)	12 (57%)

Table 2. Summary of 7 Patients with DAD and $\geq 20\%$ Hemosiderin-laden Macrophages in BALF

Age, Sex	Diagnosis	Site of BAL	% HLM	Interval from BAL to Biopsy (days)	Site of Surgical Lung Biopsy	Hemorrhage score
48, male	Cocaine-induced	Lingula	22	29	Left lower lobe	1+
74, male	Acute exacerbation of IPF	Right middle lobe	74	6	Left upper and lower lobes	3+
57, male	Idiopathic pneumonia syndrome (Hodgkin's disease)	Left lower lobe	83	3	Right lower lobe	2+
75, male	Herpes simplex virus type 1 pneumonia	Right upper lobe	24	4	Right upper and lower lobes	2+
75, male	Acute exacerbation of IPF	Right middle lobe	24	12	Right upper and lower lobes	2+
68, male	Central venous catheter-related sepsis (multiple myeloma)	Right middle lobe	90	3	Right upper and lower lobes	2+
68, female	Cytarabine-induced (acute myelogenous leukemia)	Right upper lobe	25	2	Right middle and lower lobes	1+