

**AGENESIS OF PARANASAL SINUSES AND NASAL NITRIC OXIDE IN PRIMARY
CILIARY DYSKINESIA**

Massimo Pifferi¹, Andrew Bush², Davide Caramella³, Maria Di Cicco¹, Marta Zangani³, Iolanda Chinellato⁴, Pierantonio Macchia¹, Attilio L Boner⁴

¹Department of Pediatrics, University of Pisa, Italy

²Imperial School of Medicine at the National Heart and Lung Institute, London, UK

³Division of Diagnostic and Interventional Radiology, University of Pisa, Pisa, Italy

⁴Department of Pediatrics, University of Verona, Italy

Correspondence and requests for reprints should be addressed to:

Massimo Pifferi MD, PhD

Department of Pediatrics

University of Pisa

Via Roma 67 56126 Pisa - Italy

Fax: ++39 50 992641

Phone: ++39 50 992728

e-mail: m.pifferi@med.unipi.it

Abstract

Background: Agenesis of paranasal sinuses was described only in case reports of patients with primary ciliary dyskinesia (PCD).

Objective: Since agenesis of paranasal sinuses may contribute to low nasal nitric oxide level, a common finding in PCD, we speculated that this condition might be frequent in PCD patients.

Methods: Patients referred for PCD evaluation were consecutively recruited for 30 months. In addition to standard diagnostic testing for PCD, CT scan of paranasal sinuses was performed in all subjects.

Results: Eighty six patients (46 children aged 8 - 17 years) were studied. PCD was diagnosed in 41 subjects and secondary ciliary dyskinesia (SCD) was diagnosed in the remaining subjects. Frontal and/or sphenoidal sinuses were either aplastic or hypoplastic in the CT scans of 30 out of 41 PCD patients (73%), but only in 17 out of 45 (38%) with SCD ($p=0.002$). There was a significant inverse correlation between the score for aplasia/hypoplasia of each paranasal sinus and nasal NO values in the PCD patients ($p=0.008$, $r=-0.432$), but not in SCD ($p=0.07$, $r=-0.271$).

Conclusions: the findings of aplasia/hypoplasia of the frontal and or sphenoidal sinuses may be part of the spectrum of PCD, and this finding should prompt exclusion of this condition.

KEYWORDS: agenesis, nasal nitric oxide, paranasal sinuses, primary ciliary dyskinesia, secondary ciliary dyskinesia

INTRODUCTION

Most exhaled breath nitric oxide (NO) originates from the upper airways. in particular from the paranasal sinuses [1], and also the nasal mucosa [2]. NO is probably important in local, upper airway host defense [1]. In patients with sinusitis, and those with primary ciliary dyskinesia (PCD), a disorder characterized by increased susceptibility to sinus infections, nasal NO levels are generally low [3, 4]. Hitherto, agenesis of paranasal sinuses was described only in case reports of patients with PCD [5]; there is no longitudinal study in a large number of patients. We hypothesised that sinus agenesis or decreased sinus pneumatization in PCD would be associated with a lower nasal NO, and worse upper and lower airway disease. The aim of this study was to assess paranasal sinus anatomy in a large series of patients with PCD and to correlate the findings with nasal NO levels and clinical manifestations of the disease.

MATERIALS AND METHODS

Subjects

86 subjects (26 with situs inversus) aged ≥ 8 years, with a clinical history and signs suggestive of PCD, were consecutively evaluated in Department of Pediatrics of the University of Pisa. A diagnosis of PCD was made on the basis of structural and/or functional ciliary abnormalities, as previously described [6-10]. In all subjects, ciliary motion analysis, ultrastructural assessment of cilia, ciliary function after ciliogenesis in culture of nasal brushing samples, and nasal NO measurements were performed, when the subject had been free from respiratory infection for at least 4 weeks. Other underlying conditions which could have been responsible for recurrent upper and lower respiratory tract infections were excluded. All patients underwent chest and sinus CT scans which were evaluated for the degree of pneumatization of each paranasal sinus and the severity and extent of local inflammation.

Informed consent for nasal brushing was obtained from each adult patient or the children's parents and the local Hospital Ethical Committee approved the study protocol.

Computed Tomographic scanning of paranasal sinuses

All patients underwent unenhanced CT scans (Multislice CT; General Electric Medical Systems, Milwaukee, MI, USA) of the sinuses and axial, sagittal and coronal images were acquired. The CT scan assessment of the degree of pneumatization of each paranasal sinus was always performed by the same radiologist (DC), blind to the results obtained by the other researchers. In our patients age ≥ 14 years (when sinus development is generally complete) [11] sinus aplasia or hypoplasia were defined according to radiological criteria recently used in adults with cystic fibrosis [12] (Tab. 1 and Fig. 1a-d) Moreover, to better evaluate the morphology of the paranasal sinuses in relation to the patients' age [11] a volumetric 3-dimensional reconstruction of the CT datasets were performed and the following scores allocated: 1 for hypoplasia, 2 for agenesis of each sinus. In consideration of the developmental stages of paranasal sinuses and in line with previous work [11] a delay in

pneumatization in children aged more than 8 years was considered as hypoplasia and a total lack of pneumatization in children aged more than 10 years as aplasia, even though the sphenoidal sinus attains its mature size only by the age of 14 years. Likewise, although the frontal sinuses achieve their final size after puberty, a delay in their pneumatization (hypoplasia) was diagnosed either if the top of the frontal sinuses was not at the level of the orbital roof by age 8 years, or if the top did not extend into the vertical portion of the frontal bone by age 10 years as previously suggested [11]. The degree of inflammation was assessed using the Lund – Mackay system [13], in which 0 is assigned to sinuses with no mucosal thickening, 2 is assigned to completely opacified sinuses, and 1 is assigned to lesser degrees of abnormality. The frontal, anterior ethmoid, maxillary, posterior ethmoid, and sphenoid sinuses as well as the ostiomeatal complex on each side is scored, with a possible maximum total score of 24. As previously reported, a modification of this system was used because of the prevalence of sinus aplasia [12]. Briefly, if a patient lacked an evaluable sinus the total score was adjusted to account for the lack of this structure. This was done by multiplying the patient's total score by the possible total 24 and dividing by the possible total for that patient (24 - 2 x number of missing structures) [12].

Computed Tomographic scanning of chest

In all patients a high resolution computed tomography (HRCT) of the chest was performed using the same scanner. Slices (1-mm thick) were obtained with 10-mm spacing (120 kV, 130 mA), in the supine position, at full inspiration. No intravenous contrast was injected and no anaesthesia was needed. All images were evaluated by the same radiologist (DC) who was blinded to the clinical data and scored using the Bhalla system [14], while bronchiectasis was identified according to standard criteria [15].

Statistical analyses

Baseline variables are described as group mean \pm SD. Nasal NO values, scores for sinus agenesis, and modified Lund – Mackay scores which were non-normally distributed were expressed as median and interquartile range. Differences between means were evaluated by the two-tailed Student's t test. Differences between medians were assessed by Mann-Whitney (Wilcoxon) W test.

Correlations between quantitative evaluation for the degree of pneumatization of each paranasal sinus or for the severity/extent of local sinus inflammation and nasal NO measurements were examined using Pearson correlation test. The same test was also applied to evaluate the correlation between sinus disease, presence of bronchiectasis, and lung impairment. The chi-squared test was used to verify the association between the complete development of paranasal sinuses and nasal NO levels > 250 ppb in PCD patients or between their agenesis and PCD diagnosis. This value was selected because it has been previously shown to have the best combination of sensitivity (97%) and specificity (90%) for the diagnosis of PCD (4).

A p-value < 0.05 was considered statistically significant.

All statistical calculations were performed using SPSS version 15.0 software for Windows (SPSS, Inc, Chicago, IL) for personal computers.

RESULTS

Of 86 subjects (42 males) studied, 46 were children [age range: 8–17 years, mean (SD) 10.7 (2.9) years] and 40 were adults [age range: 18–58 years, mean (SD) 32.0 (9.2) years]. Immunological abnormalities were excluded in all patients. No subject had CF or CF gene mutations (the 33 commonest mutations in the population were sought), and careful examination allowed the exclusion of swallowing problems and supraoesophageal complications of gastro-oesophageal reflux.

In 41 (47.7%) patients (19 children) the diagnosis of PCD was established. In 30 of these (13 children) the diagnosis was made with ciliary motion analysis (abnormal motion patterns, including immotile cilia and/or very low ciliary beat frequency) and TEM evaluation of cilia (alterations of the central pair and deficiencies of the dynein arms, associated with a small proportion of swollen cilia and compound cilia) while in the other 11 patients (6 children) the diagnosis of PCD was reached with functional ciliary evaluation after ciliogenesis in culture, when there was complete absence of either migration or rotation of spheroids. Ciliogenesis in culture was performed in patients with a highly suggestive clinical presentation, but with atypical functional and structural features.

In the remaining 45 (52 %) patients (27 children), ciliary motion analysis demonstrated abnormal patterns in a small proportion of cilia, prevalence of thick cilia and low ciliary beat frequency, compatible with secondary ciliary dyskinesia (SCD). In these 45 subjects, TEM evaluation and ciliogenesis in culture confirmed the diagnosis of SCD. These subjects served as controls. There was no significant age difference between patients with PCD (mean \pm SD: 21.3 \pm 12.6 years) and SCD (mean \pm SD: 19.4 \pm 13.0 years).

Frontal and/or sphenoidal sinuses were either aplastic or hypoplastic in the CT scans of 30 out of 41 PCD patients (73%), but only in 17 out of 45 (38%) with SCD ($p=0.002$). In the PCD patients 26 (32%) of 82 frontal sinuses were aplastic and 17 (21%) were hypoplastic. Likewise, 38 (46%) of 82

sphenoid sinuses were poorly developed, with 12 (15%) being aplastic and 26 (32%) being hypoplastic. Maxillary hypoplasia was less common, affecting 10 (12%) of 82 maxillary sinuses.

In subjects with SCD only 10 (11 %) out of 90 frontal sinuses were aplastic and 15 (17 %) were hypoplastic. Only 9 (10 %) of sphenoid sinuses were poorly developed, with 6 (7 %) being aplastic and 3 (3 %) hypoplastic, and 2 (2 %) of the maxillary sinuses were hypoplastic.

There was a significant difference ($p < 0.0001$) between the score for aplastic or hypoplastic sinuses in patients with PCD (median: 4.0; IQR: 6.0) compared with that of subjects with SCD (median: 0.0; IQR: 2.0). In neither group was there a significant correlation between the age of the patients and agenesis of paranasal sinuses.

In the PCD patients the group median nasal NO was 107.7 ppb (IQR: 231.4), but 10 of 41 (24%) had a nasal NO > 250 ppb (median: 498.2 ppb; IQR: 482.9, range between 290 and 1000 ppb). In the PCD group twelve patients had specific IgE to one or more perennial allergens (cat, dog, house dust mites) and/or seasonal allergens (tree, grass pollens, *Parietaria officinalis*) and of these only 3 subjects had a nNO > 250 ppb suggesting that in these patients high nNO is not driven by the atopic status. Three patients had nasal polyposis and all had nNO < 250 ppb.

The SCD group had significantly different nasal NO values (median: 685.0 ppb; IQR: 520.2, $p < 0.0000001$); 10 out of 45 (22 %) had nasal NO < 250 ppb (median: 109.7 ppb; IQR: 74.1) with a range between 31 and 202 ppb. In this group sixteen subjects were allergic, seven had nasal polyposis, which was associated with severe sinusitis in two subjects who also had nNO < 250 ppb.

There was a significant inverse correlation between the score for aplasia/hypoplasia of each paranasal sinus and nasal NO values in the PCD patients ($p = 0.008$, $r = -0.432$) (Fig. 2), but not in SCD ($p = 0.07$, $r = -0.271$) (Fig. 3). There was a significant association (Tab. 2) between the complete development of paranasal sinuses and nasal NO levels > 250 ppb in patients with PCD ($p < 0.001$).

No correlation was found between aplasia/hypoplasia and bronchiectasis or lung impairment.

As expected sinus inflammation was more frequently found in PCD patients. The median modified Lund – Mackay score was 9.0 (IQR: 6.5) in PCD, and only 3.5 (IQR: 7) in subjects with SCD

($p < 0.001$). However, in both groups of patients there was a significant inverse correlation between the severity and extent of local sinus inflammation and nasal NO (PCD: $p = 0.002$, $r = -0.499$; SCD: $p = 0.01$, $r = -0.365$). Moreover, in PCD patients there was a significant positive correlation between agenesis/hypoplasia of the frontal or sphenoidal sinuses and the degree of inflammation of the remaining developed sinuses ($p = 0.002$, $r = 0.486$) (on-line figure).

Finally, there was a positive correlation between sinus inflammation and the presence of bronchiectasis ($p = 0.01$, $r = 0.362$) in SCD but not PCD. There was no correlation between sinus inflammation and Bhalla score. There were significant positive correlations between Bhalla score and presence of bronchiectasis both groups (PCD: $p = 0.02$, $r = 0.363$; SCD: $p < 0.001$, $r = 0.733$ respectively).

DISCUSSION

We have demonstrated that the frontal and/or sphenoidal sinuses were either aplastic or hypoplastic in a significant proportion of patients with PCD significantly more frequently than in SCD. For ethical reasons we did not have scans on normal controls. From the literature, the frontal sinus is the last paranasal cavity to expand and aplasia is present unilaterally in 15% and bilaterally in 5% of normal adults [11], less than we observed even in subjects with SCD. Aplasia of a sphenoidal sinus is extremely rare [11]. Therefore, a lack of pneumatization of the sphenoidal sinus in patients more than 10 years old is abnormal and PCD should be excluded. We suggest that for the first time that sinus aplasia/hypoplasia is part of the clinical spectrum of PCD, although given the higher than normal prevalence in SCD, this finding cannot be considered diagnostic. From our data, the positive predictive value of low nasal NO is 75.6% for distinguishing primary from secondary ciliary dyskinesia, with a negative predictive value of 77.8%. The equivalent PPV for aplasia/hypoplasia of the frontal/sphenoidal sinuses is 63.8% and the NPV is 71.8%. Depending on the clinical context, possible nNO measurements could be used to reduce the need for sinus CT scans to diagnose sinus hypoplasia, although this would need to be confirmed on a larger series of patients; if precise anatomical information was needed, this could not be provided by nNO measurements.

Paranasal sinuses go through via two stages of development: a prenatal phase (primary pneumatization) when differential growth of the cartilaginous nasal capsule produces diverticular pouches or recesses as well as infoldings of cartilage [16], and secondary pneumatization, that extends from prenatal stages through adulthood, which creates additional air spaces in bone [16]. Secondary pneumatization occurs when a paranasal recess gains an extracapsular position through reabsorption of bone and proliferation of epithelium [16] by means of mucosally-mediated active processes [17].

The fact that only the development of those paranasal sinuses which have a post-natal growth (frontal and sphenoidal) is compromised might indicate that this effect is secondary to chronic post-natal upper airways infection and inflammation [16, 17] and hypothetically related to the premature

ossification of the cartilage surrounding the paranasal recesses [18]. in relation to osteoblastic activation [19]. The higher than normal prevalence in SCD would support this hypothesis. In animal models it has been demonstrated that air-filled spaces in the cranium are formed by invasion of nasal mucous epithelium into neighbouring nasal capsule cartilages [18] [20]. and this is likely to be inhibited by premature ossification. Furthermore, nasal ventilation as been demonstrated to be an important factor in the development of the paranasal sinuses [19 21] and thus nasal obstruction which is an early event in infants with PCD (but also seen in SCD and other conditions) [20 22] might be a further contributing factor to reduced expansion of the sinuses. These possibilities are further supported by the recent findings of aplastic or hypoplastic frontal and sphenoid sinuses in a high proportion of adult patients with cystic fibrosis a disease also characterized by chronic airway infection [12].It is possible that nasal hypoventilation and chronic infection are both required to produce sinus hypoplasia, since unilateral choanal atresia is not associated with ipsilateral sinus hypoplasia [21 23].

Whether NO is an active mediator in this process or only a passive bystander is a matter of speculation. NO regulates a number of physiologic processes such as blood flow, neurotransmission, and host defences [22 24]. During infection and inflammation NO production is increased but whether or not this is beneficial to the host is unclear and in the case of PCD the cause of low nasal NO is unknown [25]. However, genetically modified animals lacking inducible NO synthase are more vulnerable to viral and bacterial infections [23 26], thus the lower level of nasal NO usually found in PCD patients [4] could predispose to more severe upper airways' infections, and, we speculate, to a reduced development of the sinuses. The fact that in our patients sinus aplasia/hypoplasia was more severe in PCD than in SCD patients; that only those sinuses which develop postnatally were involved; and that there was no correlation between sinuses aplasia/hypoplasia and the age of the patient suggests that both exogenous causes and the genetic background contribute to pathogenesis. , often on the background of an additive genetic disease.

As previously reported we also observed a correlation between low level of nasal NO and the severity of sinusitis [3]. This may be because of a reduced resistance to infections [3], but the possibility that the infections may also cause a fall in nasal NO cannot be excluded in a cross-sectional study such as this. In a healthy volunteer the application of an NO synthase inhibitor topically in one maxillary sinus was associated with an unilateral marked decrease of NO production and with the appearance of CT proven maxillary sinusitis after 3 days [24 27]. Whether maxillary and/or ethmoidal sinusitis was a predisposing factor to aplasia/agenesis of post-natal developing sinuses is practically impossible to study in humans. However, the fact that a drop of nasal NO concentration can be secondary to absence and/or occlusion of paranasal sinuses is corroborated by a study showing that baboons, which constitutively have no paranasal sinus cavities, have very low nasal NO (\approx 1 ppb) compared to the nasal NO measured in rhesus monkeys with paranasal sinuses (\approx 100 ppb) (25).

Finally we found a correlation between the severity of sinusitis and bronchiectasis in patients with SCD. Mucociliary clearance is an essential first-line defence of both the upper and lower airways, and it is well known that ciliary function impairment is present both in PCD and SCD. Failure to recognize and treat both upper and lower airway infections may lead to the development of both chronic sinusitis as well as bronchiectasis. Chronic sinusitis and bronchiectasis are frequently associated [26 29] particularly when the two diseases share a common host defence abnormality [27 30]. The observation that in our patients with PCD there was no correlation between sinusitis and bronchiectasis is unexplained. Possibly it might be related to the fact that, sinusitis may be an earlier event than bronchiectasis and consequently antibiotic treatment might have led to improvement in sinusitis severity. Since compliance with treatment decreases with age, it is possible that later complications may be more severe, but this is speculative [28 31].

In conclusions, we suggest that the findings of aplasia/hypoplasia of the frontal and or sphenoidal sinuses may be part of the spectrum of PCD, and this finding should prompt exclusion of this

condition. However, SCD and other chronic respiratory can also cause sinus aplasia and hypoplasia, so specific testing for PCD should always be performed.

ACKNOWLEDGEMENTS

We are grateful to Unione Industriali Pisana for financial support.

TABLE 1. Definitions of radiological features

Radiological Features	Definitions
Frontal and sphenoid sinus aplasia	absence of bone pneumatization
Frontal sinus hypoplasia	oval-shaped sinus, presence of lateral margin of the sinus medially to a vertical line drawn through the medial surface of the globe, and absence of intrasinus septa
Sphenoid sinus hypoplasia	oval-shaped sinus, pneumatization limited to the presphenoid, anterior to the vertical plane of the tuberculum sellae, and absence of intrasinus sept
Maxillary sinus hypoplasia	presence of three of following four criteria: <ol style="list-style-type: none">1. oval-shaped sinus2. absence of pneumatization of the sinus below the level of the nasal floor3. presence of medial wall of the sinus laterally to a vertical line drawn tangentially to the medial orbital border4. lateral extension of the sinus medial to a vertical line drawn through the middle of the orbit at the level of the infundibulum, in the coronal plane

TABLE 2. Significant association* between the complete development of paranasal sinuses and nasal NO levels > 250 ppb in PCD patients

No. PCD patients with nasal NO	No. PCD patients (%) with score for sinuses agenesis/hypoplasia	
	<i>0</i>	≥ 1
> 250 ppb 10	7 (70)	3 (30)
< 250 ppb 31	3 (9.7)	28 (90.3)

* p<0.001

Figure Legends

Fig. 1: a. Agenesis of right frontal sinus and hypoplasia of left frontal sinus in a volumetric 3-dimensional reconstruction; b. Frontal sinuses agenesis in a volumetric 3-dimensional reconstruction; c. Coronal view demonstrating sphenoid sinuses agenesis; d. Axial image demonstrating maxillary sinus hypoplasia.

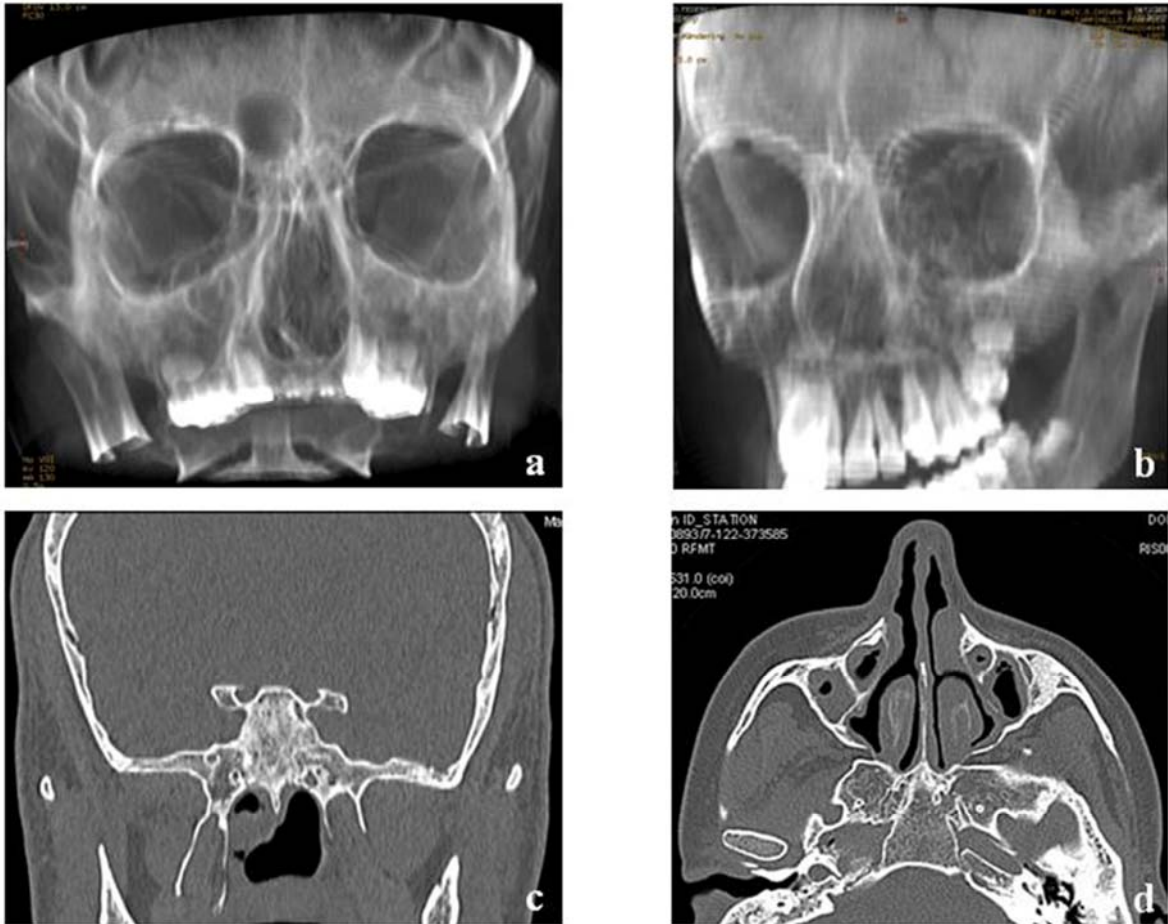


Fig. 2: Correlation between the score for aplasia/hypoplasia of paranasal sinuses and nasal NO values in patients with PCD.

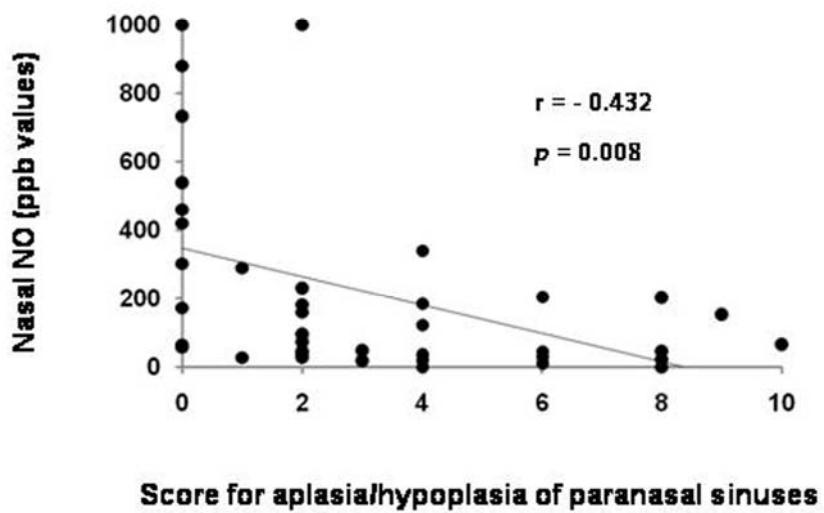
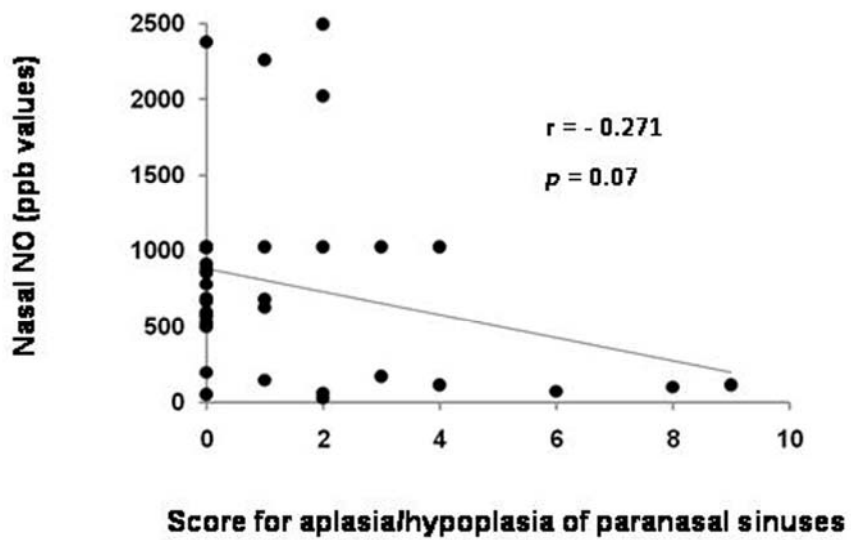


Fig. 3: Correlation between the score for aplasia/hypoplasia of paranasal sinuses and nasal NO values in subjects with SCD.



On-line figure: Correlation between sinuses agenesis/hypoplasia of the frontal or sphenoidal sinuses and the degree of inflammation of the remaining developed sinuses

REFERENCES

1. Lundberg JO. Nitric oxide and the paranasal sinuses. *Anat Rec (Hoboken)*. 2008;291:1479-1484.
2. Hood CM, Schroter RC, Doorly DJ, Blenke EJ, Tolley NS. Computational modeling of flow and gas exchange in models of the human maxillary sinus. *J Appl Physiol*. 2009;107:1195-1203.
3. Deja M, Busch T, Bachmann S, Riskowski K, Campean V, Wiedmann B, Schwabe M, Hell B, Pfeilschifter J, Falke KJ, Lewandowski K. Reduced nitric oxide in sinus epithelium of patients with radiologic maxillary sinusitis and sepsis. *Am J Respir Crit Care Med*. 2003;168:281-286.
4. Karadag B, James AJ, Gültekin E, Wilson NM, Bush A. Nasal and lower airway level of nitric oxide in children with primary ciliary dyskinesia. *Eur Respir J*. 1999;13:1402-1405.
Narang I, Ersu R, Wilson NM, Bush A. Nitric oxide in chronic airway inflammation in children: diagnostic use and pathophysiological significance. *Thorax*. 2002;57:586-589.
5. Gómez R, Pérez Trullen A, Ruiz C, Ugedo J, Suárez FJ, Ramón y Cajal S. Primary ciliary dyskinesia with frontal sinus agenesis. *Acta Otorrinolaringol Esp*. 1997;48:315-316.
6. Rutland J, Cole PJ. Non-invasive sampling of nasal cilia for measurement of beat frequency and study of ultrastructure. *Lancet*. 1980;2:564-565.
7. Pifferi M, Cangioti AM, Ragazzo V, Baldini G, Cinti S, Boner AL. Primary ciliary dyskinesia: diagnosis in children with inconclusive ultrastructural evaluation. *Pediatr Allergy Immunol*. 2001;12:274-282.
8. Carlén B, Stenram U. Ultrastructural diagnosis in the immotile cilia syndrome. *Ultrastruct Pathol*. 1987;11:653-658.
9. Pifferi M, Montemurro F, Cangioti AM, Ragazzo V, Di Cicco M, Vinci B, Vozzi G, Macchia P, Boner AL. Simplified cell culture method for the diagnosis of atypical primary ciliary dyskinesia. *Thorax*. 2009;64:1077-1081.

10. Baraldi, E, de Jongste, JC, European Respiratory Society/American Thoracic Society. Measurement of exhaled nitric oxide in children, 2001. *Eur Respir J.* 2002;20:223-237.
11. Scuderi AJ, Harnsberger HR, Boyer RS. Pneumatization of the paranasal sinuses: normal features of importance to the accurate interpretation of CT scans and MR images. *AJR Am J Roentgenol.* 1993;160:1101-1104.
12. Orlandi RR, Wiggins RH 3rd. Radiological sinonasal findings in adults with cystic fibrosis. *Am J Rhinol Allergy.* 2009;23:307-311.
13. Hopkins C, Browne JP, Slack R, Lund V, Brown P. The Lund-Mackay staging system for chronic rhinosinusitis: how is it used and what does it predict? *Otolaryngol Head Neck Surg.* 2007;137:555-561.
14. Bhalla M, Turcios N, Aponte V, Jenkins M, Leitman BS, McCauley DI, Naidich DP. Cystic fibrosis: scoring system with thin-section CT. *Radiology.* 1991;179:783-788.
15. Pifferi M, Caramella D, Bulleri A, Baldi S, Peroni D, Pietrobelli A, Boner AL. Pediatric bronchiectasis: correlation of HRCT, ventilation and perfusion scintigraphy, and pulmonary function testing. *Pediatr Pulmonol.* 2004;38:298-303.
- 16) Smith TD, Rossie JB, Cooper GM, Mooney MP, Siegel MI. Secondary pneumatization of the maxillary sinus in callitrichid primates: insights from immunohistochemistry and bone cell distribution. *Anat Rec A Discov Mol Cell Evol Biol.* 2005;285:677-689.
- 17) Wojtowicz A, Montella A, Bandiera P, Wlodarski K, Wojtowicz K, Kockanowska I, Ostrowski K. Human mucosal epithelium involvement in prenatal growth of maxillary sinuses. *Ital J Anat Embryol* 2002; 107:257–265.
16. Sato I, Sunohara M, Mikami A, Watanabe K, Sato T. Immunocytochemical study of the maxilla and maxillary sinus during human fetal development. *Okajimas Folia Anat Jpn.* 1998;75:205–216.

17. Ellington JK, Elhofy A, Bost KL, Hudson MC Involvement of mitogen-activated protein kinase pathways in *Staphylococcus aureus* invasion of normal osteoblasts. *Infect Immun.* 2001;69:5235-5242.
18. Smith TD, Rossie JB, Docherty BA, Cooper GM, Bonar CJ, Silverio AL, Burrows AM. Fate of the nasal capsular cartilages in prenatal and perinatal tamarins (*Saguinus geoffroyi*) and extent of secondary pneumatization of maxillary and frontal sinuses. *Anat Rec (Hoboken).* 2008;291:1397-1413
19. Freng A. Congenital choanal atresia. *Scand J Plast Reconstr Surg.* 1978;12:261-265.
20. Bush A, Chodhari R, Collins N, Copeland F, Hall P, Harcourt J, Hariri M, Hogg C, Lucas J, Mitchison HM, O'Callaghan C, Phillips G. Primary ciliary dyskinesia: current state of the art. *Arch Dis Child.* 2007;92:1136-1140.
21. Guimarães RE, Dos Anjos GC, Becker CG, Becker HM, Crosara PF, Galvão CP. Absence of nasal air flow and maxillary sinus development. *Braz J Otorhinolaryngol.* 2007;73:161-4.
22. Moncada S, Higgs A. The L-arginine-nitric oxide pathway. *New Engl J Med* 1993; 329:2002–2012.
25. Paraskakis E, Zihlif N, Bush A. Nitric oxide production in PCD: possible evidence for differential nitric oxide synthase function. *Pediatr Pulmonol.* 2007;42:876-880.
23. Wei XQ, Charles IG, Smith A, Ure J, Feng GJ, Huang FP, Xu D, Muller W, Moncada S, Liew FY. Altered immune responses in mice lacking inducible nitric oxide synthase. *Nature* 1995; 375:408–411.
24. Lundberg JO. Acute purulent sinusitis triggered by topical nasal nitric oxide synthase inhibition. *Am J Respir Crit Care Med* 2005; 172:512–513.
25. Lewandowski K, Busch T, Lohbrunner H, Rensing S, Keske U, Gerlach H, Falke KJ. Low nitric oxide concentrations in exhaled gas and nasal airways of mammals without paranasal sinuses. *J Appl Physiol.* 1998 ;85:405-410.

26. Shoemark A, Ozerovitch L, Wilson R. Aetiology in adult patients with bronchiectasis. *Respir Med.* 2007;101:1163–1170
27. Loebinger MR, Bilton D, Wilson R. Upper airway 2: Bronchiectasis, cystic fibrosis and sinusitis. *Thorax.* 2009;64:1096-1101.
28. Pifferi M, Bush A, Di Cicco M, Pradal U, Ragazzo V, Macchia P, Boner AL. Health-related quality of life and unmet needs in patients with primary ciliary dyskinesia. *Eur Respir J.* 2010;35:787-794.