



## Early View

### Research letter

# Personalised CFTR Pharmacotherapeutic Response Testing and Therapy of Cystic Fibrosis

Cormac McCarthy, John J. Brewington, Beth Harkness, John P. Clancy, Bruce C. Trapnell

Please cite this article as: McCarthy C, Brewington JJ, Harkness B, *et al.* Personalised CFTR Pharmacotherapeutic Response Testing and Therapy of Cystic Fibrosis. *Eur Respir J* 2018; in press (<https://doi.org/10.1183/13993003.02457-2017>).

This manuscript has recently been accepted for publication in the *European Respiratory Journal*. It is published here in its accepted form prior to copyediting and typesetting by our production team. After these production processes are complete and the authors have approved the resulting proofs, the article will move to the latest issue of the ERJ online.

Copyright ©ERS 2018

**Title:** Personalised CFTR Pharmacotherapeutic Response Testing and Therapy of Cystic Fibrosis

**Authors:** Cormac McCarthy, M.D., Ph.D., John J. Brewington, M.D., Beth Harkness, R.N., John P. Clancy, M.D., Bruce C. Trapnell, M.D.

**Institutions:** Translational Pulmonary Science Center (C.M., B.C.T.), Division of Pulmonary Biology (C.M., B.C.T.), and Division of Pulmonary Medicine (C.M., J.B., J.P.C., B.C.T.), Children's Hospital Medical Center, Cincinnati, USA.  
Children's National Medical Center, Washington D.C., USA (B.H.)  
Division of Pulmonary, Critical Care, and Sleep Medicine, University of Cincinnati College of Medicine, Cincinnati, USA (C.M., B.C.T.).

**Correspondence:** Bruce C. Trapnell, MD  
Division of Pulmonary Biology  
Cincinnati Children's Hospital Medical Center  
3333 Burnet Avenue  
Cincinnati, OH 45229-3039  
Phone: 513.636.6361  
Fax: 513.636.3723  
Email: Bruce.Trapnell@cchmc.org

**Summary Sentence:** Pharmacotherapeutic response testing identified *CFTR* Ser1159Pro as responsive to cystic fibrosis modulator therapy

## **To The Editors:**

Cystic fibrosis (CF) is a fatal, multisystem, genetic disorder caused by mutations in the cystic fibrosis transmembrane conductance regulator (CFTR), a chloride transporter critical to luminal fluid homeostasis at respiratory airway and other ductal epithelial surfaces. Therapeutic options for some CF patients were transformed by the approval of ivacaftor and lumacaftor/ivacaftor, which are indicated, respectively, for patients heterozygous for a subset of rare class III mutations [1] or homozygous for the common class II mutation Phe508del.[2] Notwithstanding, more than 40% of CF patients do not meet the CFTR mutation-specific inclusion criteria and are excluded from these therapies, and while it is impractical to conduct a clinical trial for each new pharmacotherapy-responsive CFTR mutation identified, an evolution of the drug approval process now permits drug label expansion based on *in vitro* physiological response testing. Indeed, the development of novel patient cell-based methods such as cultured intestinal organoids [3, 4] or nasal epithelial spheroids [5] permit *in vitro* testing of targeted CFTR molecular therapies. Here, we report the use of a novel preclinical test in one such patient to demonstrate patient-specific functional correction of CFTR *ex vivo* followed by initiation of therapy and functional correction *in vivo*. Further, while adverse respiratory effects have been reported with lumacaftor/ivacaftor therapy,[6] a comprehensive description of the treatment adjustment period has not been previously reported, here we provide a detailed account of this phenomenon.

## **Case**

A 38-year-old man with CF diagnosed by sweat testing, with a typical clinical course, and inconclusive CFTR genotyping became increasingly concerned about his health due to a declining lung function despite strong compliance with self-administered CF therapies. Inspired by the emergence of CFTR mutation-specific pharmacotherapy and the availability of improved

genetic testing, this extremely motivated patient sought CFTR gene sequencing analysis, which identified a rare, poorly characterised mutation Ser1159Pro (c.3475T>C)[7] and the common class II mutation Phe508del (c.1521\_1523delCTT). He conducted his own personal investigation among the CF patient community and then initiated the further consideration of evaluation and treatment options within his own care team. He underwent preclinical CFTR-therapeutic response testing [5] in which his nasal epithelial cells were isolated, cultured as spheroids and air-liquid interface (ALI) monolayers, and responses to ivacaftor and/or lumacaftor were measured.

## **Methods**

This protocol was approved by the Cincinnati Children's Hospital Medical Center Institutional Review Board. Nasal cell culture and analysis was performed as previously reported [5, 8].

Nasal epithelial cells were obtained from both inferior turbinates by curettage, pooled, dispersed with Accutase (Innovative Cell Technologies Inc.), suspended in DMEM-F12-based media containing antibiotics, rho-kinase inhibitor and seeded into dishes coated with VitroCol (Advanced BioMatrix), pre-seeded with irradiated mouse embryonic fibroblast feeder cells. Media was changed daily, antibiotics were removed after 5 days, and cultures maintained until nasal cells reached confluence. Cells were dissociated with 0.1% trypsin and then maintained as spheroid or air-liquid interface (ALI) cell monolayer cultures.

Nasal epithelial cell spheroid culture and measurement of cAMP-induced swelling: Cultured nasal cells were suspended in growth factor-reduced matrigel at 500,000 cells/mL and 100µL aliquots were seeded in 16mm four-well plates. After incubation (37°C, 5% CO<sub>2</sub>, 30 min), DMEM-F12-based media was added to each well and then changed daily during culture until the spheroids were mature (7–10 days). Nasal epithelial cell spheroid swelling was measured by time-lapse photomicroscopy in an incubated microscope chamber by capturing bright field

images before (baseline) and one hour after addition of phosphate buffered saline containing forskolin (10 $\mu$ M) and IBMX (100 $\mu$ M) to the media to increase intracellular cAMP levels. Some wells were pretreated for 48 hours with lumacaftor (3 $\mu$ M) and/or some received ivacaftor (1 $\mu$ M) at the time of stimulation. Nasal epithelial cell spheroid swelling was measured as the change in luminal area of a spheroid before and after stimulation determined from paired photomicrographs by outlining the spheroid lumen manually followed by automated measurement of the luminal area.

ALI cell monolayer culture and measurement of cAMP-induced short circuit current: Cultured nasal cells were suspended in DMEM-F12-based media and seeded onto Transwell®-Clear permeable inserts (0.4 $\mu$ m pore size) coated with type IV collagen at approximately 260,000 cells/cm<sup>2</sup>. Cells were maintained until maturity (4-6 weeks), until transepithelial resistance reached approximately 500-1000 $\mu$  $\Omega$ /cm<sup>2</sup>. Select inserts were pretreated with lumacaftor (3 $\mu$ M) for 48h prior to study. Inserts were mounted in Ussing chambers and studied in an asymmetric chloride solution to produce a basolateral-to-apical Cl<sup>-</sup> secretory gradient. Cells were treated with 100 $\mu$ M amiloride to block ENaC and sodium transport. Forskolin (10 $\mu$ M) and IBMX (100 $\mu$ M) were then added in both compartments to increase cAMP and stimulate CFTR. For select inserts, ivacaftor (1 $\mu$ M) was added to potentiate CFTR. Finally, CFTR Inhibitor-172 (10 $\mu$ M) was added to the apical compartment to block CFTR currents. Short-circuit current and resistance were measured under voltage-clamp conditions.

## Results

Pharmacotherapeutic response testing demonstrated that nasal epithelial spheroids treated with lumacaftor/ivacaftor swelled in response to cAMP-stimulation, with a mean increase in luminal area of 22.27% compared to 9.37% in untreated spheroids (p=0.002). Correction was also noted in response to ivacaftor alone (p=0.005) and a trend towards correction was noted with lumacaftor alone (p=0.065). These results indicate a pharmacological correction of

Ser1159Pro/Phe508del nasal epithelial spheroids to lumacaftor/ivacaftor *ex vivo* (Figure 1A-B), which is important before initiating expensive, lifelong therapy.

Confirmation of this pharmacological response was demonstrated by treatment of ALI monolayers with lumacaftor and ivacaftor alone or in combination. All treatment conditions resulted in an increased short-circuit current confirming the functional correction of CFTR. (Figure 1C) and the correlation between individual ALI and spheroid responses has previously been reported. [5]

Having first demonstrated pharmacodynamic correction *in vitro*, the effects of lumacaftor/Ivacaftor therapy were confirmed *in vivo* by sweat testing five weeks after initiating therapy. The patient's sweat chloride test normalised to 11mEq/L in both arms from abnormal values of 68mEq/L and 54mEq/L recorded two weeks prior to initiation of therapy. (Figure 1D)

One day after initiation of ivacaftor/lumacaftor therapy the patient noted dyspnoea at rest, slight wheezing, chest discomfort and a drop in FEV<sub>1</sub> to 50% predicted. Over the next three days he reported worsening dyspnoea, continued wheezing and chest pain, and the onset of systemic "flu-like" symptoms including malaise, generalised muscle aches, headache, lethargy and loss of appetite. There was a persistent reduction in FEV<sub>1</sub> of 49-50% predicted. After five days of therapy he noted an improvement in pulmonary and systemic symptoms despite persistent chest tightness and the onset of drenching night sweats. Following one week of treatment the patient reported resolution of systemic symptoms and continued improvement in chest tightness, dyspnoea, wheezing, but an increase in cough and sputum production (2-3 tablespoons per day). FEV<sub>1</sub> increased to values ranging between 66% and 77% predicted. During weeks three and four of therapy, the patient reported minimal dyspnoea, decreased wheeze, minimal chest tightness, and production of thin, clear to slightly yellow sputum. He resumed vigorous exercise, which resulted in transient chest tightness, significant wheezing, increased sputum production and post-exercise streaking hemoptysis, all of which resolved within hours after discontinuing exercise.

Approximately one month after starting lumacaftor/ivacaftor therapy, the patient reported “feeling that his lungs were clear”. His previous baseline spontaneous cough was absent, with cough only occurring during airway clearance therapy, productive of a tablespoon of non-viscous yellow-white sputum and incidentally the patient also noted a resolution of aquagenic wrinkling, a reported effect of ivacaftor therapy. [9] After forty-six days of therapy the FEV<sub>1</sub> had increased to 79% predicted; representing an 11% improvement upon the pre-treatment baseline of 68% predicted. (Figure 1E)

## **Conclusion**

This report identified Ser1159Pro as a CFTR allele amenable to ivacaftor therapy by use of a novel CFTR-treatment response test performed with patient-derived nasal epithelial spheroids. Results support expanding the list of CFTR mutations appropriate for CFTR-specific pharmacotherapy to include Ser1159Pro and the feasibility of the evolving approval paradigm based on *in vitro* cell-based CFTR functional testing. While both nasal and intestinal cells appear suitable for this purpose, nasal epithelial cells bear closer resemblance to lower respiratory epithelium than to intestinal epithelium; and in our experience, patients found the nasal epithelial cell approach simple and tolerable. Finally, this patient’s exceptional perseverance resulted in comprehensive description of the initial adjustment period that can occur in response to initiation of lumacaftor/ivacaftor therapy as well as the recovery and positive clinical response that follows it, which may be of use to CF patient and physician communities.

## References

1. Ramsey BW, Davies J, McElvaney NG, Tullis E, Bell SC, Dřevínek P, Griese M, McKone EF, Wainwright CE, Konstan MW, Moss R, Ratjen F, Sermet-Gaudelus I, Rowe SM, Dong Q, Rodriguez S, Yen K, Ordoñez C, Elborn JS. A CFTR Potentiator in Patients with Cystic Fibrosis and the G551D Mutation. *New England Journal of Medicine* 2011; 365(18): 1663-1672.
2. Wainwright CE, Elborn JS, Ramsey BW, Marigowda G, Huang X, Cipolli M, Colombo C, Davies JC, De Boeck K, Flume PA, Konstan MW, McColley SA, McCoy K, McKone EF, Munck A, Ratjen F, Rowe SM, Waltz D, Boyle MP. Lumacaftor–Ivacaftor in Patients with Cystic Fibrosis Homozygous for Phe508del CFTR. *New England Journal of Medicine* 2015; 373(3): 220-231.
3. Dekkers JF, Berkers G, Kruisselbrink E, Vonk A, de Jonge HR, Janssens HM, Bronsveld I, van de Graaf EA, Nieuwenhuis EE, Houwen RH, Vleggaar FP, Escher JC, de Rijke YB, Majoor CJ, Heijerman HG, de Winter-de Groot KM, Clevers H, van der Ent CK, Beekman JM. Characterizing responses to CFTR-modulating drugs using rectal organoids derived from subjects with cystic fibrosis. *Sci Transl Med* 2016; 8(344): 344ra384.
4. Dekkers JF, Gogorza Gondra RA, Kruisselbrink E, Vonk AM, Janssens HM, de Winter-de Groot KM, van der Ent CK, Beekman JM. Optimal correction of distinct CFTR folding mutants in rectal cystic fibrosis organoids. *Eur Respir J* 2016; 48(2): 451-458.
5. Brewington JJ, Filbrandt ET, LaRosa FJ, 3rd, Ostmann AJ, Strecker LM, Szczesniak RD, Clancy JP. Detection of CFTR function and modulation in primary human nasal cell spheroids. *J Cyst Fibros* 2018; 17(1): 26-33.
6. Hubert D, Chiron R, Camara B, Grenet D, Prevotat A, Bassinet L, Dominique S, Rault G, Macey J, Honore I, Kanaan R, Leroy S, Desmazes Dufeu N, Burgel PR. Real-life initiation of



lumacaftor/ivacaftor combination in adults with cystic fibrosis homozygous for the Phe508del CFTR mutation and severe lung disease. *J Cyst Fibros* 2017: 16(3): 388-391.

7. Simakova T, Kondratyeva E, Avakian L, Bragin A, Zaytseva M, Pavlov A. Identification of a novel, CF-causing compound genotype (p.S1159P and p.Y569H) using an NGS-based assay: Novel CF-causing compound p.S1159P and p.Y569H genotype. *Gene* 2016: 575(2, Part 2): 567-569.
8. Rowe SM, Pyle LC, Jurkevante A, Varga K, Collawn J, Sloane PA, Woodworth B, Mazur M, Fulton J, Fan L, Li Y, Fortenberry J, Sorscher EJ, Clancy JP. DeltaF508 CFTR processing correction and activity in polarized airway and non-airway cell monolayers. *Pulmonary pharmacology & therapeutics* 2010: 23(4): 268-278.
9. Grasemann H, Ratjen F, Solomon M. Aquagenic Wrinkling of the Palms in a Patient with Cystic Fibrosis. *New England Journal of Medicine* 2013: 369(24): 2362-2363.

### Figure 1. Preclinical Testing and Clinical Responses to CFTR-Specific Pharmacotherapy.

Nasal epithelial cells were obtained from the patient, maintained as spheroid or air-liquid interface (ALI) cell monolayer cultures, and used to measure cAMP-induced, CFTR-mediated physiological responses *ex vivo* (A-C). Oral lumacaftor/ivacaftor therapy was then initiated and treatment-related biomarker and clinical outcome responses were measured (D-E). **A.** Representative photomicrographs of nasal cell spheroids before and after addition of forskolin and IBMX to stimulate cAMP-induced activation of CFTR-dependent swelling in the absence or presence of ivacaftor plus lumacaftor treatment. White masking indicates the spheroid lumen. Scale bar: 100µM. **B.** Change in cAMP-induced spheroid luminal area determined from photomicrographs as illustrated in Panel A. Ten to eleven spheroids were evaluated for paired changes in luminal area for each condition. **C.** Change in cAMP-induced short-circuit current for ALI cell monolayers cultured with or without lumacaftor and/or ivacaftor pre-treatment as indicated. Three to four ALI cell monolayers were evaluated for each condition. **D.** Standard clinical sweat chloride test results obtained two weeks before and seven weeks after lumacaftor/ivacaftor, demonstrating treatment-related normalisation of sweat chloride in right (R) and left (L) arms. **E.** Measurement of the patient's FEV1 in the pulmonary function laboratory (open circles) or using a personal hand-held spirometer (Spiro PD 1.0, PMD healthcare, PA) (closed circles). On Day 46 of lumacaftor/ivacaftor therapy, the FEV1 was confirmed at 79 percent of the predicted value determined in the pulmonary function laboratory. T-bars indicate the standard error. Double asterisks indicate  $P < 0.01$ , a single asterisk indicates  $P < 0.05$ , and ns indicates  $P > 0.05$  for the comparison to ALI cell monolayers evaluated without lumacaftor or ivacaftor, calculated with the use of analysis of variance. The normal range of values shown in Panel B and C represent 95% confidence interval in healthy subjects as previously reported<sup>4</sup>.

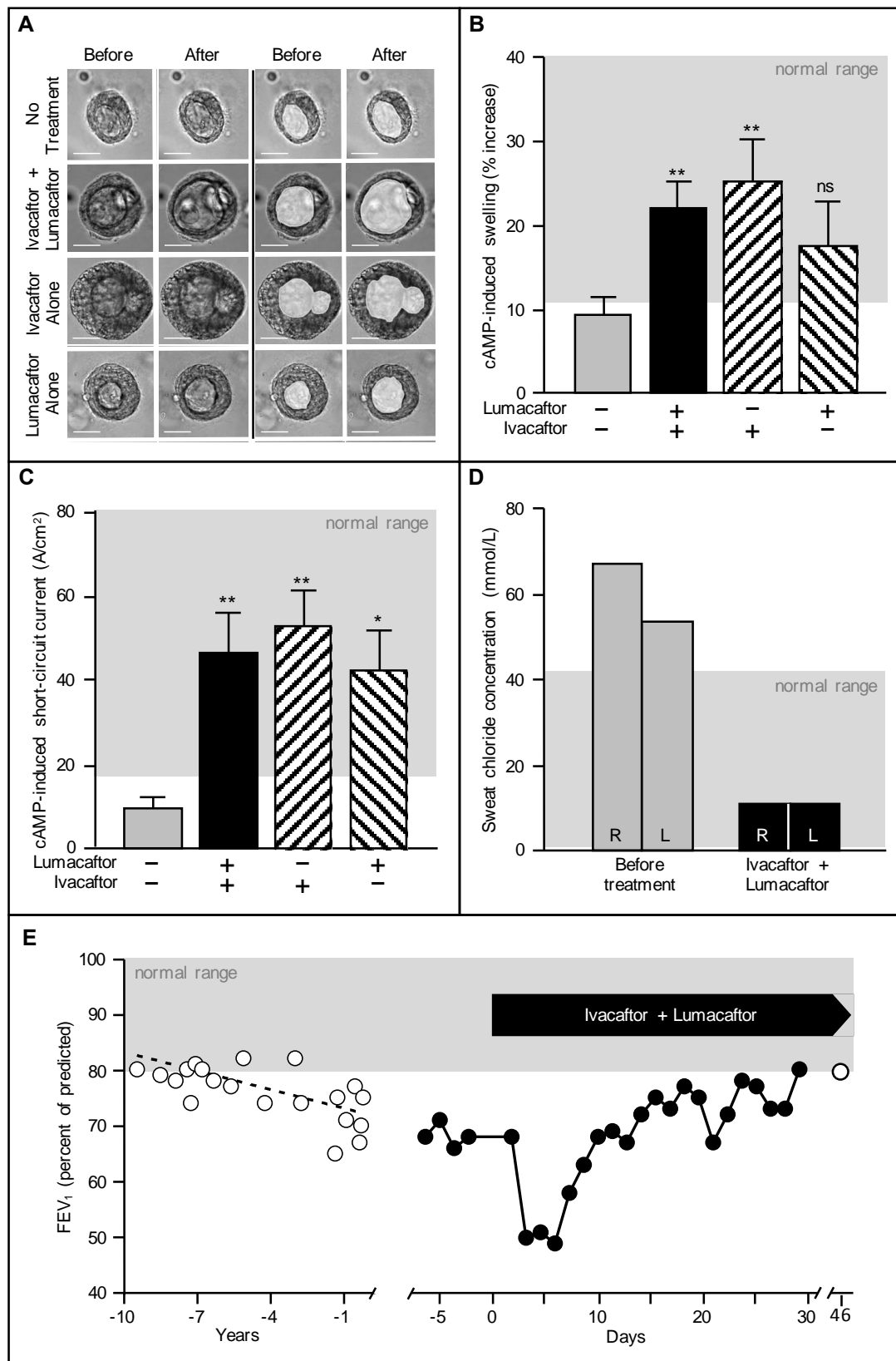


Figure 1